Leibniz Institute for Zoo and Wildlife Research
(IZW)
Berlin, Germany
&
European Association of Zoo and Wildlife Veterinarians
(EAZWV)
Liebefeld-Berne, Switzerland

# PROCEEDINGS OF THE INTERNATIONAL CONFERENCE ON DISEASES OF ZOO AND WILD ANIMALS 2013

May 8th – 11th, 2013
Vienna / Austria

Edited by Gudrun Wibbelt
Anke Schumann

ISSN 1868 - 5846

The contributions included in this volume were carefully checked and revised.
Nevertheless, authors and editors are unable to guarantee the correctness of all presented data, conclusions and advice and do not accept liability for possible printings errors.
The editors gratefully acknowledge the willingness of the following colleagues for reviewing the manuscripts submitted for this conference:

Dr. Bernardino, Lisbon, Portugal; DVM Bertelsen, Frederiksberg, Denmark; PD Dr. Borchers, Berlin, Germany; Dr. Clauss, Zürich, Switzerland; Dr. Dungl, Vienna, Austria, Prof. Dr. Eulenberger, Leipzig, Germany; Dr. Fernández-Bellon, Barcelona, Spain; Dr. Flügger, Hamburg, Germany; Dr. Frey, Berlin, Germany; Dr. Grobbel, Berlin, Germany; Prof. Dr. Gröne, Utrecht, The Netherlands; Dr. Gruber-Dujardin, Göttingen, Germany; Prof. Dr. Gumpenberger, Vienna, Austria; Dr. Höner, Berlin, Germany; Dr. IJzer, Utrecht, The Netherlands; Prof. Dr. Jewgenow, Berlin, Germany; MVDr. Jurek, Liberec, Czech Republic; Dr. J. Kaandorp, Hilvarenbeek, The Netherlands; Dr. König, Gießen, Germany; Prof. Dr. Krautwald-Junghanns, Leipzig, Germany; Dr. Kutzer, Frankfurt/Oder, Germany; Dr. Lécu, Paris, France; Dr. Lobo Fernandes, Lisbon, Portugal; Prof. Dr. Meinecke-Tillmann, Hannover, Germany; Dr. Jean Meyer, Villach, Austria; PD Dr. Moser, Jena, Germany; Dr. Kerstin Müller, Berlin, Germany; Dr. Mutschmann, Berlin, Germany; Dr. Nöckler, Berlin, Germany; Dr. Ochs, Berlin, Germany; DVM Pasmans, Merelbeke, Belgium; Dr. Rudnick, Rostock, Germany; Dr. Schmäschke, Leipzig, Germany; Prof. Dr. Schmidt, Vienna, Austria; D. Schrudde, Münster, Germany; Dr. Christoph Schulze, Frankfurt/Oder, Germany; Prof. Dr. Schwarzenberger, Vienna, Austria; Dr. Schwensow, North Terrace, Australia; DVM Sós, Budapest, Hungary; Dr. Spiezio, Bussolengo, Italy; Prof. Dr. Steinhagen, Hannover, Germany; Dr. Thaller, Vienna, Austria; Dr. Unwin, Chester, UK; Dr. Vercammen, Antwerp, Belgium; Dr. Vodička, Praha, Czech Republic; Prof. Dr. von Samson-Himmelstjerna, Berlin, Germany; Prof. Dr. Weissengruber, Vienna, Austria; Dr. Wenker, Basel, Switzerland; Dr. Wibbelt, Berlin, Germany

**This is also the continuation of the 7th "Proceedings of the Meeting of the EAZWV" (2008) and the "Erkrankungen der Zootiere – Verhandlungsbericht des 43. Internationalen Symposiums über die Erkrankungen der Zoo- und Wildtiere" (2007).**

Published by the Leibniz Institute for Zoo and Wildlife Research (IZW)
Alfred-Kowalke-Str. 17, 10315 Berlin (Friedrichsfelde)
Postfach 70 04 30, 10324 Berlin, Germany

Supported by Deutsche Forschungsgemeinschaft (DFG)
[German Research Foundation]
Kennedyallee 40, 53175 Bonn, Germany

Printed on FSC-certified paper. The paper has been harvested, processed and manufactured in a sustainable fashion. The Forest Stewardship Council (FSC) label is the gold standard in forest management and sustainable wood products.



Setting and layout: Anke Schumann, Jana Ehrhardt, Steven Seet, Berlin
Cover: Tiergarten Schönbrunn, Vienna, Austria
(Photo: Jutta Kirchner)
Printing: MAXROI Graphics GmbH, Görlitz, Germany
Order: Leibniz Institute for Zoo and Wildlife Research (IZW)
Forschungsverbund Berlin e.V.
Postfach 70 04 30, 10324 Berlin, Germany
www.izw-berlin.de

# Jointly organised by

## European Association of Zoo and Wildlife Veterinarians (EAZWV)
## &
## Leibniz Institute for Zoo and Wildlife Research (IZW)

**Scientific programme committee**
Gudrun Wibbelt, Berlin, Germany
Alex D. Greenwood, Berlin, Germany
Heribert Hofer, Berlin, Germany
Alexis Lécu, Paris, France
Christian Wenker, Basel, Switzerland
Thomas Voracek, Vienna, Austria
Hanna Vielgrader, Vienna, Austria
Anke Schumann, Berlin, Germany
Steven Seet, Berlin, Germany

***in cooperation with***

## Tiergarten Schönbrunn, Vienna

**Local organising committee**
Thomas Voracek, Vienna, Austria
Hanna Vielgrader, Vienna, Austria
Claudia Slond, Vienna, Austria
Dagmar Schratter, Vienna, Austria

## Venue
## University of Veterinary Medicine, Vienna, Austria

# TABLE OF CONTENTS

## Reptile, amphibian and fish medicine



## Imaging & Ophthalmology

## Animal welfare and training



## Free topics



## Conservation medicine & Zoonotic diseases

## Pathogens & Veterinary applications



## Asian animals: medicine, management and conservation & Primates

## Alpine wildlife & Ungulates



## Reproduction

## POSTERS

# ADVANCES IN FISH, AMPHIBIAN, AND REPTILE ANAESTHESIA, ANALGESIA, AND SURGERY

LEWBART GA

North Carolina State University, College of Veterinary Medicine, 1060 William Moore Drive, Raleigh NC 27607, USA; galewbar@ncsu.edu

## Summary

Recent years have produced many exciting and ground-breaking advances in the areas of fish, amphibian, and reptile medicine and surgery. It is well beyond the scope of these notes, or the accompanying presentation, to provide a comprehensive review of these broad topics. Consequently, I have selected several of these developments to focus on, and review in the paragraphs below, with an emphasis on analgesia, anaesthesia, and surgery. These notes and the talk are divided taxonomically beginning with fishes.

**Objectives**

- To provide interested veterinarians and other health care and husbandry providers with state-of-the science information on the anaesthesia, analgesia, and surgical techniques for captive fishes, amphibians, and reptiles.

**Key points**

- Fish anaesthesia is relatively simple to employ, inexpensive, and generally safe. There are several advances with regards to compounds used and their potential that will be shared in this talk.
- Our knowledge of analgesia and pain management in pet fish is rudimentary but expanding. This is still an important clinical topic that needs attention. The recent literature and findings will be reviewed.
- The last decade or so has produced major advances in pet fish surgery. In the past several years research has been published examining such pertinent topics as suture selection, suture pattern, post-operative care, and ethical issues. These topics will be addressed.
- Amphibian anaesthesia is relatively simple to employ, inexpensive, and generally safe. Anaesthetic monitoring can be challenging and of the three taxonomic groups may be the most problematic. There are several advances with regards to compounds used and their potential that will be shared in this talk.
- Advances in amphibian surgery and application will be shared.
- In recent years there have been major advances in reptile analgesia. A relatively large number of research papers have explored this topic. Some of these papers and their findings will be discussed.
- Reptile anaesthesia and surgical techniques have also improved. Several of the more interesting and exciting findings will be elaborated upon.

# FISHES

## Introduction

With the increasing interest in pet/ornamental fish medicine, exotic animal practitioners, zoo and aquarium veterinarians, and fisheries biologists will find it necessary to provide both anaesthesia and analgesia for their patients. While a number of compounds have been used to anaesthetise fish, the focus of this presentation will be on recent advances utilising compounds such as alfaxalone, metomidate, and propofol. Dosing and effect details will be included in this presentation. Tricaine methanesulfonate (MS-222) and eugenol (an aromatic compound found in clove oil) will be reviewed. Two recent articles provide a thorough review of anaesthesia, analgesia, and euthanasia in fishes (NEIFFER and STAMPER, 2009; SNEDDON, 2012).

Analgesia with regards to post-operative pain management in fish is a pertinent topic. A recently published book reviews the topic (BRAITHWAITE, 2010) and there is a good and comprehensive review article by WEBER (2011). Very few analgesic agents have been investigated in pet fish but there is some anecdotal and scientific evidence that butorphanol (0.4 mg/kg IM) provides some comfort to fish following abdominal surgery (HARMS et al., 2005). One can read an informative and short review by of this important topic (POSNER, 2009).

### *Anaesthetic agents*

#### MS-222

This sodium channel blocker is the only anaesthetic approved for use in fish intended for human consumption in the United States. It has a wide margin of safety in a number of species and has been the fish anaesthetic of choice at the North Carolina State University College of Veterinary Medicine (STOSKOPF, 1995; HARMS, 1998).

A neutral-buffered stock solution can be made by dissolving 1 gram of MS-222 and 1 gram of sodium bicarbonate (0.5 grams should work but 1:1 makes the math simple) in 100 millilitres (mls) of distilled water. This solution will contain 10 mg/ml of MS-222 and should be labelled appropriately. The stock solution should be protected from light and adequately labelled with the concentration, date of preparation, and name of person who mixed the solution. The stock solution should be effective for at least 30 days and in most cases longer. I am not aware of any studies that test for efficacy over time.

A recent study determined that certain analgesic/anaesthetic agents like morphine, butorphanol, and ketoprofen reduced the minimum-anaesthetic-concentration (MAC) in goldfish when used with MS-222 (WARD et al., 2012). Interestingly, higher doses of butorphanol actually increased the MAC. This study also showed that with repeated exposure (same fish) the MAC for MS-222 increased over time.

#### Eugenol

A practical alternative to MS-222 is clove oil (which may contain several eugenol isomers) that is available at many pharmacies (HIKASA et al., 1986; SOTO and BURHANUDDIN, 1995; SLADKY et al., 2001; GLADDEN et al., 2010). Concentrations of between 25 and 50 mg/L are effective in freshwater and

marine species and results are comparable to MS-222, except that recovery may be prolonged (SLADKY et al., 2001).

Eugenol is not completely soluble in water and should be diluted 1:9 in 70 - 95 % ethanol to yield a working stock solution of 100 mg/ml, since each ml of clove oil contains approximately 1 gram (1000 mg) of drug. Note, over the counter formulations may not be 100 % pure or even list the percentage of eugenol. A recent study determined that isoeugenol, an aromatic oils from the clove plant, produced safe, predictable, and dose-related anaesthesia in koi carp at concentrations of between 40 and 80 mg/L (GLADDEN et al., 2010).

*Summary of MS-222 and clove oil*

"Anaesthesia induced with tricaine methanesulfonate or eugenol contributes to hypoxemia, hypercapnia, respiratory acidosis, and hyperglycemia in red pacu (*Piaractus brachypomus*). Similar to tricaine methanesulfonate, eugenol appears to be an effective immobilisation compound, but eugenol is characterised by more rapid induction, prolonged recovery, and a narrow margin of safety. Care must be taken when using high concentrations of eugenol (over 100 mg/L) for induction, because ventilatory failure may occur rapidly. In addition, analgesic properties of eugenol are unknown." (SLADKY et al., 2001).

*Miscellaneous plant-based agents*

A number of plant chemical extracts have been used to anaesthetise fishes, and, this is an area that will likely to continue to be scientifically explored. A recent peer-reviewed paper found that extracts from the avocado pear plant leaf (*Pyrus communis*) was an effective anaesthetic for surgery of the catfish *Clarias gariepinus* (ADEBAYO et al., 2010). The authors report an effective and safe dosing range of between 130 and 190 mg/L.

*Alfaxalone*

Alfaxalone (3-alpha-hydroxyy-5-alpha-pregnane 11,20-dione) is a neuroactive steroid that has been used widely and for many years in Australia and the United Kingdom for anaesthesia of a variety of species (JONES, 2012). It is a $GABA_A$ agonist that inhibits action potential by postsynaptic hyperpolarisation. This results in decreased awareness and arousal of the patient (POSNER and BURNS, 2009; JONES, 2012).

Recent work shows that immersion alfaxalone can be a suitable anaesthetic in koi carp at a concentration of 2.5 mg/L (MINTER et al., 2013). Another study found that injectable (IM) alfaxalone is not a reliable, or even safe, anaesthetic in koi based on preliminary findings (BAILEY, 2013).

*Metomidate*

Metomidate hydrochloride has been tested in several species of fishes via bath/immersion, oral, and injectable (IV) routes (HANSEN et al., 2003; CROSBY et al., 2012). One study found that oral metomidate at a dose of 7.0 mg/kg was sufficient to immobilise halibut (*Hippoglossus hippoglossus*) and turbot (*Scophthalmus maximus*) and the authors stated this would have application in a large public aquarium setting (HANSEN et al., 2003). A more recent study looking at gouramis (*Trichogaster trichopterus*)

found immersion metomidate problematic and does not recommend its use for transport of this species without further investigation (CROSBY et al., 2012).

*Propofol*

Recent work shows that immersion propofol can be a suitable anaesthetic in koi carp at concentrations of between 2.5 mg/L and 10.0 mg/L (POSNER et al., 2013). From this unpublished work it appears that propofol at a concentration of 5.0 mg/L is adequate to induce and maintain koi carp under anaesthesia for routine diagnostic and minor surgical procedures.

***Anaesthetic delivery***

A number of fish anaesthetic "machines" have been described (LEWBART et al., 1995; LEWBART and HARMS, 1999; BRITT et al., 2002). Most are designed around the "fountain" concept where a submersible pump is used to generate constant and steady water flow. The fish is placed on a surgical platform so that a tube or tubes deliver the anaesthetic-laden water through the patient's mouth and over its gills. Anaesthetised fish can be maintained on such systems for several hours.

Several references contain detailed information on fish anaesthesia. In addition to the references mentioned previously, TREVES-BROWN (2000) and LEWBART (2013) provide helpful information.

## Surgical techniques in the fish patient

## Introduction

Ornamental fish can make excellent subjects for surgery. A large percentage of these patients are nishikigoi (*Cyprinus carpio*), which are taxonomically an ornamental carp. In the United States and in other parts of the world, nishikigoi are simply referred to as koi. Koi have been selectively bred in Asia for hundreds of years with qualities such as colour, pattern, size, and confirmation of utmost importance in terms of desirability and value. It is not uncommon for a koi owner to have thousands of Euros worth of fish in a pond, and this does not include the value of the pond and filtration equipment.

A large number of references contain details of fish surgery via case reports and review articles. Some of the more recent works examining and reviewing various surgical techniques and patient monitoring include HURTY et al. (2002), HARMS (2005), HANLEY et al. (2010), NEMATOLLAHI et al. (2010), DETERS et al. (2012) including a recently published series of articles in the *Rev. Fish Biol. Fish.* (BROWN et al., 2011; CHOMYSHYN et al., 2011; COOKE et al., 2011; HARMS and LEWBART, 2011; WAGNER et al., 2011).

Most small and exotic animal hospitals will already possess the necessary surgical instruments and other supplies necessary to perform surgery on fish. A delicate or ophthalmologic pack is helpful when working with small patients. Table 1 contains a list of pertinent materials and supplies.

The skin should be kept moist throughout the surgical. During prolonged procedures, a red rubber catheter and large syringe can be used to carefully moisten the koi patient without splashing water into the incision site. Patient monitoring can be performed with a pulse Doppler or ECG leads (one at the base of each pectoral fin and a third at the base of the anal fin).

A clear plastic avian-style drape has many advantages for fish surgery. The plastic helps retain moisture around the fish, does not allow moisture to leak through and compromise the surgical field, and provides a working surface which stray suture can contact without contamination. A rim of petroleum jelly can be used to adhere the drape to the fish if desired.

Surgical preparation should minimise disruption of the skin and mucus, as these are major barriers to infection. A simple swipe along the intended incision site with a cotton swab soaked in sterile saline, or at most dilute povidone iodine (Betadine®) or chlorhexidine solution, to reduce gross contamination suffices in place of a traditional surgical scrub. Removing scales along the incision line facilitates a smooth entry.

Retractors are a valuable tool for visualising and accessing various internal organs in the koi. Bipolar cautery works well for haemostasis during koi abdominal surgery. Needles with a cutting tip facilitate skin penetration. Simple continuous, simple interrupted and continuous Ford interlocking patterns have all been used for skin closure with satisfactory results. Single or two-layer closure can be used depending on the thickness of the body wall. A recent study examined three suture patterns in goldfish: 1) interrupted horizontal mattress; 2) simple interrupted; 3) subcuticular. Based on the inflammatory response these authors recommend the subcuticular pattern (NEMATOLLAHI et al., 2010). A study examining suture patterns in juvenile Chinook salmon (*Oncorhynchus tshawytscha*) receiving acoustic transmitters found the simple interrupted pattern superior to the horizontal mattress with regards to tissue ulceration (DETERS et al., 2012). We do not advocate use of cyanoacrylate tissue adhesive, either alone, or in combination with sutures. Studies have shown that surgical adhesives can contribute to dehiscence, delay healing, and cause local irritation (WAGNER et al., 2011; DETERS et al., 2012). Skin sutures should be removed in 10 to 14 days under most conditions.

Many suture types have been used successfully in fish. Synthetic absorbable sutures may not be readily absorbed in fish. We generally recommend using monofilament suture in the skin to decrease the risk of wicking bacteria into the wound. Other factors in suture selection are tissue reactivity and healing time. Preliminary results from a study in koi indicate that monofilament materials like nylon and polyglyconate (Maxon®) are slightly superior to braided suture (HURTY et al., 2002).

Several review articles provide thorough summaries of surgery in fish with emphasis on fish in research (HARMS, 2005; BROWN et al., 2011; HARMS and LEWBART, 2011).

*Tab. 1: Surgical supplies and equipment, medications.*

| **Surgical supplies and equipment** | **Medications** |
|---|---|
| Surgery pack (with appropriate instruments) | Antibiotics (injectable) |
| Suture absorbable and non-absorbable (monofilament) | Butorphanol (at 0.1-0.4 mg/kg IM/SQ) |
| Cotton-tipped swabs | Ketoprofen |
| Clear plastic drape | Triple antibiotic ointment |
| Sterile saline | Povidone iodine ointment |

*Continuation tab. 1*

| | |
|---|---|
| Surgery sponges (2x2 or 4x4) | Silver sulfadiazine cream |
| Scalpel blades | Sterile ophthalmic lubricant |
| Surgical gloves (selection of sizes) | Salt (1 - 3 ppt in recovery tank) for freshwater fishes |
| Masks | |
| Caps | |
| Scrub tops | |
| Head loupes | |
| Gelpi retractors | |
| +/-Doppler flow probe | |
| +/- ECG | |

## References


*ADEBAYO OT, FASAKIN EA, POPOOLA OM (2010): Use of aqueous extracts of avocado pear, Pyrus communis, leaf as anaesthetic in gonadectomy of African catfish, Clarias gariepinus. J. Appl. Aquac.* ***22****, 117 - 122.*

*BRAITHWAITE B (2010): Pain In Fish, the Evidence and Ethical Implications. Oxford University Press, Oxford UK, 256 pp.*

*BAILEY KM (2013): Personal Communication. An abstract summarizing this work has been prepared and submitted for the 2013 International Association for Aquatic Animal Medicine Conference.*

*BRITT T, WEISSE C, WEBER ES, MATZKIN Z, KLIDE A (2002): Use of pneumocystoplasty for overinflation of the swim bladder in a goldfish. J. Am. Vet. Med. Assoc.* ***221****, 690 - 3, 645.*

*BROWN RS, EPPARD MB, MURCHIE KJ, NIELSEN JL, COOKE SJ (2011): An introduction to the practical and ethical perspectives on the need to advance and standardize the intracoelomic surgical implantation of electronic tags in fish. Rev. Fish Biol. Fish.* ***21****, 1 - 9.*

*CROSBY TC, HILL JE, HARTMAN KH, YANONG RPE (2012): Effects of metomidate hydrochloride sedation on blood glucose and marketability of transported threespot gourami Trichogaster trichopterus. J. Aquat. Anim. Health* ***24****, 73 - 80.*

*CHOMYSHYN L, MCCONNACHIE SH, COOKE SJ (2011): Evaluation of water entry into the coelom and different levels of aseptic technique during surgical implantation of electronic tags in freshwater fish. Rev. Fish Biol. Fish.* ***21****, 61 - 70.*

*COOKE SJ, WAGNER GN, BROWN RS, DETERS KA (2011): Training considerations for the intracoelomic implantation of electronic tags in fish with a summary of common surgical errors. Rev. Fish Biol. Fish.* ***21****, 11 - 24.*

*DETERS KA, BROWN RS, BOYD J, EPPARD MB, SEABURG AG (2012): Optimal suturing technique and number of sutures of surgical implantation of acoustic transmitters in juvenile salmonids. Trans. Amer. Fish Soc.* ***141****, 1 - 10.*

*GLADDEN JN, BRAINARD BM, SHELTON JL, CAMUS AC, DIVERS SJ (2010): Evaluation of isoeugenol for anesthesia in koi carp (Cyprinus carpio). Am. J. Vet. Res.* ***71****, 859 - 866.*

*HANLEY CS, CLYDE VL, WALLACE RS, PAUL-MURPHY J, PATTERSON TA, KEULER NS, SLADKY KK (2010): Effects of anesthesia and surgery on serial blood gas values and lactate concentrations in yellow perch (Perca flavescens), walleye pike (Sander vitreus), and koi (Cyprinus carpio). J. Am. Vet. Med. Assoc.* ***236****, 1104 - 1108.*

*HANSEN MK, NYOMEN U, HORSBERG TE (2003): Pharmacokinetic and pharmacodynamic properties of metomidate in turbot (Scophthalmus maximus) and halibut (Hippoglossus hippoglossus). J. Vet. Pharmacol. Ther.* ***26****, 95 - 103.*

*HARMS CA (1998): Anesthesia in fish. In: Fowler ME, Miller RE (Eds.). Zoo & Wild Animal Medicine Current Therapy 4. Philadelphia: WB Saunders Company, 158 - 163.*

*HARMS CA (2005): Surgery in fish research; Common procedures and post-operative care. Lab Animal* ***34****, 28 - 34.*

*HARMS CA, KISHIMORIJ, BOYLAN S, LEWBART GA, SWANSON C (2005): Behavioral and clinical pathology changes in koi carp (Cyprinus carpio) subjected to anesthesia and surgery with and without peri-operative analgesics. Comp. Med.* ***55****, 221 - 226.*

*HARMS CA, LEWBART GA (2011): The veterinarian's role in surgical implantation of electronic tags in fish. Rev. Fish Biol. Fish.* ***21****, 25 - 33.*

*HIKASA Y, TAKASE K, OGAWAWARA T, OGASAWARA S (1986): Anesthesia and recovery with Tricaine methanesulfonate, eugenol, and thiopental sodium in the carp, Cyprinus carpio. Jpn. J. Vet. Sci.* ***48****, 341 - 351.*

*HURTY CA, BRAZIK DC, LAW JM, SAKAMATO K, LEBART GA (2002): Evaluation of the tissue reactions in the skin and body wall of koi (Cyprinus carpio) to five suture materials. Vet. Rec.* ***151****, 324 - 328.*

*JONES KL (2012): Therapeutic review: Alfaxalone. J. Exot. Pet Med.* ***21****, 347 - 353.*

*LEWBART, GA, STONE EA, LOVE NE (1995): Pneumocystectomy in a Midas cichlid. J. Am. Vet. Med. Assoc.* ***207****, 319 - 321.*

*LEWBART GA, HARMS CA (1999): Building a fish anesthesia delivery system. Exotic DVM Magazine* ***1****, 25 - 28.*

*LEWBART GA (2013): Fish. In: Carpenter J (Ed.). Exotic Animal Formulary, 4th Ed., Elsevier Publishing, 18 - 52.*

*MINTER LJ, MEDL-BAILEY K, HARMS CA, LEWBART GA, POSNER LP (2013): The efficacy of alfaxalone for immersion anesthesia in koi carp (Cyprinus carpio). Vet. Anaesth. Analg.. In Press.*

*NEIFFER D, Stamper MA (2009): Fish sedation, anesthesia, analgesia, and euthanasia: Considerations, methods, and types of drugs. ILAR J.* ***50****, 343 - 360.*

*NEMATOLLAHI A, BIGHAM AS, KARIMI I, ABBASI F (2010): Reactions of goldfish (Carrasius auratus) to three suture patterns following full thickness skin incisions. Res. Vet. Sci.* ***89****, 451 - 454.*

*POSNER LP (2009): Pain and distress in fish: A review of the evidence. ILAR J.* ***50****, 327 - 328.*

*POSNER LP, BURNS P (2009): Injectable anesthetic agents. In RIVIERE JE, PAPICH MG (Eds.) Veterinary Pharmacology and Therapeutics (ed. 9). Ames, IA, Wiley-Blackwell, 265 - 300.*

*POSNER LP (2013): Personal Communication. An abstract summarising this work has been prepared and submitted for the 2013 International Association for Aquatic Animal Medicine Conference.*

*SLADKY KK, SWANSON C, STOSKOPF MK, LOOMIS M, LEWBART GA (2001): Comparative efficacy of tricaine methanesulfonate and clove oil for use as anesthetics in red pacu (Piaractus brachypomus). Am. J. Vet. Res.* ***62****, 337 - 342.*

*SNEDDON LU (2012): Clinical anesthesia and analgesia in fish. J. Exot. Pet Med.* ***21****, 32 - 43.*
*SOTO CG, BURHANUDDIN CG (1995): Clove oil as a fish anesthetic for measuring length and weight or rabbitfish (Siganus lineatus). Aquaculture* ***136****, 149 - 152.*
*STOSKOPF MK (1995): Anesthesia of pet fishes. In: Bonagura JD, Kirk RW (Eds.). Current veterinary therapy XII, small animal practice. Philadelphia: WB Saunders Co., 1365 - 1369.*
*TREVES-BROWN KM (2000): Applied Fish Pharmacology. Kluwer Academic Publishers, Dodrecht, The Netherlands.*
*WARD JL, McCARTNEY SP, CHINNAUDARI SK, POSNER LP (2012): Development of a minimum-anesthetic-concentration depression model to study the effects of various analgesics in goldfish (Carassius auratus). J. Zoo Wildl. Med.* ***43****, 214 - 222.*
*WEBER S (2011): Fish analgesia: Pain, stress, fear aversion, or nociception. Vet. Clin. North Amer. Exot. Anim. Prac.* ***14****, 21 - 32.*
*WAGNER GN, COOKE SJ, BROWN RS, DETERS KA (2011): Surgical implantation techniques for electronic tags in fish. Rev. Fish Biol. Fish.* ***21****, 71 - 81.*

## AMPHIBIANS

### Introduction

Amphibians are a fascinating and extremely important taxonomic group of animals. They are valued as environmental sentinels, biomedical research subjects, public display animals, private pets, and even as a human food source. WRIGHT and WHITAKER (2001) provide a detailed resource on general amphibian husbandry and medicine. A recent husbandry guide produced by the Association of Zoos and Aquariums (POOLE, 2012) provides a thorough review of amphibian natural history and husbandry.

With the frequent, and increasing veterinary engagement with amphibians, it is necessary to provide both analgesia and anaesthesia for these animals, especially when surgery is involved. While a number of compounds have been used to anaesthetise amphibians, the focus of this presentation will be on recent advances utilising compounds such as benzocaine (Orajel®), eugenol, isoflurane, propofol, and sevoflurane). Dosing and effect details will be included in this presentation. Tricaine methanesulfonate (MS-222) will be reviewed.

Analgesia with regards to post-operative pain management in amphibians is a pertinent topic. The literature is well represented with studies on opioid agonists; most of these studies date to the 1980's and 1990's (PEZALLA and STEVENS, 1984; STEVENS et al., 1994; STEVENS, 1996; TERRIL-ROBB et al., 1996; NEWMAN et al., 2000) but several have been published in the last 10 years (STEVENS, 2004; MOHAN and STEVENS, 2006; KOELLER, 2009; STEVENS, 2011). A number of non-steroidal anti-inflammatory drugs (NSAID) have been investigated in amphibians including, but not limited to, flunixin megalamine, indomethacin, and ketorolac (STEVENS, 1996; TERRIL-ROBB et al., 1996). All of these agents appeared to produce analgesic effects in the species tested. Meloxicam (0.1 mg/kg IM) suppresses prostaglandin E2 (PGE2) (the most predominant prostaglandin) postinjury in American bullfrogs, *Rana catesbeiana* (MINTER et al., 2011). This indicates that administering an NSAID like meloxicam in anurans, and perhaps other amphibians, can elicit an anti-inflammatory response and possibly have an analgesic effect.

### *Anaesthetic agents*

A number of anaesthetic agents are commonly used to anaesthetise amphibians. A recent article reviews the topic (MITCHELL, 2009). Historically the most commonly employed anaesthetics have been isoflurane and MS-222. Recent studies have illuminated a number of agents including benzocaine, eugenol, propofol, and sevoflurane.

**MS-222**

This sodium channel blocker is widely used for amphibian anaesthesia and has a good margin of efficacy and safety when applied appropriately at a wide range of dosages. A neutral-buffered stock solution can be made by dissolving 1 gram of MS-222 and 1 to 2 grams of sodium bicarbonate (0.5 grams should work but 1:1 makes the math simple) in 100 millilitres (mls) of distilled water. This solution will contain 10 mg/ml of MS-222 and should be labelled appropriately. The stock solution should be protected from light and adequately labelled with the concentration, date of preparation, and name of person who mixed the solution. The stock solution should be effective for at least 30 days and in most cases longer. I am not aware of any studies that test for efficacy over time.

*Isoflurane*

This halogenated ether compound has been used to anaesthetise amphibians via immersion, inhalant, and topical routes (MITCHELL, 2009). Numerous references discuss the details of its use. Frequently it is simply used to effect as a liquid soaked into cotton balls and then placed in close proximity to the amphibian (MAJOR et al., 2011; POJMAN et al., 2011).

**Eugenol**

See the **Fish** section above for general information about eugenol. In African clawed frogs 350 mg/L was successful as an immersion anaesthetic (GUENETTE et al., 2007; GOULET et al., 2010). The latter paper determined that smaller frogs (approx. 10 grams) were anaesthetised for a shorter time than medium sized frogs (approx. 30 grams). A subsequent toxicity evaluation paper (using the aforementioned dose) found that even after a single administration eugenol immersion causes renal tubular apoptosis, and, after three successive daily dosings, hepatic necrosis can result (GOULET et al., 2011).

*Benzocaine*

Orajel® is an over-the-counter commercial preparation used for local analgesia in people; it contains 20 % benzocaine. In a recent study comparing MS-222 and Orajel® in four North American amphibian species, the authors found that 20 % benzocaine provided adequate anaesthesia for amphibians, and acted faster and for a longer period compared to MS-222 (CECALA et al., 2007). It was determined to be slightly more economical than MS-222.

*Propofol*

A study on the tiger salamander (*Ambystoma tigrinum*) comparing propofol and clove oil found that propofol was an effective general anaesthetic for a surgical plane when given at 35 mg/kg intracoelomically in 5/6 salamanders (MITCHELL et al., 2009). An earlier study, examining propofol use

in the White's tree from (*Pelodryas caerulea*) determined that a safe and effective dose in this species was 30 mg/kg intracoelomically (VON ESSE and WRIGHT, 1999). Propofol was not recommended as an immersion anaesthetic for African clawed frogs (*Xenopus laevis*) in a study by GUENETTE et al. (2008). At 88 mg/L for 15 minutes it produced only light anaesthesia and at 175 mg/L all tested frogs died. Thirty-three 115-165 gram female frogs were included in the study.

*Sevoflurane*

While there do not appear to be any in vivo studies examining sevoflurane in amphibians, one study investigated its use in vitro on bullfrog (*Rana catesbeiana*) skin and several different silastic membranes (ARDENTE et al., 2008). The authors determined that sevoflurane absorption was positively affected by pluronic/lecithin organogel (PLO).

## Surgical techniques in the amphibian patient

## Introduction

Surgery can be a productive option for amphibians when such invasive therapy is warranted. Many of the same considerations and supplies needed for fish surgery apply to the amphibians (see **Fish** section above). GENTZ (2007) reviews surgical approaches and techniques in a review article that also addresses general anatomy, physiology, and anaesthesia considerations. Since amphibians are such important and widely utilised research animals, many techniques, such as ovariectomy and application of tracking/telemetry devices, are reviewed in this article.

The animal's skin (aside from the area close to the incision) should be kept moist throughout the surgical procedure. During prolonged procedures, a red rubber catheter and large syringe can be used to carefully moisten the amphibian patient without splashing water into the incision site. Patient monitoring can be performed with a pulse Doppler.

A clear plastic avian-style drape has many advantages for amphibian surgery. The plastic helps retain moisture around the patient, does not allow moisture to leak through and compromise the surgical field, and provides a working surface which stray suture can contact without contamination. A rim of petroleum jelly can be used to adhere the drape to the amphibian if desired.

Surgical preparation should minimise disruption of the skin and mucus, as these are major barriers to infection. A simple swipe along the intended incision site with a cotton swab soaked in sterile saline can suffice. Using povidone iodine or similar compounds is discouraged since these can be toxic to amphibians.

Bipolar cautery works well for haemostasis during amphibian surgery. Needles with a cutting tip facilitate skin penetration. With regards to suture selection, TUTTLE et al. (2006) found that monofilament nylon was the most appropriate of five suture types examined in the skin of the African clawed frog. LEVESQUE et al. (2010), describes wound healing in the axolotl (*Ambystoma mexicanum*).

A variety of case reports appear in the literature regarding surgical approaches to a clinical challenge. These include removal of a mandibular melanosarcoma in an axolotl (*Ambystoma mexicanum*) utilising

a skin graft from the patient (MENGER et al., 2009), femoral fracture repair in an American bullfrog (ROYAL et al., 2007), and a laminectomy in a two-towed amphiuma (WAFFA et al., 2012).

## References


*ARDENTE AJ, BARLOW BM, BURNS P, GOLDMAN R, BAYNES RE (2008): Vehicle effects on in vitro transdermal absorption of sevoflurane in the bullfrog, Rana catesbeiana. Environ. Tox. Pharmacol.* ***25****, 373 - 379.*

*GENTZ EJ (2007): Medicine and surgery of amphibians. J. Am. Assoc. Lab Anim. Sci.* ***48****, 255 - 259.*

*GUENETTE SA, HELIE P, BEAUDRY F, VACHON P (2007): Eugenol for anesthesia of African clawed frogs (Xenopus laevis). Vet. Anesth. Analg.* ***34****, 164 - 170.*

*GUENETTE SA, BEAUDRY F, VACHON P (2008): Anesthetic properties of propofol in African clawed frogs (Xenopus laevis). J. Am. Assoc. Lab. Anim. Sci.* ***47****, 35 - 38.*

*KOELLER CA (2009): Comparison of buprenorphine and butorphanol analgesia in the eastern red-spotted newt (Notophthalmus viridescens). J. Am. Assoc. Lab. Anim. Sci.* ***48****, 171 - 175.*

*LEVESQUE M, VILLIARD E, ROY S (2010): Skin wound healing in axolotols; a scarless process. J. Exp. Zool. (Mol. Dev. Evol.)* ***314****, 684 - 697.*

*MAJOR SR, FONTENOT Jr. CL, POJMAN JA Sr., POJMAN JA Jr., MERCHANT ME (2011): Serum complement activity in the three-toed amphiuma (Amphiuma tridactylum). Comp. Microbiol. Immun. Infect. Dis.* ***34****, 115 - 121.*

*MENGER B, JAHN S, ALLMELING C, REIMERS K, MUTSCHMANN F, HACOBSEN ID, VOGT PM (2009): Therapy of a melanoscarcoma in an axolotl (Ambystoma mexicanum) by resection and skin grafting. Kleintierpraxis* ***54****, 149 - 154.*

*MINTER LJ, CLARKE EO 3rd, GJELTEMA JL, ARCHIBLAD KE, POSNER LP, LEWBART GA (2011): Effects of intramuscular meloxicam administration on prostaglandin E2 synthesis in the North American bullfrog (Rana catesbeiana). Zoo Wildl. Med.* ***42****, 680 - 685.*

*MITCHELL MA (2009): Anesthetic considerations for amphibians. J. Exot. Pet. Med.* ***18****, 40 - 49.*

*MITCHELL MA, RIGGS SM, SINGLETON CB, DIAZ-FIGUEROA O, HALE LK (2009): Evaluating the clinical and cardiopulmonary effects of clove oil and propofol in tiger salamanders (Ambystoma tigrinum). J. Exot. Pet. Med.* ***18****, 50 - 56.*

*MOHAN S, STEVENS CW (2006): Systemic and spinal administration of the mu opioid remifentanil produces antinociception in amphibians. Eur. J. Pharmacol.* ***534****, 89 - 94.*

*NEWMAN LC, WALLACE DR, STEVENS CW (2000): Selective opioid agonist and antagonist competition for [3H]-naloxone binding in amphibian spinal cord. Brain. Res.* ***884****, 184 - 191.*

*PEZALLA PD, STEVENS CW (1984): Behavioral effects of morphine, levorphanol, dextrorphan and naloxone in the frog Rana pipiens. Pharmacol. Biochem. Behav.* ***21****, 213 - 217.*

*POJMAN JA Sr., POJMAN JA Jr., FONTENOT CL JR. (2011): Comparison of immobilization methods for PIT tagging three-toed amphiuma (Amphiuma tridactylum). Herpetological Review* ***42****, 362 - 363.*

*POOLE V (Ed.) (2012): Amphibian Husbandry Resource Guide. Association of Zoos & Aquariums (AZA), 238 pp.*

*ROYAL LW, GRAFINGER MS, LASCELLES BDX, LEWBART GA, CHRISTIAN LS (2007): Internal fixation of a femur fracture in an American bullfrog. J. Am. Vet. Med. Assoc.* ***230****, 1201 - 1204.*

*STEVENS CW, KLOPP AJ, FACELLO JA (1994): Analgesic potency of mu and kappa opioids after systemic administration in amphibians. J. Pharmacol. Exp. Ther.* ***269****, 1086 - 1093.*

*STEVENS CW (1996): Relative analgesic potency of mu, delta and kappa opioids after spinal administration in amphibians. J. Pharmacol. Exp. Ther.* ***276****, 440 - 448.*

*STEVENS CW (2004): Opioid research in amphibians: An alternative pain model yielding insights on the evolution of opioid receptors. Brain. Res. Rev.* ***46****, 204 - 215.*

*STEVENS CW (2011): Analgesia in amphibians: Clinical and preclinical applications. Vet. Clin. North Am. Exot. Anim. Pract.* ***14****, 33 - 44.*

*TERRIL-ROBB LA, SUCKOW MA, GRIGDESBY CF (1996): Evaluation of the analgesic effects of butorphanol tartrate, xylazine hydrochloride and flunixin meglumine in leopard frogs (Rana pipiens). Contemp. Top. Lab. Anim. Sci.* ***35****, 54 - 56.*

*TUTTLE AD, LAW JM, HARMS CA, LEWBART GA, HARVEY SB (2006): Evaluation of the gross and histologic reactions to five commonly used suture materials in the skin of the African clawed frog (Xenopus laevis). J. Am. Assoc. Lab. Anim. Sci.* ***45****, 31 - 35.*

*VON ESSE FW, WRIGHT KM (1999): Effect of intracoelomic propofol in White's tree frogs, Pelodryas caerulea. Bull. Assoc. Reptil. Amphib. Vet.* ***9****, 7 - 8.*

*WAFFA BJ, MONTGERARD AC, GRAFINGER MS, CHRISTIAN LS, DOMBROWSKI DS, LEWBART GA (2012): Dorsal laminectomy in a two-towed amphiuma (Amphiuma means). J. Zoo Wildl. Med.* ***43****, 927 - 930.*

*WRIGHT KM, WHITAKER BR (2001): Amphibian Medicine and Captive Husbandry. Krieger Publishing, Malabar, FL.*

## REPTILES

### Taxonomic Summary

The class Reptilia is broken into four orders, 48 families, over 9700 species. Taxonomy and nomenclature are dynamic disciplines so these numbers change frequently and may not be universally accepted by herpetologists. The snakes and the lizards belong in the same order (Squamata) and the turtles, crocodilians and the single species of Tuatara each have their own order. The veterinary practitioner is likely to encounter certain species of snakes, turtles and lizards in a practice, laboratory, or captive/wild zoological setting. The following represents the taxonomic break down of the world's extant reptiles as of 1 February 2013 (http://www.reptile-database.org/db-info/SpeciesStat.html; accessed 19 February, 2013):

Class: Reptilia
- Order: Testudines or Chelonia (Turtles and Tortoises)
  - 13 Families
    - 328 species

- Order: Squamata (Snakes and Lizards)
  - Suborder: Sauria (Lizards)
    - 26 Families
      - 5796 Species

  - Suborder: Serpentes (Snakes)
    - 18 Families
      - 3432 Species
  - Suborder: Amphisbaenia (Worm Lizards)
    - 4 Families
      - 181 Species

Order: Crocodylia (Crocodiles and Alligators)
3 Families
25 Species

Order: Rhynchocephalia (The Tuatara)
1 Family
1 Species

While simply memorising lists of taxonomic names and categories is not the best use of your time, it is important to understand the basic relationships between taxonomic groups (e.g. snakes and lizards are more closely related to each other than snakes and turtles).

## Snakes

## Introduction

There are over 3400 species of snakes throughout the world. Only the Arctic regions, Antarctica, Iceland and Ireland, along with a few other very small oceanic islands lack the presence of snakes. The suborder Serpentes belongs in the order Squamata that contains both the lizards and snakes. There are about 18 recognised families of snakes containing over 400 genera (http://www.reptile-database.org/db-info/SpeciesStat.html; accessed February, 2013). Snakes come in a variety of shapes and sizes but all have scales, are cylindrical in shape and lack legs and external ear openings. They range in size from about 10 cm to over 10 meters.

*Anaesthesia/analgesia/restraint*

Simple diagnostics like blood sampling, radiography and physical examination do not require anaesthesia. Larger snakes may require an extra handler or two for proper restraint.

The use of injectable barbiturates should be discouraged since there are several reports of anaesthetic death. Snakes may be masked down with 3 - 5 % isoflurane or placed into an induction chamber (an aquarium works well) that contains isoflurane. Snakes are easy to intubate due to the prominent glottis that opens into the trachea. At the NCSU-CVM we frequently intubate snakes with manual restraint. Depth of anaesthesia can be monitored by heart rate (the heart is located about one quarter of the length of the snake from the head and can be observed beating on the snake's ventral surface) and respiratory rate. A portable Doppler® apparatus works well for heart monitoring. Special care should be taken to observe respiration since all of a snake's breathing is facilitated by the abdominal muscles (they lack a diaphragm). Snakes that are not breathing may be "bagged" and care should be taken to avoid a large dead space (their lung - and they only have one that is functional - is much smaller than those of dogs and cats). Ketamine has been used as an anaesthetic agent for snakes at approximately 30 to 75 mg/kg but recovery times may be prolonged (hours to days). Propofol is preferable if venous access can be obtained. Anaesthetised snakes should be kept between 70 and 85 degrees Fahrenheit (°F) and recovered at the same temperature. The highly lipid soluble isoflurane may cause a problem if a reptile is warmed up after anaesthesia since the animal could fall back into an anaesthetic state. A number of agents have been used for analgesia in snakes. A recent study (SLADKY et al., 2008) found that butorphanol may be superior to morphine in snakes. A study (OLESEN et al., 2008) involving ball

pythons (*Python regius*) determined that neither butorphanol (5.0 mg/kg) nor meloxicam (0.3 mg/kg) were likely effective analgesics.

Hydration is an important consideration when dealing with surgery and anaesthesia. Lactated ringers and physiological saline solutions work well on snakes, as a 1:2 dilution of the two respectively (sometimes called “reptile ringers”). Some clinicians feel that LRS alone is sufficient for fluid therapy in reptiles. Guideline maintenance values are 15 to 25 ml/kg/day. A subcutaneous route is the easiest way to administer parenteral fluids in snakes although oral and intracoelomic routes can be advantageous.

## Lizards

## Introduction

There are over 5700 species of lizards worldwide. The suborder Sauria belongs in the order Squamata that contains both the snakes and the lizards. There are 26 recognised families of lizards containing approx. 400 different genera (http://www.reptile-database.org/db-info/SpeciesStat.html; accessed February, 2013). Lizards occur on every continent except Antarctica (surprise) and occupy both island and mainland habitats. The majority of species are centred in the tropical and sub-tropical regions of the world. Lizards may be as small as 1.5 cm in length or as long as 3 metres. Most are in the 20 to 30 cm range.

*Anaesthesia/analgesia/restraint*

Simple procedures such as blood sampling, radiography and general physical examination can be performed without anaesthesia in most lizards. A pair of thick gloves may help protect the handler from superficial bites and scratches.

Invasive procedures like abdominal surgery, orthopaedic surgery and surgical biopsy will require general anaesthesia. A number of anaesthetics are reported in the literature for use in lizards. Both injectable and inhalant anaesthetic agents have been used. Intravenous propofol works well for fast induction and recovery. Another and “older” approach is to induce lizards (specifically iguanas) with 15 mg/kg IM ketamine (given in a front limb) and then place them on inhalant isoflurane. If the lizard is not too fractious it may simply be masked down with isoflurane and then intubated without the use of ketamine. Small lizards can be placed in a plastic bag containing isoflurane and oxygen from the anaesthesia machine. Dexmedetomidine in combination with a lower ketamine dose and then reversal with atipamezole shows some promise, although medetomidine alone appears ineffective in iguanas. Lizards are easy to intubate since the highly visible glottis is located at the base of the tongue. Most lizards will be too small for standard mammalian endotracheal tubes so the clinician will have to improvise with a red rubber catheter or tomcat catheter. The tube can be tied in with gauze. Detecting a pulse during anaesthesia can be difficult. The heart is located far cranially and can be auscultated almost directly between the base of the forelimbs. During surgery, when the animal is in dorsal recumbency, the pulse can be monitored quite effectively with a contact Doppler® device. A well-placed oesophageal stethoscope can also detect the cardiac pulse. A number of agents have been used for analgesia in lizards. SLADKY et al. (2008) found morphine superior to butorphanol in bearded dragons (*Pogona vitticeps*).

## Turtles

## Introduction

Turtles are found throughout the world on all continents and in all oceans except Antarctica. There are over 325 species of turtles (far fewer than snakes or lizards) that belong to about 90 genera in 13 families (http://www.reptile-database.org/db-info/SpeciesStat.html; accessed February, 2013). Turtles appeared in the fossil record over 200 million years ago and were on earth long before mammals and other forms of present day reptiles. They occur in terrestrial, freshwater aquatic, semiaquatic, and marine environments. They range in size from 11 cm to 185 cm and one species can weigh close to a ton, making it (the leatherback sea turtle) the world's largest turtle and one of the largest living reptiles!

*Anaesthesia/analgesia/restraint*

Simple procedures like radiography and blood sampling usually do not require sedation. Most turtles will remain still for the time it takes to produce a radiograph.

Invasive surgical procedures will require anaesthesia and analgesia. Many textbooks and review articles adequately summarise the literature (e.g., McArthur et al., 2004; Mader, 2006; Jacobson, 2007; Mitchell and Tully, 2008; Sladky and Mans, 2012; Gibbons et al., 2013). A number of agents are used in turtles including injectable and inhalant compounds. We have had favorable results with many chelonian species using 3 to 10 mg/kg propofol IV for induction or relatively quick procedures like fish hook removal. Ketamine hydrochloride at a dose of 5 to 10 mg/kg combined with medetomidine or dexmedetomidine at 50 mcg/kg IM or IV works very well. A study on mature female nesting leatherback sea turtles (*Dermochelys coriacea*) by Harms et al. (2007) found the medetomine/ketamine combination with atipamezole reversal satisfactory for field anaesthesia. This regimen may also be used in order to sedate a turtle for intubation and placement on inhalant isoflurane or sevoflurane. Telazol® is used by some clinicians to anaesthetise chelonians. Barbiturates should be avoided if possible because of deleterious effects. Butorphanol, ketoprofen, buprenorphine, morphine, and other agents have been used for analgesia in chelonians. A study (Sladky et al., 2007) found that morphine may be superior to butorphanol in turtles. Buprenorphine can also be used and has been studied in red-eared sliders (*Trachemys scripta*) by Kummrow et al. (2008). Details on some of these compounds and references are given below.

## Selected analgesia/anaesthesia agents in reptiles

While there is some overlap between the information in this section and the previous paragraphs, here we examine some analgesic/anaesthetic drugs individually as they are applied to various reptile taxa. A recent publication (Mosley, 2011) summarises the state-of-the science with regards to pain and nociception in reptiles; this 16-page review article contains over 80 references.

*Alfaxalone*

Please refer to the **Fish** section above for general information about alfaxalone and its mode of action. While widely used and available in the UK and Australia, it is not sold in the United States. It is legal to import a 30-day supply for in-clinic (no distribution) use in the US (Lennox, 2011). For most reptiles an IM dose of between 5.0 and 25.0 mg/kg is satisfactory for anaesthetic induction; lower doses (2.0-5.0 mg/kg) can be used for IV administration (Lennox, 2011). Turtles generally require higher end dosages

and can be given alfaxalone intracoelomically (LENNOX, 2011). BERTELSEN and SAURER (2011) investigated 10, 20, and 30 mg/kg IM dosages in the green iguana. They concluded that, respectively, the lower dose was adequate for sedation (phlebotomy), the mid-range dose worked for tracheal intubation, and the latter dose for short (up to 40 minutes) surgical procedures. The reader is encouraged to consult a current formulary for more information (GIBBONS et al., 2013).

*Buprenorphine*

KUMMROW et al. (2008) determined that buprenorphine, a primary µ-receptor agonist, is safe for red-eared sliders (*Trachemys scripta elegans*), and produces acceptable/target blood levels, when administered in the forelimbs at a dose of 0.05 mg/kg subcutaneously. Interestingly, when the same dose and route was given in the hind limbs, the plasma levels were much lower, likely due to first-pass hepatic clearance (although a secondary rise in levels was detected, probably from enterohepatic recirculating).

*Butorphanol*

OLESEN et al. (2008) determined that butorphanol was not an effective analgesic agent in the ball python (*Python regius*). SLADKY et al. (2008) determined that a high dose (20 mg/kg IM) of butorphanol provided analgesia for corn snakes (*Elaphe guttata*) but not for bearded dragons (*Pogona vitticeps*). SLADKY et al. (2007) found butorphanol to be unacceptable as an analgesic agent in red-eared slider turtles.

*Meloxicam*

OLESEN et al. (2008) found that meloxicam was not an effective analgesic agent in the ball python (*Python regius*). DIVERS et al. (2010) performed a pharmacokinetics study of meloxicam in the green iguana and concluded that a dose of 0.2 mg/kg PO or IV appears safe and yields plasma concentrations consistent with an anti-inflammatory effect in some mammals. They do not recommend higher doses due to potential toxicity, although no histopathological changes were observed on a limited number of iguanas that received multiple daily doses of between 1.0 and 5.0 mg/kg. A clinical trial investigating carprofen (2.0 mg/kg IM) and meloxicam (p.2 mg/kg IM) along with a saline control found no evidence of significant toxicity based on gross observation and blood work parameters. A recently published study (ROYAL et al., 2012) found that eastern box turtles (*Terrapene carolina carolina*) possess both COX-1 and COX-2 proteins are expressed in this species and are upregulated with inflammation. This indicates that NSAID's that block both COX-1 and COX-2 (e.g. ketoprofen) might be superior to COX-2 specific drugs like meloxicam.

*Morphine*

SLADKY et al. (2008) determined that high doses (10 - 20 mg/kg IM) of morphine provided analgesia for bearded dragons (*Pogona vitticeps*) but not for corn snakes (*Elaphe guttata*). SLADKY et al. (2007) found morphine to be acceptable as an antinociceptive agent in red-eared slider turtles (*Trachemys scripta*) at a dose of 1.5 mg/kg SC.

*Propofol*

Propofol is a widely used and popular intravenous anaesthetic for reptiles. Dosing details abound and can be viewed in various texts and formularies. A recent study examined its used via the supra-vertebral sinus in red-eared slider turtles (ZIOLO and BERTELSEN, 2009). These authors concluded that 10 to 20 mg/kg IV provided safe and adequate sedation for endotracheal intubation. It should be noted there is evidence that needle placement in the subcarapacial sinus can have deleterious effects in several species of turtles if the spinal cord or epidural space is compromised (INNIS et al., 2010). The problems frequently, but are not limited to, limb and tail paresis.

*Tramadol*

Tramadol is a non-controlled drug with μ-opioid activity in mammals that was recently studied in the red-eared slider turtle (BAKER et al., 2011). The authors found that PO doses of 5.0 and 10.0 mg/kg provided thermal-insult analgesia and may be superior to morphine as it does not have the same respiratory depression effect. For a review of tramadol use in reptiles and other exotic animals see SOUZA and COX (2011).

## Surgical techniques in the reptile patient

## Introduction

Surgery is a productive option for reptiles when such invasive therapy is warranted. Some of the same considerations and supplies needed for fish and amphibian surgery apply to the amphibians (see **Fish** and **Amphibian** sections above). Of course the more terrestrial/air breathing nature of reptiles negates some of the concerns and applications of fishes and amphibian surgery. Numerous texts, several of which are listed in the reference section below, address this topic in great detail for all of the major reptilian groups. It is beyond the scope of these notes to thoroughly address or include the vast number of references on this broad topic. However, a few recently published reviews, which are very helpful in targeting specific aspects of the literature, are included below.

A laboratory animal journal publication (ALWORTH et al., 2011) reviews surgery in reptiles utilised in research. The authors provide, in great detail, surgical approaches and techniques for dozens of procedures. The article is richly illustrated in colour and contains over 100 peer-reviewed references. A review article by DIVERS (2010) describes techniques and applications for endoscopic diagnostics and endosurgery in snakes, lizards, and turtles. RAFTERY (2011) has published a well-illustrated review focused on orthopaedic surgery and some underlying medical conditions of reptiles.

A 2011 study (MCFADDEN et al.) examined eight types of sutures and cyanoacrylate tissue adhesive (CTA) in 30 hatchling ball pythons where 1-cm skin incisions were evaluated. The authors found that all sutures produced a significant inflammatory response and that none of the sutures were absorbed at the 90-day conclusion of the study. They determined that CTA is adequate and appropriate to close small lacerations or incisions in the skin of this species.

## References


*ALWORTH LC, HERNANDEZ SM, DIVERS SJ (2011): Laboratory reptile surgery: Principles and techniques. J. Am. Assoc. Lab. Anim. Sci.* ***50****, 11 - 26.*

*BAKER BB, SLADKY KK, JOHNSON SM (2011): Evaluation of the analgesic effects of oral and subcutaneous tramadol administration in red-eared slider turtles. J. Am. Vet. Med. Assoc.* ***238****, 220 - 227.*

*BERTELSEN MF, SAURER CD (2011): Alfaxalone anesthesia in the green iguana (Iguana iguana). Vet. Anesth. Analg.* ***28****, 461 - 466.*

*DIVERS SJ, PAPICH M, McBRIDE M, STEDMAN NL, PERPINAN D, KOCH TF, HERNANDEZ SM, BARRON GH, PETHEL M, BUDSBERG SC (2010): Pharmacokinetics of meloxicam following intravenous and oral administration in green iguanas (Iguana iguana). Am. J. Vet. Res.* ***71****, 1277 - 1283.*

*DIVERS SJ (2010): Reptile diagnostic endoscopy and endosurgery. Vet. Clin. NA Exot. Anim. Pract.* ***13****, 217 - 242.*

*GIBBONS PM, KLAPHAKE E, CARPENTER JW (2013): Reptiles. In: Carpenter J, Marion C (Eds.). Exotic Animal Formulary, Fourth Edition, Elsevier Saunders, St. Louis, MO, 84 - 170.*

*HARMS CA, ECKERT SA, KUBIS SA, CAMPBELL M, LEVENSON DH, CROGNALE MA (2007): Field anaesthesia of leatherback sea turtles (Dermochelys coriacea). Vet. Rec.* ***161****, 15 - 21.*

*INNIS C, DeVOE R, MYLNICZENKO N, YOUNG D, GARNER M (2010): A call for additional study of the safety of subcarapacial venipuncture in chelonians. Proc. ARAV., 8 - 10.*

*JACOBSON ER (2007): Infectious Diseases and Pathology of Reptiles. CRC Press, Boca Raton, FL. 716 pp.*

*KUMMROW MS, TSENG F, HESSE L, COURT M (2008): Pharmacokinetics of buprenorphine after single-dose subcutaneous administration in red-eared sliders (Trachemys scripta elegans). J. Zoo Wildl. Med.,* ***39****, 590 - 595.*

*LENNOX AM (2011): Use of alfaxalone (Alfaxan) in reptiles. Proc. North Am. Vet. Conf., 1643 - 1644.*

*MADER DR (2006): Reptile Medicine and Surgery, Second Edition. Elsevier/Saunders Co., Phila, 1262 pp.*

*McARTHUR S, MEYER J, WILKINSON R (2004): Medicine and Surgery of Tortoises and Turtles. Blackwell Publishing, 600 pp.*

*McFADDEN MS, BENNETT A, KINSEL MJ, MITCHELL MA (2011): Evaluation of the histologic reactions to commonly used suture materials in the skin and musculature of ball pythons (Python regius). Am. J. Vet. Res.* ***72****, 1397 - 1406.*

*MITCHELL MA, TULLY TN (2008): Manual of Exotic Pet Practice. Elsevier (Saunders) Publishing, 560 pp.*

*MOSLEY C (2011): Pain and nociception in reptiles. Vet. Clin. Exot, Anim.* ***14****, 45 - 60.*

*OLESEN MG, BERTELSEN MF, PERRY SF, WANG T (2008): Effects of preoperative administration of butorphanol or meloxicam on physiologic responses to surgery in ball pythons. J. Am. Vet. Med. Assoc.,* ***233****, 1883 - 1888.*

*RAFTERY A (2011): Reptile orthopedic medicine and surgery. J. Exotic. Pet Med.* ***20****, 107 - 116.*

*ROYAL LW, LASCELLES BDX, LEWBART GA, CORREA MT, JONES SL (2012): Evaluation of cyclooxygenase protein expression in traumatized versus normal tissues from eastern box turtles (Terrapene carolina carolina). J. Zoo Wildl. Med.* ***43****, 289 - 295.*

*SLADKY KK, MILETIC V, PAUL-MURPHY J, KINNEY ME, DALLWIG RK, JOHNSON SM (2007): Analgesic efficacy and respiratory effects of butorphanol and morphine in turtles. J. Am. Vet. Med. Assoc.* ***230****, 1356 - 1362.*

*SLADKY KK, KINNEY ME, JOHNSON SM (2008): Analgesic efficacy of butorphanol and morphine in bearded dragons and corn snakes. J. Am. Vet. Med. Assoc.* ***233****, 267 - 273.*

*SLADKY KK, MANS C (2012): Clinical analgesia in reptiles. J. Exot. Pet Med.* ***21****, 158 - 167.*

*SOUZA MJ, COX SK (2011): Tramadol use in zoologic medicine. Vet. Clin. Exot. Anim.* ***14****, 117 - 130.*

*ZIOLO MS, BERTELSEN MF (2009): Effects of propofol administered via the supravertebral sinus in red-eared sliders. J. Am. Vet. Med. Assoc.* ***234****, 390 - 393.*

# KOI HERPESVIRUS-3 (KHV) DISEASE: SEARCHING FOR MOLECULAR BASED CONTROL METHODS

GOTESMAN M, SOLIMAN H, KATTLUN J, EL-MATBOULI M

University of Veterinary Medicine, Clinical Division of Fish Medicine, Veterinärplatz 1, 1210 Vienna, AUSTRIA; michael.gotesman@vetmeduni.ac.at

Koi Herpesvirus (KHV) Disease is a notifiable disease with high mortality rates (80 - 100 %) affecting both the common and koi carp *Cyprinus carpio L*. Initial reports of the disease surfaced 15 years ago from Germany, USA, and Israel. Since, the virus has been studied extensively in terms of detection and pathology. There are a number of KHV enzyme-linked immunosorbent assay (ELISA) detection methods that rely on protein binding based on antibody affinity in conjunction to PCR-based detection methods. A membrane protein, termed ORF81, was shown by immunohistological assays to localise in the cytoplasmic regions of cells. The localisation included regions of the endoplasmic reticulum or Golgi apparatus which indicates a role for ORF81 in protein synthesis, possibly in the maturation of the viral envelope. A recent report demonstrated that several endogenous fish defense proteins are down-regulated during KHV infection. However, relatively few studies have been made in understanding host-viral interactions mechanistically. This study used monoclonal antibodies against ORF81 linked to NHS-activated spin-columns to purify KHV proteins and KHV associated host proteins from tissue samples originating from either infected or uninfected fish. The antibody-based purified samples were next analysed by either Polyacrylamide gel electrophoresis (PAGE) and subsequent electrospray ionisation coupled to mass spectrometry (ESI-MS) or ESI-MS analysis directly after purification. Five KHV proteins and 11 host defense proteins were identified in the samples originating from infected and an additional two host defense proteins were identified from tissue samples originating in uninfected fish. Novel control methods can be established for KHV based on the proteins identified in this study.

# MEDICAL CARE OF AN ELASMOBRANCH COLLECTION

OESTERWIND M[1,2], BLANC V[3], CORTINOVIS L[1,4], GARCÍA HARTMANN M[1]

[1]Marineland Antibes, 306 Avenue Mozart, 06600 Antibes, FRANCE; melanie_oesterwind@gmx.net; crc@marineland.fr
[2]University of Veterinary Medicine Hannover, Bünteweg 2, 30559 Hannover, GERMANY
[3]Laboratory Centre Hospitalier d'Antibes Juan les Pins, 107 avenue de Nice, 06606 Antibes, FRANCE
[4]University of Bologna, Dept. Veterinary Medical Sciences, Viale Vespucci 2, Cesenatico, ITALY

Sharks, skates and rays are held in aquaria all over the world, but their medical care poses many challenges. Difficult animal access, the animals' instincts to hide symptoms, and the lack of established reference values in the literature all cause problems to the clinician. A large number of elasmobranchs is held in several natural sea water tanks at Marineland Antibes, and various animals from five different species (*Carcharhinus plumbeus*, *Carcharhinus melanopterus*, *Ginglymostoma cirratum*, *Triakis semifasciata*, *Taeniura lymma*) were presented to the veterinary team as patients during a three year period between 2009 and 2012. Diagnostic methods utilised included clinical evaluation, CT, X-ray, ultrasound, blood sampling, bacteriology, mycology, virology, and pathology. Result interpretation was challenging due to the lack of references and of specialised laboratories, so for *C. plumbeus* the establishment of normal reference values for blood, and an image catalogue were started. These were useful for the interpretation of results in several cases. Two juvenile *C. plumbeus* from the same litter presented a progressively upward bent head, while their litter mates remained normal under the same conditions. Diagnostics as well as several treatments were conducted in order to find and eliminate the cause of this pathology. Several possible causes could be excluded that way, but a definite diagnosis has not been possible to date. Another *C. plumbeus* suffered from cloacal prolapses two times, which could be placed back manually. Blood takes from this animal revealed a range of altered parameters at the time of the prolapse, which returned to levels within the normal range a few days after treatment. Other elasmobranch patients suffered from wounds, bacterial infection, dystocia, heart disease and shock. Close collaboration between laboratories and the park, and the creation of elasmobranch-specific standard laboratory protocols proved essential for obtaining meaningful results. The creation of such references as blood normal values and a picture catalogue would be desirable for the other elasmobranch species as well.

# HYDROCOELOM AND LYMPHOEDEMA IN DENDROBATID FROGS AT NATIONAL AQUARIUM, BALTIMORE: 2003 – 2011

CLANCY MM[1, 2], CLAYTON LA[2], HADFIELD CA[2]

[1]Wildlife Conservation Society, Clinical Dept., Zoological Health Program, 2300 Southern Blvd., Bronx, New York 10460, USA; mclancy@wcs.org
[2]National Aquarium, Dept. of Animal Health, 501 E Pratt St., Baltimore, Maryland 21202, USA

Hydrocoelom and lymphoedema in amphibians are common, yet reports in the literature are scarce (PESSIER, 2009; VANNEVEL, 2006; WRIGHT, 2001). Complete review of all cases in the family Dendrobatidae from January 1, 2003 to June 1, 2011 identified annual prevalence, cumulative incidence, associated signs, diagnostic findings, therapeutics, outcomes, and aetiologies. Prevalence from 2005 to 2011 was 3.19 % ($n$ = 89). Hydrocoelom, coelomic distention with fluid, and lymphoedema, fluid accumulation in the lymph spaces, occurred concurrently ($n$ = 22) with no association between case success ($n$ = 35) or aetiology to contrast the two syndromes. Species susceptibility varied, with increased prevalence and incidence rate in *Adelphobates castaneoticus*, *Phyllobates bicolor, P. lugubris, P. terribilis*, *P. vittatus,* and *Dendrobates auratus*, which also had reduced odds of case success (OR = 0.17, P = 0.02). Females experienced hydrocoelom and/or lymphoedema more than three times as often as males. Infections ($n$ = 24), renal disease ($n$ = 26), and gastrointestinal disease ($n$ = 23) were most often identified on postmortem evaluation. Gram-negative bacteria were the most prevalent agent ($n$ = 18). Interstitial nephritis ($n$ = 11), renal cystic dilation ($n$ = 4), and inflammatory gastrointestinal lesions without concurrent parasitism ($n$ = 14) were seen on histopathology. Culture of fluid aspirate was the most predictive antemortem diagnostic (Sens = 71 %, Spec = 55 %), and other diagnostics were noncontributory in identifying noninfectious causes of fluid accumulation. Enrofloxacin treatment increased case success fivefold when compared to untreated cases (OR = 5.82, P = 0.01), and was the only treatment positively associated with case success. These findings underscore the importance of the ability to individually track and treat cases, with fluid culture and enrofloxacin therapy (10 mg/kg PO q24 h) seen as the best first steps following presentation with hydrocoelom or lymphoedema.

## References

*PESSIER AP (2009): Edematous frogs, urinary tract disease, and disorders of fluid balance in amphibians. J. Exotic Pet Med.* ***18****, 4 - 13.*

*VANNEVEL JY (2006): Glomeruonephritis and anasarca in a colony of frogs. Vet. Clin. Exot. Anim.* ***9****, 609 - 619.*

*WRIGHT KM (2001): Idiopathic syndromes. In: Wright KM, Whitaker BR (Eds.). Amphibian Medicine and Captive Husbandry. Malabar, Florida: Krieger Publishing Company, 239 - 244.*

# CONCURRENT RANAVIRUS AND *BATRACHOCHYTRIUM DENDROBATIDIS* INFECTION IN CAPTIVE FROGS (*PHYLLOBATES* AND *DENDROBATES* SPECIES), THE NETHERLANDS, 2012

KIK MJL, STEGE M, BOONYARITTICHAIKIJ R, VAN ASTEN AJAM

Utrecht University, Faculty of Veterinary Medicine, Dept. of Pathobiology, Pathology, Yalelaan1, 3584 CL Utrecht, THE NETHERLANDS; info@kikdierenarts.nl

Ranavirus and *Batrachochytrium dendrobatidis* (*Bd*) infections have been associated with amphibian mass mortalities and population decline worldwide and are considered as emerging infections, therefore the infections have been listed as notifiable by the World Organization for Animal Health. In the Netherlands, ranavirus infection has recently been discovered in wild water frogs (*Pelophylax* spp.) and common newts (*Lissotriton vulgaris*). Ranavirus infection in captivity in Belgium and The Netherlands has only been described in imported red tailed knobby newts (*Tylototriton kweichowensis*). *Bd* infections in Europe have been described in captive poison dart frogs in Germany and in a captive Central American bolitoglossine salamander (*Bolitoglossa dofleini*) in Belgium.

We are the first to report ranavirus infection with concurrent *Bd* infection and mortality in captive *Phyllobates* and *Dendrobates* species in Europe. The die-off began with two *P. bicolor* (black-legged poison frog) followed by five *P. vittatus* (Golfo Dulce poison frog) and five *D. auratus* (green and black poison dart frog). Young as well as adult animals were involved. Clinical signs in the frogs were dry, greyish skin with the animals spending 90 % of their time in the water, anorexia and death. Young metamorphosed tadpoles that just emerged onto the land lay suddenly dead with their hind legs stretched out, and others did not grow well. Some lay dead in the water. Some of the adult frogs still ate but were emaciated, and died after two to three weeks. Three months prior to the first dead *P. bicolor,* the owner had bought a number of used paludariums coated with peat-soil. For enrichment, the owner filled pine cones with springtails (*Collembola*), divided them over the different paludariums and reused the cones. Necropsy was performed on ten of the twelve frogs. The weight of the animals varied from 1 to 6 g. Greyish skin with hepato- and renomegaly was evident. Microscopically, *Batrachochytrium dendrobatidis* was present in the stratum corneum of the hyperkeratotic skins. Intracytoplasmic inclusion bodies were present in erythrocytes and multiple organs. All samples examined tested positive using PCR for the major capsid protein (MCP) gene of ranavirus and the ITS-1–5.8S region of *B. dendrobatidis*. The sequence obtained showed a 99 % identity with the deposited sequence of the MCP gene of the common midwife toad virus (CMTV).

To date, CMTV is known to infect tadpoles of the common midwife toad and juvenile alpine newts, adult water frogs and common newts. More importantly, it is the first time CMTV or a CMTV-like virus has been reported in *Phyllobates* and *Dendrobates* species in captivity. These findings highlight the importance of monitoring ranaviral and *B. dendrobatidis* infections in captive as well as wild amphibians.

## Reference

*KIK M, STEGE M, BOONYARITTICHAIKIJ R, VAN ASTEN A (2012): Concurrent ranavirus and Batrachochytrium dendrobatidis infection in captive frogs (Phyllobates and Dendrobates species), The Netherlands, 2012: A first report. Vet. J.* ***194****, 247 - 249.*

# THE USE OF ALFAXALONE FOR INDUCTION OF ANAESTHESIA IN SELECTED REPTILE SPECIES: A PRELIMINARY CLINICAL INVESTIGATION

WENGER S, WYSS F, PETERSON S, GULL J, HATT JM

University of Zurich, Vetsuisse Faculty, Clinic for Zoo Animals, Exotic Pets and Wildlife, Winterthurer-strasse 260, 8057 Zürich, SWITZERLAND; swenger@vetclinics.uzh.ch

Alfaxalone is a neurosteroid with general anaesthetic properties that binds to γ-aminobutyric acid cell surface receptors. A new formulation of alfaxalone has been used to induce anaesthesia in a variety of reptile and mammalian species (BERTELSEN and SAUER, 2011; SCHEELINGS et al., 2011; KISCHINOVSKY et al., 2013).

The use of alfaxalone as an induction agent was evaluated in 23 clinical cases representing 12 squamate and chelonian reptile species. Anaesthesia was required for surgical and diagnostic reasons such as wound treatment, salpingotomy, cystotomy, ovariectomy, mass removal and CT. The general condition prior to anaesthesia ranged from good to bad. Mean body weight was 941 g (range 20 - 4180 g). Alfaxalone was injected intramuscularly at a dose of 10 - 30 mg/kg. Mean induction time was 21 min (range 7 - 40 min) and depth of immobilisation ranged from deep sedation to surgical anaesthesia. Loss of righting reflex was not achieved in six cases. Two cases (one ball python and one red-eared slider) showed apnea five to ten minutes after administration of alfaxalone. Supplemental analgesia (opioids and non-steroidal anti-inflammatory drugs) was given as deemed necessary in 96 % of the cases. Supplemental isoflurane to perform surgery was administered as required in 61 % of the cases. Mean duration of isoflurane administration was 35 minutes (10 - 180 min). Thirteen animals were manually ventilated during the surgical procedure. Mean time to regaining spontaneous ventilation after discontinuation of isoflurane was 13 minutes (5 - 20 min). Recovery from anaesthesia was smooth. One comb-toed gecko and one leopard gecko, both presenting in poor general condition and requiring surgery due to dystocia, died in the post-operative phase.

Intramuscular administration of alfaxalone was an effective induction agent in most species examined. Supplemental analgesia and/or inhalational anaesthesia are advised for longer or more invasive procedures. Recovery from anaesthesia was rapid. Care must be taken when giving alfaxalone to reptiles with poor general condition.

## References

*BERTELSEN MF, SAUER CD (2011): Alfaxalone anaesthesia in the green iguana (Iguana iguana). Vet. Anaesth. Anal.* ***38****, 461 - 466.*

*KISCHINOVSKY M, DUSE A, WANG T, BERTELSEN MF (2013): Intramuscular administration of alfaxalone in red-eared sliders (Trachemys scripta elegans) – effects of dose and body temperature. Vet. Anaesth. Anal.* ***40****, 13 - 20.*

*SCHEELINGS FT, BAKER RT, HAMMERSLEY G, HOLLIS K, ELTON I, HOLZ P (2011): A preliminary investigation into the chemical restraint with alfaxalone of selected Australian squamate species. J. Herp. Med. Surg.* ***21****, 63 - 67.*

# SONOMORPHOLOGIC DIAGNOSIS OF GENDER, REPRODUCTIVE STATUS, AND HEALTH IN GIANT SALAMANDERS (CRYPTOBRANCHIDAE)

HOLTZE S[1], GÖRITZ F[1], VIELGRADER H[2], SCHAFTENAAR W[3], HERMES R[1], HILDEBRANDT TB[1]

[1]Leibniz Institute for Zoo and Wildlife Research (IZW), Alfred-Kowalke-Str. 17, 10315 Berlin, GERMANY; holtze@izw-berlin.de
[2]Tierärztliche Ordination Tiergarten Schönbrunn, Seckendorff–Gudent Weg 6, 1130 Vienna, AUSTRIA
[3]Rotterdam Zoo, van Aerssenlaan 49, 3039 KE Rotterdam, THE NETHERLANDS

Amphibians currently are among the most endangered vertebrate classes on the planet; about one third of amphibian species are in danger of extinction worldwide. The majority of them have never been kept or bred in captivity. Unfortunately, missing reproductive success is common under captive conditions. This holds true also for the largest of all living amphibian species, the Chinese giant salamander (*Andrias davidianus*), listed as critically endangered by the IUCN. It may reach a length of 1.8 metres and live for more than 50 years. Cryptobranchid salamanders, including also the smaller North-American hellbender (*Cryptobranchus alleganiens*) are monomorphic and extremely difficult to breed in captivity, mainly because of frequent failure to determine gender and to combine suitable breeding pairs. To retain functioning founder populations crucial for their conservation, new tools for the survey of reproductive status, health and the evaluation of assisted reproduction techniques will be needed.
To this end, here, we extended ultrasonographic examinations of a pilot study (HILDEBRANDT et al., 1997) to a total of seven hellbenders and 21 Chinese giant salamanders. Data were acquired over the past 18 years in 11 zoological and private institutions, using portable computersonography (CS 9100, Physia GmbH, Germany or Voluson I, GE healthcare, Austria; 3.5 - 10.0 MHz). It was not necessary to fixate or sedate the animals, as ultrasound under water can be performed without body contact. We hereby were able to not only unequivocally determine gender and female reproductive status, but to further detect various subclinical pathologies of the inner organs, e.g. calcifications in the kidneys that may be indicative of gout.
Sexing as well as estimation of gonadal activity and reproductive capacity, solely based on external morphological traits, is unreliable in many amphibian species. For the latter, we propose the routine use of ultrasound to provide a low-stress assessment of inner organ health and to determine parameters such as the stage of ovarian oocyte maturation. Particularly, the non-invasive determination of reproductive status will be helpful e.g. to choose the optimal time period for the pairing of individuals during the breeding season.

## References

*HILDEBRANDT T, GÖRITZ F, SCHAFTENAAR W, SPELMAN L, ROSSCOE R (1997): Sonomorphologische Geschlechtsbestimmung und Einschätzung der reproduktiven Kapazität bei Riesensalamandern (Cryptobranchidae). Verh. Ber. Zootiere, **38**, 175 - 180.*

# AN EXTENSIVE STUDY: DIAGNOSTIC IMAGING OF NORMAL ANATOMY AND PATHOLOGY IN HOOFED MAMMAL'S DISTAL LIMB

GALATEANU G, HERMES R, GÖRITZ F, SZENTIKS CA, WIBBELT G, HILDEBRANDT TB

Leibniz Institute for Zoo and Wildlife Research (IZW), Alfred-Kowalke-Str. 17, 10315 Berlin, GERMANY; galateanu@izw-berlin.de

Chronic foot disease represents a tremendous clinical challenge and is a major health concern for herbivores in captivity, often being a reason for euthanasia. Currently, radiography is the only imaging technique used to diagnose bone pathology in animals situated under "field conditions". Yet, unlike in elephants, for the other hoofed mammals there are no established radiographic protocols or documented normal radiographic anatomy and pathology. Without improved knowledge on distal limb radiographic imaging, clinical management will remain under the rule-of-thumb.

This study was designed to identify and depict the radiographic appearance of both normal anatomy and pathological changes encountered in autopodium of captive hoofed mammals.

Using state-of-the-art tools of high-resolution, 128-slices, computed tomography (CT), quantitative CT (QCT), digital radiography (DR), synchronised CT-DR and a dedicated workstation, we imaged and analysed autopodial elements including: podial elements (carpus/ tarsus), metapodials (metacarpus/ metatarsus) and phalanges. Distal limb excerpts were analysed post-mortem. A wide variety of species and subspecies were included in our study: Asian elephant (*Elephas maximus*), African elephant (*Loxodonta africana*), white rhinoceros (*Ceratotherium simum*), Indian rhinoceros (*Rhinoceros unicornis*), common hippopotamus (*Hippopotamus amphibious*), pygmy hippopotamus (*Choeropsis liberiensis*), Chapman's zebra (*Equus quagga chapmani*), bongo antelope (*Tragelaphus eurycerus*), Thorold's deer (*Cervus albirostris*), Rocky mountain goat (*Oreamnos americanus*), dromedary camel (*Camelus dromedarius*), Bactrian camel (*Camelus bactrianus*), alpaca (*Vicugna pacos*), Bawean deer (*Axis kuhlii*), roe deer (*Capreolus capreolus*), elk (*Cervus canadensis*), waterbuck (*Kobus ellipsiprymnus*), giraffe (*Giraffa camelopardalis*), cheetal (*Axis axis*), Brazilian tapir (*Tapirus terrestris*), Mongolian gazelle (*Procapra gutturosa*), and Java mouse-deer (*Tragulus javanicus*).

Normal anatomical features and their radiographic appearance were depicted, emphasising the unique traits found in each species. Additionally, this study revealed a large variety of osteopathologies, such as: periosteal reaction, cortical sclerosis, cortical proliferation, bone remodelling with loss of the normal shape, ankylosis, mineralised and osseous bodies found intra- and periarticular (osteophytes and enthesiophytes), new bone production, fractures, osteolysis, bone rarefaction, changes in the trabecular pattern, bone cystic formation and enlargement of the radiolucent linear areas along the distal border of the third phalanx termed "vascular channel". Concomitant presence of several lesions has as an end stage the degenerative joint disease (DJD), osteoarthritis and/ or osteoarthrosis.

The present study demonstrates that bone pathologies are present in hoofed mammals in large variety and with high occurrence. These pathologies in medical imaging were largely overlooked; they were not investigated and, therefore, not acknowledged. Recognising the scarcity of previous data, this study provides important reference data and basis for accurate radiographic interpretation as very useful diagnostic tools for clinicians. Major advances in diagnostic imaging of hoofed mammals' autopodium may constitute an important step in clinical management of foot disorders, providing new possibilities for wildlife management and animal welfare.

# CT DIAGNOSES IN AVIANS SUFFERING FROM UPPER RESPIRATORY DISTRESS

GUMPENBERGER M[1], SCOPE A[2]

[1]University of Veterinary Medicine, Clinic for Diagnostic Imaging, Veterinärplatz 1, 1210 Vienna, AUSTRIA; Michaela.Gumpenberger@vetmeduni.ac.at
[2]University of Veterinary Medicine, Clinic for Poultry, Pet Birds, Reptile and Fish Medicine, Veterinärplatz 1, 1210 Vienna, AUSTRIA

Various avian patients were presented with clinical signs of upper respiratory distress. Radiographs did not provide sufficient information for conclusive diagnoses. CT turned out to be crucial for final diagnosis and therefore prognosis and therapy. Most birds were scanned consciously in upright position in a cardboard box, whereas some were sedated and positioned in ventral recumbency. Quick and effective examination was guaranteed by using a multi-slice helical CT.
The most interesting cases showed tracheal lumen obstruction by aspergillous granuloma, narrowed trachea due to scar tissue after a biting wound as well as a precordial mass.
Limitations of non-sedated patients to be taken into account were movement artefacts. In tiny birds even minimal patient movements interfered with correct diagnoses of small suggested tracheal lesions.

# BILATERAL PHACOEMULSIFICATION WITH INTRAOCULAR LENS IMPLANTATION FOR CATARACT REMOVAL IN MACARONI PENGUIN (*EUDYPTES CHRYSOLOPHUS*)

MODESTO F[1], VANORE M[2]

[1]Ecole Nationale Vétérinaire d'Alfort, Exotics Medicine Service, 7 Avenue du Général de Gaulle, 94700 Maisons-Alfort, FRANCE; florent.modesto@yahoo.fr

[2]University of Montreal, Veterinary Faculty of Saint-Hyacinthe, Dept. of Ophthalmology, 1525 rue des Vétérinaires, J2S 8H5 Saint-Hyacinthe, CANADA

A 22-years-old macaroni penguin (*Eudyptes chrysolophus*) from the Biodôme of Montreal (Canada) was brought to the Veterinary Faculty of Saint-Hyacinthe after it had been diagnosed with a progressive vision loss, associated with a bilateral cataract, for more than six months. The ophthalmologic examination revealed a mature cataract on the right eye and a hyper-mature one on the left eye. Ocular ultrasonography did not yield any evidence of retinal detachment, but a mild degenerated vitreous instead. In order to re-enable normal vision, a phacoemulsification with intraocular lens implantation (11 mm and 41 diopters) was performed bilaterally. The subluxation of the right eye's lens justified the placement of a ring in the capsule before implant insertion, thus enhancing stability. Following the surgery, local treatments (Neomycin, Polymyxin B and Dexamethasone ophthalmic, Hyaluronic acid and Glycerin ophtalmologic) as well as systemic ones (Prednisolone, Tramadol and Itraconazole) have been administered. One week after the procedure, a ventro-lateral movement of the right implanted lens was noticed, but a complete return of vision has been observed two weeks and a half postoperatively. To our knowledge, this is the first documented occurrence of using a lens suited for canines on an amphibious avian species. However, this implant may cause myopia in aerial environment and hyperopia in water, because it is not adapted to Spheniscidae's vision. The lack of data justifies additional studies in order to assess and treat ophthalmological conditions in these species, adapted to a particular lifestyle, in the most appropriate way.

# INFECTIOUS KERATOCONJUNCTIVITIS IN SEMI-DOMESTICATED REINDEER (*RANGIFER TARANDUS TARANDUS*) – CHALLENGES IN TREATMENT

TRYLAND M[1], MØRK T[2], SUNDE M[3]

[1]The Norwegian School of Veterinary Science, Section of Arctic Veterinary Medicine, Dept. of Food Safety and Infection Biology, Stakkevollveien 23, 9010 Tromsø, NORWAY; morten.tryland@nvh.no
[2]National Veterinary Institute, Stakkevollveien 23, 9010 Tromsø, NORWAY
[3]National Veterinary Institute, Ullevålsveien 68, P.O. Box 750, Sentrum, 0106 Oslo, NORWAY

Infectious keratoconjunctivitis (IKC) in semi-domesticated reindeer (*Rangifer tarandus tarandus*) can cause permanent eye destruction. As in cattle, IKC in reindeer is regarded as multi-factorial, and it is not clear which infectious agents are involved. During a previous outbreak of IKC in semi-domesticated reindeer it was indicated that Cervid herpesvirus 2 (CvHV2) was the causative agent.
We investigated serum and swab samples from eyes of healthy and diseased (IKC) reindeer (n = 147).
Cultivation revealed bacterial growth from healthy (71 %) and diseased (70 %) eyes, dominated by Gram negative rods and mixed flora. From one reindeer herd, *Moraxella* sp. was isolated from seven animals with and three animals without IKC, one isolate being characterised as *M. bovoculi* (16S rRNA). Antibodies against CvHV2 were found in 90 % of the animals. CvHV2-specific DNA was found in eye swabs from both healthy and diseased eyes. DNA specific for *Mycoplasma conjunctiva* was detected in five animals. Many challenges exist regarding treatment of an outbreak of IKC in reindeer. Reindeer with IKC needs to be corralled and treated daily for seven to ten days. No specific antibiotic eye ointment is registered for use in production animals in Norway. If CvHV-2 is the initialising agent of IKC in reindeer, anti-herpesvirus treatment, such as Cidofovir, reported in use for cats, horses and cattle, could contribute to an early termination of an IKC outbreak, which could restrict the use and cost of antibiotics as well as limit the animal stress and suffering.

# POSITIVE REINFORCEMENT TRAINING – METHOD AND PRACTICAL EXPERIENCE

DUNGL E

Zoo Vienna/Tiergarten Schönbrunn, Maxingstr. 13b, 1130 Vienna, AUSTRIA; edungl@zoovienna.at

No! – well-trained animals do not necessarily have to be intelligent

No! – there is no contradiction in the use of positive reinforcement training for zoo- and wild animals

No! – positive reinforcement does not mean 'just being nice with the animal'

We speak of positive reinforcement training if a reinforcer is added to the animal's environment as consequence of a wanted behaviour. A reinforcer is something that strengthens the dimension of a certain behaviour concerning rate, duration, magnitude or latency. The scientific concept used in animal training is operant conditioning, which means that behaviour can be modified by the consequences that follow them (RAMIREZ, 1999).

Taking blood of a giant panda with full consciousness at an appointed time within five minutes can become self-evident. This and other examples of the training programmes at Zoo Vienna/Tiergarten Schönbrunn should deliver insight into the potential of positive reinforcement training for medical care and mental stimulation.

The physical and mental well-being in zoo animals is within the responsibility of the keepers, zoologist, nutritionists and of course vets of an institution. There are several good reasons to establish a positive reinforcement training programme for a certain species but the well-being of the animal should be of top priority.

## References

*RAMIREZ K (1999): Animal Training: Successful Animal Management Through Positive Reinforcement. Chicago: Shedd Aquarium.*

# TIGER–HUMAN CONFLICT RESOLUTION TRAINING IN INDONESIA, TRANSFERRING ZOO VET EXPERTISE TO THE FIELD

STRIKE T[1], CHRISTIE S[1], LEWIS J[2], PRIATNA D[1,3], SUDARWATI R[4]

[1]Zoological Society of London, Regent's Park, London, NW1 4RY, UK; tai.strike@zsl.org
[2]Wildlife Vets International, Station House, Parkwood Street, Keighley, West Yorkshire, BD21 4NQ, UK
[3]Sumatran Tiger Conservation Forum, Jl. Samiaji 3/10, Bogor, 15153, INDONESIA
[4]Taman Safari Indonesia, Jl Raya Puncak 601, Cisarua, Bogor, 16750, INDONESIA

An estimated 300 wild Sumatran tigers (*Panthera tigris sumatrae*) inhabit the island of Sumatra. Human encroachment into these tigers' territories is reducing available tiger habitat through habitat loss, degradation and fragmentation. Snares set for wild ungulates in and around tiger territories often result in the inadvertent snaring of tigers. The consequent increase in tiger-human conflict results in frequent tiger deaths as well as occasional loss of human life and of livestock. Between 1998 and 2011, 563 cases of such conflict have been reported, resulting in 57 human deaths and 46 tiger deaths. Education programmes exist to reduce these outcomes. However, in order to save tigers caught in conflict situations, specialist teams need to be created and to have rapid access to a suitably-trained veterinarian. Most veterinarians in Sumatra are not trained or equipped for this work. Zoo veterinarians, together with expert field veterinarians and biologists, have the requisite skills to provide specialist practical training to local veterinary surgeons on safe techniques to assess, immobilise, obtain samples from, treat and make outcome based decisions for these tigers.

Guidelines for the health and handling of conflict tigers were recently devised at a workshop for this purpose held on Java. The workshop was attended by national and international zoo veterinarians and tiger ecology experts, veterinarians from Sumatra, and officials from the Indonesian Ministry of Forestry. These guidelines address protocols for the capture, immobilisation, health assessment and welfare of the conflict animal. They also address the three primary outcomes for these animals: translocation with immediate release in the wild; capture and relocation to a short or long term captive environment with or without treatment; and euthanasia if appropriate to prevent undue suffering or risk of the spread of infectious disease.

Euthanasia is a contentious issue in such a critically endangered flagship species and local concerns about euthanasia must be addressed. A veterinarian must establish a clear chain of command from first contact with a conflict animal to evaluation. This command structure must be able to decide between translocation, with or without treatment, and euthanasia, often based on incomplete information. In order to be effective, the command chain must have the support of Indonesian government ministers, local officials, veterinarians and other stakeholders.

Well-trained zoo veterinarians will play an important role in providing practical training, practiced in a zoo environment but applicable to wild animals. They will also assist with the establishment of a local knowledge base and veterinary network ensuring access to international expertise, and to keep the guidelines up to date. These guidelines should be ratified by the government departments under which the affected animals fall in order to give local veterinarians the authority needed in the decision making processes.

# GIRAFFE TAMER TRAINING: HOOFTRIMS, BLOOD COLLECTION AND ULTRASOUND MADE EASY

LUEDERS I[1,2], POOTOOLAL J[3], LÉCU A[4]

[1]GEOlifes - Animal Fertility and Reproductive Research, Frohmestr. 7, 22457 Hamburg, GERMANY; imke.lueders@geolifes.com
[2]University of the Western Cape, Dept. of Medical Biosciences, Bellville 7535, SOUTH AFRICA
[3]African Lion Safari, Cooper Road, Cambridge, Ontario, CANADA
[4]Parc Zoologique de Paris, 53 avenue de St Maurice, 75012 Paris, FRANCE

Giraffes are one of the most difficult zoo mammals when handling or medical intervention is required. This is rather due to their awkward shape and special physiology then to their temper. Target training is one possibility to practice useful behaviours, but is limited when it comes to more invasive procedures. Chemical immobilisation still bears high risks to giraffes. In order to provide adequate care for this species and to enable several medical procedures without anaesthesia, a commercially available restraint device (Fauna research tamer, www.faunaresearch.com/giraffe.htm) was installed in two facilities, holding 13 and 17 giraffes, respectively. The tamer was built into a hallway, leading either to the outdoor enclosure or another indoor pen. It has a sliding gate at front and rear to confine the animal. A cushioned push panel and two belly straps allow for further securing the giraffe within the tamer. Another eight doors allow the access to several body parts. For safety reasons, an emergency side- exit can be opened to release the animal. Under the floor a scale can be installed for weight monitoring. This setting needs two to three operators to work safely.

Giraffes of all ages and both sexes were habituated to walk through the opened tamer every day, before they were eventually stopped within it to receive treats. Basic training took six to eight weeks in adult giraffes with 5 to 30 minutes spent per animal at least every other day.

When fully trained, the giraffes accepted daily blood collection from the jugular vein, oral medication, IM/SC injections by hand, hoof trims, transrectal palpation and ultrasound. Females further tolerated dystocia management, transcervical catheterisation (embryo transfer catheter, artificial insemination), faecal collection from the rectum for hormone analysis and milking, while in a breeding male semen was collected via prostate massage.

The advanced training level opened the possibility to study the reproduction physiology. During daily ultrasound, blood and faecal collections, the ovarian activity was studied, leading to detailed knowledge on ovulation timing, corpus luteum formation and secretion of hormones such as progesterone, estradiol, LH, inhibin and FSH. The intensive monitoring helped the reproductive research and the breeding management of the herd. This example shows that giraffes can be trained safely, not only to targets, but also to be restraint, for proper access and care.

# OCCUPATIONAL ENRICHMENT AND ITS INFLUENCE ON THE DIURNAL ACTIVITY OF CAPTIVE BORNEAN ORANGUTANS (*PONGO PYGMAEUS*)

JAMALUDDIN NS[1], SHARMA RSK[2,3], SUMITA S[1,2*]

[1]Universiti Putra Malaysia, Faculty of Agriculture, Dept. Animal Science, 43400 UPM Serdang, Selangor, MALAYSIA; sumi@upm.edu.my

[2]Universiti Putra Malaysia, Wildlife Research & Conservation Centre, 43400 UPM Serdang, Selangor, MALAYSIA

[3]Universiti Putra Malaysia, Faculty of Veterinary Medicine, Dept. Veterinary Pathology & Microbiology, 43400 UPM Serdang, Selangor, MALAYSIA

Diurnal activities of four captive Bornean orangutans (*Pongo pygmaeus*) housed at a local zoological park in Malaysia were documented over a period of 36 days. Since the zoological park has a collection of both Bornean and Sumatran orangutans, the management exhibited the two species separately on an alternate day rotation. On days when a specific group did not have access to the outdoor exhibit, they were released from their night dens into an indoor off-exhibit enclosure. This study comprised three phases: baseline (pre-enrichment), enrichment and post-enrichment. Tied bundles of coconut leaves were provided as enrichment items, and were replenished daily. Data were collected using instantaneous scan sampling every 10 minutes, between 1000 and 1630 hours daily. The orangutans were generally inactive for a significant proportion of the time in their indoor off-exhibit (44.8 ± 4.4 %) as well as in their outdoor (42.3 ± 5.8 %) enclosures. Peaks of activity were observed early in the morning when they were released into their respective enclosures, and just before they returned to their night dens at the end of the day. Provision of the novel enrichment item resulted in an increase in locomotion, solitary play and investigative behaviours, irrespective of the enclosure that they were housed in. Although the occurrence of abnormal behaviour was generally low in both enclosures, it was more predominant when they were housed outdoors. Begging was the most prevalent abnormal behaviour recorded among the orangutans when they were housed outdoors, followed by regurgitate, throwing objects and spitting. Begging was only observed in the presence of zoo visitors with food items. The provision of the enrichment item did not significantly alter ($P > 0.05$) the frequency of begging between the three phases. In the indoor enclosure, where there was no visitor access, the orangutans performed head twirling and patrolling, and frequently threw around objects in the enclosure. The frequency of head twirling during the pre-enrichment phase was 50.0 ± 0.4 %, and it increased to 66.7 ± 0.5 % when the enrichment item was available. Head twirling decreased to that of baseline levels, once the enrichment item was removed. Patrolling was only observed during the enrichment phase, and increased from 33.3 ± 0.4 % to 50.0 ± 0.4 % following the withdrawal of the enrichment item. The increase in the frequency of abnormal behaviours while the animals were housed indoors may be influenced by the limited space and lack of sufficient furniture in their indoor enclosure. The coconut leaves were utilised more while they were in their indoor off-exhibit enclosure, and the apes spent less time in contact with the enrichment items when they were housed outdoors. This study has shown that the provision of a simple and cheap enrichment item can stimulate natural behaviours in orangutans, especially when they are housed in barren enclosures. It is therefore essential to provide environmental enrichment to zoo apes in barren and non-stimulating enclosures to encourage the development of natural activities and reduce the incidence of abnormal behaviour.

# DEVELOPMENT OF A CAPTIVE VETERINARY CARE PROGRAMME IN ARABIAN SAND CATS (*FELIS MARGARITA HARRISONI*) AT AL WABRA WILDLIFE PRESERVATION, QATAR

SCHILP CM, HEBEL C, ARIF A, BOUTS T

Al Wabra Wildlife Preservation (AWWP), P.O. Box 44069, Doha, STATE OF QATAR;
cschilp@alwabra.com

The Arabian sand cat (*Felis margarita harrisoni*) is a felid species found in the deserts of the Arabian Peninsula that prefers flat or sloping terrains with scarce vegetation. Sand cats are currently listed as near threatened on the Red List (2008) of the International Union for Conservation of Nature (IUCN). Several institutions around the world, including Al Wabra Wildlife Preservation (AWWP), participate in the European Endangered Species Programme (EEP) to propagate and conserve this species. To improve the veterinary management of Arabian sand cats the veterinary department at AWWP collected valuable veterinary medical data about this species during the yearly health check of the 19 individuals living at the facility.

All individuals received general anaesthesia. Induction was either by intramuscular (IM) injection of 0.05 mg/kg medetomidine and 3 mg/kg ketamine (n = 11) or by mask induction with 5 volume% isoflurane and 4 L/min oxygen (n = 10). Animals were intubated and anaesthesia was maintained with 2 L/min oxygen with or without isoflurane depending on the induction protocol. Depth of anaesthesia was monitored by checking jaw tone, eyelid reflexes and monitoring heart and respiration rates. Animals were either allowed to recover spontaneously (isoflurane group) or 0.125 mg/kg atipamezole was administered IM after the procedure (medetomidine-ketamine group). Whole body lateral and ventrodorsal (VD) radiographs were taken and analysed. Heparinised blood samples taken from the jugular vein were analysed for routine haematology and biochemistry. All animals appeared healthy on clinical examination.

The anaesthetic protocols were compared using unilateral variance analysis (ANOVA). Radiographic measurements of thoracic and abdominal structures were taken using metric and vertebral scale systems and were compared to measurements in domestic cats (*Felis catus*). Haematology and biochemistry reference values were determined for the species.

The development of normal baseline parameters has allowed improved veterinary care for captive sand cats at this institution as it will be easier to diagnose abnormalities based on these guidelines.

# ESTABLISHING GUIDELINES FOR THE ASSESSMENT OF ZOO ANIMAL WELFARE, MANAGEMENT AND ENCLOSURE DESIGN IN SOUTHEAST ASIA

SHARMA RSK[1,2], SUMITA S[1,3]

[1]Universiti Putra Malaysia, Wildlife Research and Conservation Centre, 43400 UPM Serdang, Selangor, MALAYSIA; reuben@vet.upm.edu.my

[2]Universiti Putra Malaysia, Faculty of Veterinary Medicine, 43400 UPM Serdang, Selangor, MALAYSIA

[3]Universiti Putra Malaysia, Faculty of Agriculture, Dept. of Animal Science, 43400 UPM Serdang, Selangor, MALAYSIA

The assessment of captive animal welfare and the accreditation of zoological facilities have become focal issues for many zoological parks worldwide. In Southeast Asia, the welfare standards at many captive wildlife facilities have attracted global attention, and their purpose as centres of education and conservation are under constant scrutiny. As such, many Southeast Asian zoos have recognised that there is a driving need for guidelines and standards to be established in areas of animal management, enclosure design and animal welfare. In Malaysia alone, there are over 40 public and private zoological parks and the improvement of animal welfare is a national concern. The proposed guidelines on the assessment of zoo animal welfare, management, and enclosure design places emphasises on providing a suitable physical, physiological and psychological environment for the animals. Focal areas include space requirements, provision of suitable furniture, substrate and enrichment, feeding regime and diet, management of zoo records, improvement of waste management and sanitation, and protocols for safety, biosecurity, and disease monitoring. While these guidelines for the assessment and accreditation of zoos do not claim to be absolute, it is envisaged to provide a positive direction to the gradual improvement in the welfare standards and management of captive wild animals in the region. The need to establish standards for zoo animal welfare is of global concern. It is therefore timely that internationally accepted criteria and guidelines be established to serve as a beacon for the zoo community worldwide.

# SHORT-RANGE NET GUNS – AN ALTERNATIVE IMMOBILISATION METHOD

HAMMER S, HAMMER C

Naturschutz-Tierpark, Zittauerstr. 43, 02826 Görlitz, GERMANY; s.hammer@tierpark-goerlitz.de

The zoo veterinarian's first question is always: how to get hold of my patient? Compared to the classical curative veterinary praxis, where the pet's owner delivers the patient - on the leash or in a container - a zoo- and wildlife veterinarian always has to carefully consider the most suitable choice for immobilisation of the particular wildlife patient prior to diagnostics or treatment. The short-range gas-powered net gun is a capture system that might, under certain circumstances, be an appropriate and practical alternative to chemical distance immobilisation, classical net catching, or stationary catching devices.

Short-range gas-powered net guns are in use by the police, the military, or as private self-defence equipment. First modifications have been made to use it also as an animal capture tool - a complete turn-around of the original design aimed at keeping an aggressor at a distance. With some modifications for animal capture, the system is already working well in different bird species. A gas cartridge power short-range net gun has an operation range of 7 to 12 metres and rubber-covered weights. It can also be used in confined spaces. To become familiar with the handling and the flight characteristics, it is advised to start with some training shots.

Net guns can be used for the capture of birds, reptiles and small mammals up to 25 kg. Particularly for the quick catching of small and medium sized birds the net gun is useful. We were able to catch targeted birds in midair up to 10 m height. The best catching result is obtained when the animal is hit frontally. Fleeing animals are best hit from the side. The relatively loud detonation is ideal in case of defence, but when catching an animal, one should consider that this could boost the animal's avoidance reaction.

For the catching of individuals, the net weights do not pose a health risk. Due to the funnel shaped shot, the weights will always be off the target object. There is a slight risk for individual birds that are not sitting in the centre of the net, when captured. In this case the weights could cause damages / leg-fractures. We regard this risk as rather low, as long as the weights are properly covered with rubber (caution - weight and design differ from manufacturer to manufacturer). Nets are offered with the following mesh sizes: 20×20 cm, 15×15 cm, 10×10 cm and 5×5 cm. The volume of the funnel shaped net container is quite limited; therefore one must be aware that a smaller mesh size also means a smaller net surface. Thus, the sizes of the nets differ from 4 m² to 12 m². The numbers of net weights vary from manufacturer to manufacturer. There are nets with ten, eight or only with four weights. To our experience, four weights are sufficient. With fewer weights, one reduces the time for untangling and repacking distinctively. Depending on the manufacturer, 12 g $CO_2$ or 8 g $N_2O$ cartridges are used. The minimum shooting distance is about three meter; at shorter range, the net will not sufficiently span and the animal might escape. For reuse, it is important to disentangle the discharged net on a clean ground. After removal of the weights, dirt and objects, the net will eventually disentangle on its own when shaken. When disentangled, the net is placed on the ground, in order to fix the weights at their designated ends before reloading. At the EAZA Conference 2012 in Innsbruck many curators and veterinarians have seen these devices and for animal welfare reasons it could become a proper tool to catch small animals e.g. birds. We advise against purchasing from online-shops because neither warranty nor quality are convincing. In summary, we can say: we had a lot of fun testing all those devices, and are convinced that we found an effective capture technique with the "Gladiator" from Zooprofis, Germany (www.zooprofessionals.de).

# POLYCYSTIC KIDNEY DISEASE IN BRAZILIAN AGOUTIS (*DASYPROCTA LEPORINA*) – A HEREDITARY CONDITION

DELNATTE P[1,2], COTE O[1], DUTTON CJ[2], BIENZLE D[1], SMITH DA[1]

[1]University of Guelph, Ontario Veterinary College, 50 Stone Road, Guelph, Ontario N1G 2W1, CANADA; cdutton@torontozoo.ca
[2]Toronto Zoo, 361A Old Finch Avenue, Toronto, Ontario M1B 5K7, CANADA

Autosomal dominant polycystic kidney disease (PKD) is a hereditary condition characterised by the progressive development of bilateral renal cysts, eventually leading to renal failure. Two captive-born female Brazilian agoutis (*Dasyprocta leporina*) were presented with a history of lethargy and weight loss. Physical examination and additional diagnostic tests showed poor body condition, regenerative anaemia, elevated BUN and creatinine, hypercalcaemia, hyperphosphataemia, haematuria, soft tissue calcification and renomegaly with multiple cysts. Gross necropsy and histopathology on both animals confirmed severe PKD and metastatic calcification. PKD has been previously reported in agoutis in Germany. A mutation located in exon 29 of the PKD1 gene was found in the two affected animals but not in ten control animals from the Toronto Zoo. Retrospective analysis of medical and post mortem records of agoutis across several North American institutions revealed similar pathological findings in seven related individuals. Tissues from a total of 41 affected and non-affected agoutis were obtained in order to assess the association between the mutation in PKD1 gene and the presence of renal cysts. We identified 28 animals with wild type genotype, nine animals with heterozygous mutation and four animals with homozygous mutation. The mutation correlated positively with the presence of polycystic changes in kidneys. All animals but one with the mutation showed histological evidence of polycystic changes, however, not every animal with polycystic changes was mutated. Polycystic kidney disease in Brazilian agoutis appears thus to be a hereditary condition. We recommend testing for this mutation as part of management of captive breeding programmes in this species.

# PATHOLOGICAL LESIONS ASSOCIATED WITH CHRONIC INDUSTRIAL FLUORIDE TOXICOSIS IN AUSTRALIAN MARSUPIALS

DEATH C[1], HUFSCHMID J[1], COULSON G[2], BEVERIDGE I[1]

[1]The University of Melbourne, Faculty of Veterinary Science, 250 Princess Hwy, Werribee, VIC, 3030, AUSTRALIA; dclare@unimelb.edu.au
[2]The University of Melbourne, Dept. of Zoology, Royal Parade, Parkville, VIC, 3010, AUSTRALIA

Particulate and gaseous fluoride emissions contaminate vegetation surrounding fluoride-emitting industry, with potential for skeletal and dental disease following long-term consumption by herbivorous wildlife. This condition has been studied in livestock and game species throughout Europe and North America. Eastern grey kangaroos (*Macropus giganteus*) resident near an aluminium smelter in south-eastern Australia have been affected by chronic fluoride toxicosis. In the current study we extend the investigation to other species of marsupials. We discuss dental and skeletal pathology in relation to species, age, bone fluoride concentration and location relative to the emission source. Necropsy examinations of red-necked wallabies (*Macropus rufogriseus*), swamp wallabies (*Wallabia bicolor*), koalas (*Phascolarctos cinereus*), brushtail possums (*Trichosurus vulpecula*) and ringtail possums (*Pseudocheirus peregrinus*) from the smelter site have revealed varying degrees of skeletal and dental lesions consistent with fluorosis. Through better understanding of how dietary fluoride exposure leads to clinical fluorosis in marsupials, including further description of the associated epidemiology and pathology, we aim to improve welfare outcomes and produce management options that may prevent disease in marsupials resulting from industrial fluoride emissions.

# CARDIAC PATHOLOGY IN MEDITERRANEAN DOLPHINS

SCAGLIONE FE[1], BOLLO E[1], PREGEL P[1], CHIAPPINO L[1], SERENO A[1], MIGNONE W[2], MOSCHI R[3], GARIBALDI F[4], TITTARELLI C[2], GUARDA F[1]

[1]Università degli Studi di Torino, Dipartimento di Scienze Veterinarie, 10095 Grugliasco, ITALIA; frineeleonora.scaglione@unito.it

[2]Istituto Zooprofilattico Sperimentale del Piemonte, Liguria e Valle d'Aosta, Sezione di Imperia, 18100 Imperia, ITALIA

[3]ASL 1 imperiese, Bussana di Sanremo, 18038 Sanremo, ITALIA

[4]Università degli Studi di Genova, Dipartimento di Scienze della Terra, dell'Ambiente e della Vita, 16132 Genova, ITALIA

## Summary

Nine striped dolphins (*Stenella coeruleoalba*) and one bottlenose dolphin (*Tursiops truncatus*) stranded along the Ligurian sea coast of Italy were examined.

Macroscopically the hearts showed pulmonary aneurysms, cirsoid aneurysms, enlarged right ventricle, hypoplasia of the tricuspid chordae, valvular fibrosis, mitral leaflet thickening and left ventricular hypertrophy.

Histological evaluation of samples showed a case of lymphocytic myocarditis, several cases of Lambl's excrescences as well as confirming macroscopic findings.

To the authors' best knowledge Lambl's excrescences, pulmonary aneurysms and cirsoid aneurysms have never been previously described in marine mammals.

## Introduction

Little is known about the structure and pathologies affecting the cetacean heart (SEDMERA et al., 2003), since they have been poorly studied in marine mammals. Moreover few cases of heart disease, mostly concerning malformations (SLIJPER, 1961; GRAY et al., 1974; NEUROHR, 1982; TRONCONE and ZIZZO, 2004; POWELL et al., 2009), have been reported.

Heart malformations and congenital anomalies are rarely observed in Atlantic bottlenose dolphins (*Tursiops truncatus*) and other delphinids, and are mainly reported in stillborn or neonate cetaceans. The aim of this study is to evaluate heart pathologies in stranded adult dolphins.

## Material and methods

Nine striped dolphins (*Stenella coeruleoalba*) (seven males and two females) and one male bottlenose dolphin (*Tursiops truncatus*) stranded along the Ligurian sea coast of Italy from February 2011 to April 2012 were examined (table 1). Age classes were determined (sub-adults: case nos. 6 and 10; adults: all the other animals), and field necropsies were performed on all animals to ascertain the cause of death. Hearts were fixed in 10 % neutral buffered formalin (pH 7), referred to the Department of Veterinary Science of the University of Turin (Italy), and macroscopically examined.

Tissue samples from hearts were wax-embedded, sectioned at 4 µm using a microtome (Leica Microsystems, Wetzlar, Germany), and stained with Haematoxylin and Eosin (HE), and Weigert-Van Gieson stainings (WVG).

## Results and discussion

Macroscopic evaluation of the hearts revealed in three cases (nos. 1, 7 and 9) a white, elevated, well demarcated, ovoidal area adjacent the pulmonary ostium. These findings were classified as aneurysms of the pulmonary trunk. The wall of the pulmonary artery, in all the observed cases, was atrophic, compared to a normal artery.

One dolphin (case no. 1) also showed enlargement of the right ventricle, hypoplasia of the tricuspid chordae, tricuspid insufficiency due to fibrosis, thickening and retraction of the leaflets, and an interventricular white spot, 0.2 cm in diameter, adjacent to the papillary muscle, caused by a focal lymphocytic myocarditis. Mitral fibrosis (case no. 2), mitral leaflet thickening (case no. 4) and mitral insufficiency caused by fibrosis associated with left ventricular hypertrophy (case no. 6) were also observed. Case no. 4 also presented winding course of the left subepicardial coronary artery, which, at the cut surface, revealed dilated arteries surrounded by connective tissue, allowing a diagnosis of cirsoid aneurysm.

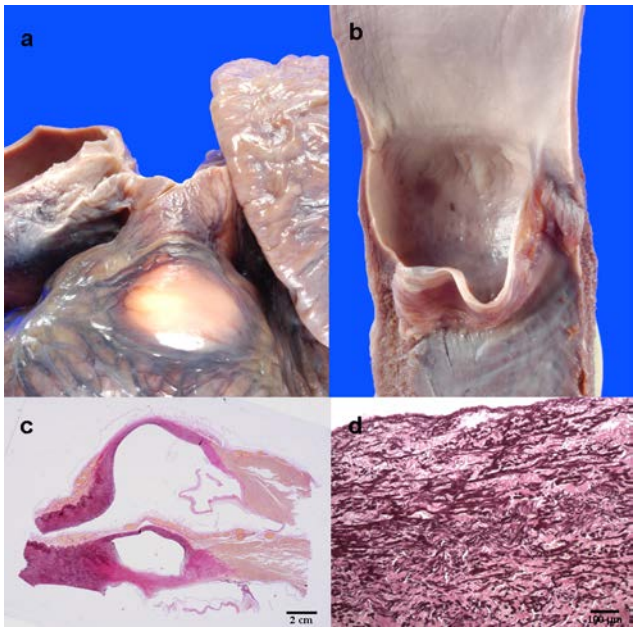


*Fig. 1: Case no. 1, Stenella coeruleoalba, pulmonary artery: a) white, elevated, well demarcated, ovoidal area classified as aneurysm of the right sinus of Valsalva; b) endothelial surface of the aneurysm of the right sinus of Valsalva; c) thinning of the pulmonary arterial wall (WVG 2X); d) thick, shattered and randomly arranged elastic fibres of the pulmonary arterial wall (WVG 200X).*

Histologically, the aneurysms of the pulmonary artery (case nos. 1, 7 and 9) showed a thinner wall compared to a normal one. WVG stain revealed thick, shattered and randomly arranged elastic fibres.

The walls of a limited number of cirsoid aneurysms revealed the presence of intimal digitations. Necrosis and pyknosis were detected in smooth muscle cells and nuclei of the tunica media in some arteries. Arteriovenous anastomosis was not detected.

In five animals histological examination of the mitral leaflets (case nos. 2, 4 - 6) and of the tricuspid leaflets (case no. 1) showed thickening of the spongiosa caused by proliferation of fibroblastic tissue, deposition of eosinophilic interstitial matrix, and degeneration of the fibrosa, revealing myxoid degeneration in the central fibrous core. Four dolphins (case nos. 1, 2, 4 and 6) showed also small pointed projections from the edges of the valve cusps, identified as Lambl's excrescences.

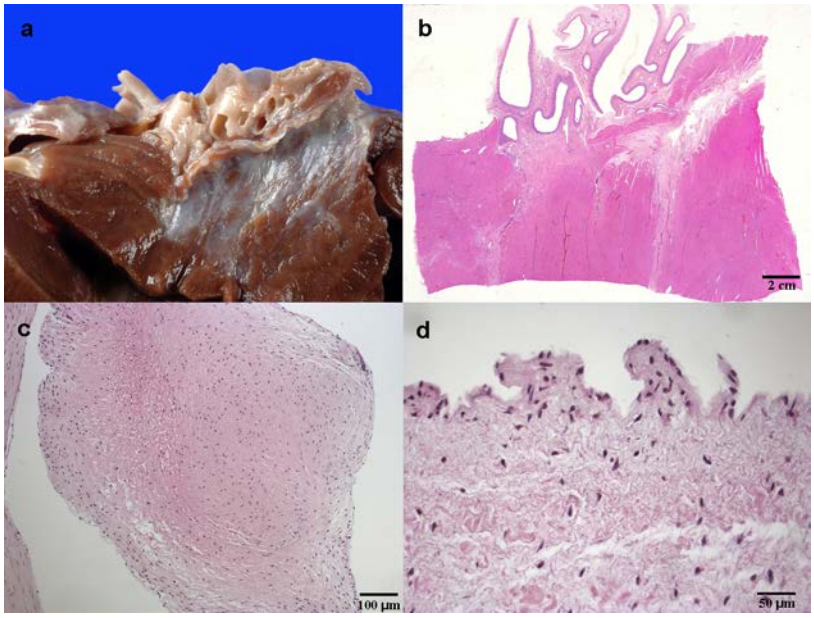


*Fig. 2: Stenella coeruleoalba: a) case no. 4: cut surface of the left subepicardial coronaric artery: cirsoid aneurysm; b) case no. 4: histological features of cirsoid aneurysm: dilation and twisting lengthening of the coronary artery surrounded by connective tissue; c) case no. 5: thickening of the mitral spongiosa caused by myxoid degeneration in the central fibrous core (HE 200X); d) case no. 6: Lambl's excrescences (HE 400X).*

The aneurysms of the pulmonary artery were detected only in adult subjects; on the contrary, Lambl's excrescences and alteration of the mitral leaflet were present in adult and sub-adult animals. Because of the low number of cases, these data cannot be statistically evaluated.
Dolphin cardiac diseases are very complex, and they present interesting similarities with and differences from terrestrial mammals and human pathology.
To the authors' best knowledge Lambl's excrescences, pulmonary aneurysms and cirsoid aneurysms have never been previously described in marine mammals.

## Acknowledgements

The authors gratefully acknowledge the "Centro di Referenza di Patologia Comparata Bruno Maria Zaini", Italy.

*Tab. 1: Necropsy findings, gross and microscopic heart lesions.*

| No. | Species | Age | Sex | Length | Weight | Gross heart lesions | Microscopic heart lesions |
|---|---|---|---|---|---|---|---|
| 1 | *Stenella coeruleoalba* | Adult | M | 194 cm | 73 kg | Enlarged right ventricle; aneurysm of the right sinus of Valsalva; hypoplasia of the tricuspid chordae; valvular fibrosis; interventricular white spot | Aneurysm of the right sinus of Valsalva; tricuspid fibrosis; Lambl's excrescences; lymphocytic myocarditis |
| 2 | *Stenella coeruleoalba* | Adult | F | 188 cm | 68 kg | Mitral fibrosis | Mitral fibrosis; Lambl's excrescences |
| 3 | *Stenella coeruleoalba* | Adult | M | 203 cm | 73 kg | Marked auto-lysis and putrefaction | Marked autolysis and putrefaction |
| 4 | *Stenella coeruleoalba* | Adult | M | 194 cm | 65 kg | Cirsoid aneu-rysms; mitral leaflet thickening | Cirsoid aneu-rysm; mitral fibrosis; Lambl's excrescences |
| 5 | *Stenella coeruleoalba* | Adult | F | 203 cm | 76 kg | Abscence of gross lesions | Mitral fibrosis |
| 6 | *Stenella coeruleoalba* | Sub-adult | M | 136 cm | 26 kg | Left ventricular hypertrophy | Mitral fibrosis; Lambl's excrescences |
| 7 | *Stenella coeruleoalba* | Adult | M | 208 cm | 63 kg | Aneurysm of the right sinus of Valsalva | Aneurysm of the right sinus of Valsalva |
| 8 | *Stenella coeruleoalba* | Adult | M | 205 cm | 73 kg | Abscence of gross lesions | Abscence of microscopic lesions |
| 9 | *Stenella coeruleoalba* | Adult | M | | 70 kg | Aneurysm of the right sinus of Valsalva; mitral fibrosis | Aneurysm of the right sinus of Valsalva |
| 10 | *Tursiops truncatus* | Sub-adult | M | 181 cm | | Abscence of gross lesions | Abscence of microscopic lesions |

## References


*GRAY KN, CONKLIN RH (1974): Multiple births and cardiac anomalies in the bottle-nosed dolphin. J. Wildl. Dis **10**, 155 - 157.*

*NEUROHR B (1982): Herzfehler bei einem Großen Tümmler (Tursiops truncatus). Verhandlungsbericht des International Symposiums über die Erkrankungen der Zootiere **24**, 55 -56.*

*POWELL JW, ARCHIBALD RT, CROSS CA, ROTSTEIN DS, SOOP VM, MCFEE WE (2009): Multiple congenital cardiac abnormalities in an Atlantic bottlenose dolphin (Tursiops truncatus). J. Wildl. Dis. **45**, 839 - 842.*

*SEDMERA D, MISEK I, KLIMA M, THOMPSON RP (2003): Heart development in the spotted dolphin (Stenella attenuata). Anat. Rec. A Discov. Mol. Cell. Evol. Biol. **273**, 687 - 699.*

*SLIJPER J (1961): Foramen ovale and ductus arteriosus Botalli in aquatic mammals. Mammalia 25, 528 - 570.*

*TRONCONE A, ZIZZO N (1994): Malformazione cardiovascolare in un delfino (Stenella coeruleoalba). ODV **15**, 67 - 68.*

# DEVELOPING GLOBAL CAPACITY FOR PREDICTION AND PREVENTION OF EMERGING ZOONOTIC DISEASES OF WILDLIFE

AGUIRRE AA[1,2]

[1]Smithsonian-Mason School of Conservation, 1500 Remount Rd., Front Royal, Virginia, USA; aaguirr3@gmu.edu
[2]George Mason University, Dept. of Environmental Science and Policy, 4400 University Drive, Fairfax, Virginia, USA

## Summary

Conservation Medicine and more recently EcoHealth have emphasised the need to bridge disciplines, thereby linking human health, animal health, and ecosystem health under the paradigm that "health connects all species in the planet" with the urgent need to address the emergence and resurgence of zoonotic diseases. Emerging zoonotic diseases are a major threat to public health globally. These diseases emerge from wildlife or livestock, and include HIV/AIDS, SARS, Ebola, Nipah and H5N1 avian influenza. Key factors that drive emergence are related to human changes to the environment, agriculture, healthcare and demography, all against a background of a large pool of potential new zoonoses. We are establishing a global early warning system that is capable of detecting, tracking, and predicting the emergence of new infectious diseases in high-risk wildlife (e.g. bats, rodents, and non-human primates) that could pose a major threat to human health. The geographic scope of this expanded effort is directed to those zoonotic "hotspots" of wildlife origin. Our strategy targets important sentinel species at active human interfaces to improve surveillance deficiencies at these hotspots. We perform collaborative assessments of local capacity, creating infectious disease modelling, introducing new technologies and cutting edge information management and communication tools with the potential to bring the world closer to an integrated, global approach to emerging zoonoses.

## Introduction

Conservation Medicine and more recently EcoHealth have emphasised the need to bridge disciplines, thereby linking human health, animal health, and ecosystem health under the paradigm that "health connects all species in the planet" with the urgent need to address global emerging and resurgent zoonotic diseases of wildlife (AGUIRRE et al., 2002). The recent convergence of global problems including climate change, biodiversity loss, habitat fragmentation, globalisation, infectious disease emergence and ecological health demanded integrative approaches breaching disciplinary boundaries. This integration requires commitment not only from government agencies, universities and non-government organisations, but eventually will attempt to generate new international structures. Emerging zoonotic diseases are a major threat to public health globally. These diseases emerge from wildlife or livestock, and include HIV/AIDS, SARS, Ebola, Nipah and H5N1 avian influenza. Key factors that drive emergence are related to human changes to the environment, agriculture, healthcare and demography, all against a background of a large pool of potential new zoonoses. The International Union for Conservation of Nature (IUCN) maintains a Red List of threatened species - an important initiative in view of the 869 animal extinctions that have already occurred, of which 3.7 % were caused by disease (SMITH et al., 2006).

## Zoonotic disease emergence

Zoonotic diseases “emerge” when environmental changes and/or changes in human activities alter the relationship between people and animals and provide new opportunities for pathogens to spread to people. Rather than respond to the disastrous effects after they have emerged, our collaborations attempt to prevent these diseases from ‘spilling over’ from animals to humans or to halt them rapidly after that spillover by understanding what factors induce emergence and rapidly identifying ways of prevention, control, and mitigation. It is evident that the world’s pandemic prevention strategy is only beginning to take this broader view, as it has traditionally focused on the machinations of each pathogen strain and on the politics of surveillance, reporting, and trade regulation. The key factors that drive the emergence of new zoonotic diseases are related to a combination of human changes to the environment, agriculture, healthcare, and changes in demography, all against a background of a large pool of potential new zoonoses.

## Building global capacity

The U.S. Agency for International Development (USAID) has been a major leader in the global response to the emergence and spread of Highly Pathogenic Avian Influenza (HPAI). Since mid-2005, it has programmed approximately $500 million to build capacities in more than 50 countries for monitoring the spread of HPAI among wild bird populations, domestic poultry, and humans, and to mount a rapid and effective containment of the virus when it is found. Recent analyses indicate that these efforts have contributed to significant downturns in reported poultry outbreaks and human infections and a dramatic reduction in the number of countries affected. The *Global Avian Influenza Network for Surveillance* (GAINS) conducted active surveillance of highly pathogenic avian influenza in wild bird populations. Sponsored by USAID and the CDC, GAINS was begun in 2006 and administered by the Wildlife Conservation Society. Partner institutions, such as non-governmental organisations, universities, and foreign governments, collaborated in the GAINS network to collect and analyse laboratory samples from wild birds, which were captured and released. This early warning system intended for health officials to track viral spread in the natural hosts of the disease. The USAID Bureau for Global Health, Office of Health, Infectious Disease and Nutrition (GH/HIDN) recently granted two cooperative agreements, PREDICT and RESPOND, under its Avian and Pandemic Influenza and Zoonotic Disease Program to continue and expand this work. The goal of PREDICT is to establish a global early warning system for zoonotic disease emergence that is capable of detecting, tracking, and predicting the emergence of new infectious diseases in high-risk wildlife (e.g. bats, rodents, and non-human primates) that could pose a major threat to human health. The goal of RESPOND is to improve the capacity of countries in high-risk areas to respond to outbreaks of emergent zoonotic diseases that pose a serious threat to human health. The intent is to respond to outbreaks while they are still within the animal community or to rapidly identify spillover to humans in the early stages of emergence. The geographic scope of this expanded effort is directed to those zoonotic “hotspots” of wildlife and domestic animal origins (JONES et al., 2008). Within PREDICT we have developed SMART (Strategic, Measurable, Adaptive, Responsive and Targeted) surveillance focusing on prevention of ‘spilling over’ from wildlife to humans or to halt these diseases rapidly after that spillover by understanding what factors induce emergence and rapidly identifying ways of prevention, control, and mitigation. We are establishing a global early warning system that is capable of detecting, tracking, and predicting the emergence of new infectious diseases in high-risk wildlife (e.g. bats, rodents, and non-human primates) that could pose a major threat to human health. The geographic scope of this expanded effort is directed to those zoonotic “hotspots” of wildlife origin. Our strategy targets important sentinel species at active human interfaces to improve surveillance

deficiencies at these hotspots. We perform collaborative assessments of local capacity, creating infectious disease modelling, introducing new technologies and cutting edge information management and communication tools with the potential to bring the world closer to an integrated, global approach to emerging zoonoses. This integration requires commitment from a broad coalition of partners and stakeholders including government agencies, universities and non-governmental organisations and will attempt to generate new international structures able to respond to these emerging zoonoses. Much more should be done to monitor diseases in wildlife and domestic animals. There is no one international governmental agency that conducts comprehensive ecological surveillance and monitoring of diseases in animals. Even worse, many wild animals are exported to countries that conduct little or no surveillance of the pathogens that they might harbour. An EcoHealth/ Conservation Medicine approach involving many parties including human and animal health professionals, ecologists, modellers and others would help provide comprehensive, coordinated, and cohesive strategies in addressing this immense threat. With 1.5 billion animals being imported into the United States each year, as well as an extensive international trade in illegal animal exports (SMITH et al., 2009) and some 75 per cent of emerging zoonoses worldwide having wildlife origins, Professor Aguirre stressed that EcoHealth has become a necessity, not an optional policy goal.

## Acknowledgements

I would like to thank EcoHealth Alliance for using some of the information presented herein. Furthermore I would like to acknowledge the generous support of the American people through the United States Agency for International Development (USAID) Emerging Pandemic Threats PREDICT. The contents are the responsibility of the author and do not necessarily reflect the views of USAID or the United States.

## References

*AGUIRRE AA, OSTFELD RS, DASZAK P (2012): New Directions in Conservation Medicine: Applied Cases of Ecological Health. Oxford University Press, New York, 672 pp.*

*AGUIRRE AA, OSTFELD RS, TABOR GM, HOUSE CA, PEARL MC (2002): Conservation Medicine: Ecological Health in Practice. Oxford University Press, New York, 407 pp.*

*JONES KE, PATEL N, LEVY M, STOREYGARD A, BALK D, GITTLEMAN JL, DASZAK P (2009): Global trends in emerging infectious diseases. Nature **451**, 990 - 994.*

*SMITH KF, SAX DF, LAFFERTY KD (2006): Evidence for the role of infectious disease in species extinction and endangerment. Conserv. Biol. **20**, 1349 - 1357.*

*SMITH KF, BEHRENS M, SCHLOEGEL LM, MARANO N, BURGIEL S, DASZAK P (2009): Reducing the risks of the wildlife trade. Science **324**, 594 - 595.*

# EMERGING DISEASES OF WILDLIFE IN AUSTRALIA: AN OVERVIEW OF SELECTED DISEASES

BOARDMAN W, MCALLISTER M, REICHEL M, HEMMATZEDAH F, WOOLFORD L

University of Adelaide, School of Animal and Veterinary Science, Roseworthy, SA 5371, AUSTRALIA; wayne.boardman@adelaide.edu.au

Recently in Australia we have seen the emergence of many new wildlife diseases and an expansion in the range of others. Australian bat lyssavirus and Hendra virus have recently been isolated from Grey headed flying foxes (*Pteropus poliocephalus*) in South Australia for the first time associated with the range expansion of this species from Victoria.

Koalas (*Phascolarctos cinereus*) were introduced into the Adelaide hills region of South Australia in the 1930's, but only recently have clinical cases of chlamydiosis emerged, associated with *Chlamydia pecorum*. Furthermore, sarcoptic mange (*Sarcoptes scabiei*), has also recently emerged in this population of koalas. The increased prevalence of these diseases may indicate a response to environmental stressors such as overcrowding and poor nutrition (FUNNELL et al., submitted). Little is known of the prevalence of Koala retrovirus (KoRV) in this population, however this has been found in populations where it was thought previously not to exist.

Mycobacteriosis associated with *Mycobacterium pinnipedia* has been diagnosed in an Australian fur seal (*Arctocephalus pusillus*) in South Australia for the first time, and few and sporadic cases have been detected across southern Australia previously; the impact of this disease on the population is not yet known but may indicate an unknown ongoing circulation of infection in the population of pinnipeds in southern Australia.

An as yet uncharacterised apicomplexan parasite, closely aligned to *Besnoitia* spp. has been seen in Western grey kangaroos (*Macropus fuliginosus*) and Red kangaroos (*Macropus rufus*) causing chronic and in some cases fatal epistaxis. Concern has been raised about the significance of this disease because of the similarity of this protozoan to *Besnoitia besnoti* an emerging disease of cattle in Europe.

A putative novel papillomavirus has been detected in associated with proliferative feet lesions in Regents parrots (*Polytelis anthopeplus*) in South Australia which may account for the recent decline of this species in the region, and a novel family of DNA viruses with characteristics of both papilloma- and polyomaviruses was found associated with debilitating neoplastic skin lesions in the endangered Western barred bandicoot (*Perameles bougainville*).

This presentation will give an overview of the pathology and significance of these emerging diseases.

## References

*FUNNELL O, JOHNSON L, WOOLFORD L, BOARDMAN W, POLKINGHORNE A, MCLELLAND D (submitted): Conjunctivitis associated with Chlamydia pecorum in three koalas (Phascolarctos cinereus) in the Mount Lofty Ranges, South Australia.*

# THE OLM (*PROTEUS ANGUINUS*) IN CROATIA – CONSERVATION RESEARCH PROJECT

LUKAC M[1], HORVATEK TOMIC D[1], CIZELJ I[2], JELIC D[3], PRUKNER RADOVCIC E[1]

[1]University of Zagreb, Faculty of Veterinary Medicine, Heinzelova 55, Zagreb 10000, CROATIA; maja.lukac@vef.hr
[2]Zagreb Zoo, Maksimirski perivoj b.b., Zagreb 10000, CROATIA
[3]Croatian Institute for Biodiversity, Croatian Herpetological Society, Prva breznicka 5 a, Zagreb 10000, CROATIA

## Summary

The olm (*Proteus anguinus*) is the only real cave-dwelling (stygobiont) chordate found in Europe. It is adapted to a life of complete darkness in its underground habitat in caves of the Dinaric karst of Central and Southeastern Europe. The olm is extremely vulnerable to changes in its environment and is now threatened by an increasing and uncontrolled spreading of urban areas and human-made infrastructure, and the excessive pollution of water habitats. Due to its life at difficult accessible locations its biology is not well understood and its physiological microflora and the pathogens that may jeopardise its existence are completely unknown. Here we present the project of the field investigation at several localities in Croatia, aimed to increase the knowledge about the olm's ecology and biology, including its microflora, in order to help protection and conservation of this endangered species.

## Introduction

The olm (*Proteus anguinus*) is an amphibian endemic to the subterranean waters of caves of the Dinaric karst inhabiting areas from northern Italy (Trieste), southern Slovenia and southwestern Croatia and Bosnia and Herzegovina (SKET, 1982). The olm is the only species in the *Proteus* genus and the only European species of the Proteidae family, as well as the only cave-dwelling (stygobiont) chordate in Europe. The olm is extremely vulnerable to changes in its environment because of its adaptation to the specific conditions in caves (ARNTZEN et al., 2009). In addition, waters in the karst are extremely sensitive to all kinds of pollution (BULOG et al., 2002). Some of the main reasons why the olm is endangered in its habitats are increasing and uncontrolled spreading of urban areas and human-made infrastructure, and the uncontrolled excessive pollution of water habitats, and many times the crevices and cave entrances are also used as landfills by the local communities. Also, heavy rains or waters from melted snow may wash the olm up from its subterranean habitat, bringing it to the surface of the ground. The animal is not able to survive here for a longer period of time because it is either illegally taken by local people as pet animal or dies after drainage/evaporation of the surface water. In Croatia, the olm is protected by the legislation designed to protect amphibians – collecting is possible only for this research project by the permission of the Croatian Ministry of Environmental and Nature Protection from Rupecica, Miljacka and Vedrine localities (MENP, 1999). The olm is also a species of European Community interest and a species in need of particularly strict protection and is included in Appendices II (as a priority species) and IV of the EU Habitats Directive (92/43/EEC). Despite of its popularity, a general knowledge of the olm's ecology and biology is limited. There is also a growing need for education of local communities in order to help the protection of this unique species. Further investigations are therefore required to increase the knowledge about this species to allow measures for its more efficient protection and conservation. This project is carried out by the

Croatian Herpetological Society and Croatian Institute for Biodiversity with the Hungarian Nature History Museum (Budapest), Zoological Society of London, Zagreb Zoo and Faculty of Veterinary Medicine, University of Zagreb as key partners.

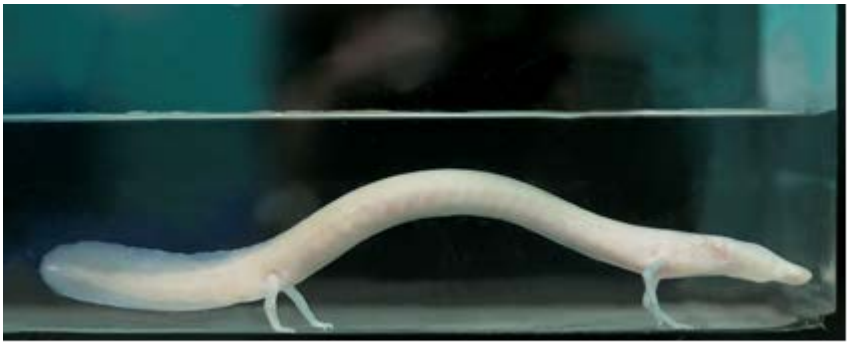

*Fig. 1: Proteus anguinus - The olm rescued from Vedrine locality and situated at Zagreb Zoo. (Photo: Neven Vrbanic)*

The aims of the project are to

- increase the awareness of local people and their efforts to reduce/stop the pollution and educate the public, particularly the young people, and get them involved in the maintaining and taking care of local caves as olm's natural habitats
- investigate the known localities and look for the new ones
- confirm the olm's presence in the inaccessible cave system with the environmental DNA technique
- establish a captive breeding and recovery centre for rescued olms from the localities where the water flushes away a large number of individuals each year
- investigate the potential to return the rescued individuals to their natural habitat
- identify all the microorganisms in olms to distinguish between normal, opportunistic and pathogenic flora both in animals from their natural habitat and those flushed out
- establish the optimal treatment and preventive measures against contagious pathogens, if required.

## Materials and methods

### Animals and husbandry

A special, well isolated room has been prepared for keeping the rescued olms. The room temperature is kept at 9°C, the same as water temperature. Each animal is placed individually in 50 litre glass aquarium. Aquariums are filled with water of 840 µS/cm conductivity. Water circulation is minimal and done only through the air stone. Each aquarium has at least two hiding places, made of transparent glass. Hiding places are different in height, so the animal has the opportunity to choose between 4 and 8 mm height. Glass hiding places enables easy and clear view on animal in every moment, without disturbing them. Room is kept totally dark, except for quick checking of animals on a daily basis.

### Microbiology

The following testing is underway:

1. Microbiological cultures of: (i) olms flushed out (dead or alive; skin, pharyngeal and cloacal swabs); (ii) olms from their natural habitat (skin, pharyngeal and cloacal swabs); (iii) water from the location where animals were found on the field; (iv) water from aquariums of rescued animals;

and (v) water from olm's natural habitat. Samples are incubated at 8 – 10°C and 22 – 24°C on the Neutral Agar (Difco Nutrient Agar, Becton, Dickinson and Company, Sparks, USA), Brilliant Green Agar (brilliant green agar -modified, Oxoid Ltd., Basingstoke, Hampshire, England) and Sabouraud dextrose agar (Oxoid GmbH, Wesel, Germany).

2. Antimicrobial susceptibility testing of identified bacteria
3. Bacteriological analysis by pyrosequencing (GS Junior 454 Sequencing System, Roche) of (i) water samples from the ground and aquariums and (ii) skin, pharyngeal and cloacal swabs
4. Parasitological analyses of faecal samples
5. RT-PCR testing for the presence of *Batrachochytrium dendrobatidis* in the skin swabs from the back, side, abdomen and groin (BOYLE et al., 2004) of: (i) olms flushed out (dead or alive), (ii) olms from their natural habitat, (iii) other amphibians from area around caves that are reasonably suspected to be asymptomatic carriers (*Bombina sp*.)
6. Viral testing, including Rana-virus detection by PCR (MARSCHANG et al., 1999) of: (i) olms flushed out (dead or alive; skin, pharyngeal and cloacal swabs); (ii) olms from their natural habitat (skin, pharyngeal and cloacal swabs); (iii) other amphibians from area around caves that are reasonably suspected to be asymptomatic carriers (skin, pharyngeal and cloacal swabs); (iv) water from the location where animals were found on the field; and (v) water from olm's natural habitat

*Fig. 2: Taking of samples for microbiological analysis by cloacal swabbing. (Photo: Neven Vrbanic)*

## Results and discussion

### Animals and husbandry

So far a total of four animals, two from Vedrine and two from Istria locality, were found flushed out on the field. The animals are doing well at the recovery centre provided in the Zagreb Zoo. They are fed on live earthworms, *Tubifex* sp., *Chironomus* sp. and *Gammarus* sp. on a 2-week basis and the food is readily accepted. Variety of live food is offered, because there is a great difference in prey selection between individuals. Therefore, some of them eat only earthworms while others prefer *Chironomus* sp. only. Because of the small number of animals, it is not possible to identify the association between eating preferences and different localities.

### Microbiology

Microbiological testing is carried out depending on the sample collection dynamics, as described above and the results will be published when completed. The veterinary part of the project is aimed to find out if it is possible to return the rescued olms to their natural habitat without harming the existing population. Therefore it is of great importance to identify all of the microorganisms that may harm both olms found in the field and those living in the caves, the latter ones expected to be healthy. It is also

important to distinguish between the infectious pathogens and the opportunistic ones that may appear depending on the temperature and other environmental factors. The olms found out of caves do not live at the preferred temperature at which they usually live. It is therefore important to identify micro-organisms that are opportunistic, for which the animal need not be treated and distinguish them from pathogenic ones. This may help to find out the best way for preventing potential infectious diseases in the population and to increase the general knowledge about microorganisms colonising and harming the olms since this data does not exist.

## Conclusion

The ongoing project is aimed to contribute to the knowledge about the health, biology and ecology of the olm, one of the most mysterious amphibian species in the world and to help building conservation capacities in Croatia and in the region.

## References


*ARNTZEN JW, DENOËL M, MIAUD C, ANDREONE F, VOGRIN M, EDGAR P, CRNOBRNJA ISAILOVIC J, AJTIC R, CORTI C (2009): Proteus anguinus. In: IUCN 2012. IUCN Red List of Threatened Species. Version 2012.2. www.iucnredlist.org. Retrieved 27th January 2013.*

*BOYLE DG, BOYLE DB, OLSEN V, MORGAN JAT, HYATT AD (2004): Rapid quantitative detection of chytridiomycosis (Batrachochytrium dendrobatidis) in amphibian samples using real-time Taqman PCR assay. Dis. Aquatic Org.* ***60****, 141 - 148.*

*BULOG B, MIHAJL K, JERAN Z, TOMAN MJ (2002): Trace element concentrations in the tissues of Proteus anguinus (Amphibia, Caudata) and the surrounding environment. Water Air Soil Pollut.* ***136****, 147 - 163.*

*EU Habitats Directive (1992): Council Directive 92/43/EEC of 21 May 1992 on the conservation of natural habitats and of wild fauna and flora.*

*MARSCHANG RE, BECHER P, POSTHAUS H, WILD P, THIEL H-J, MULLER-DOBLIES U, KALETA EF, BACCIARINI LN (1999): Isolation and characterization of an iridovirus from Herman's tortoises (Testudo hermanni). Arch. Virol.* ***144****, 1909 - 1922.*

*MENP - Croatian Ministry of Environmental and Nature Protection (1999): Ordinance on Protection of Amphibia (in Croatian). Official Gazette No. 80.*

*SKET B (1982): Distribution of Proteus (Amphibia: Urodela: Proteidae) and its possible explanation. J. Biogeogr.* ***24****, 263 - 280.*

# AVIAN BORNAVIRUS INFECTION IN FREE-RANGING WATERFOWL – PREVALENCE OF FAECAL SHEDDING AND SEROPREVALENCE IN ONTARIO, CANADA

DELNATTE P[1,2], ELIAS K[1], OJKIC D[3], NAGY E[1], CRAWSHAW G[2], SMITH DA[1]

[1]University of Guelph, Ontario Veterinary College, 50 Stone Road, Guelph, Ontario, N1G 2W1, CANADA; pdelnatt@uoguelph.ca
[2]Toronto Zoo, 361A Old Finch Avenue, Toronto, Ontario, M1B 5K7, CANADA
[3]University of Guelph, Animal Health Laboratory, Box 3612, Guelph, Ontario, N1H 6R8, CANADA

A new strain of avian bornavirus (ABV) has been recently identified as a cause of neurological disease and mortality in free-ranging Canada geese (*Branta canadensis*) and trumpeter swans (*Cygnus buccinator*) in Canada. This unique genotype has also been reported in apparently healthy ducks, geese and swans in the United States of America. Cloacal swabs and blood samples were collected from 206 free-ranging Canada geese, 135 trumpeter swans, 75 mute swans (*Cygnus olor*) and 208 mallard ducks (*Anas platyrhynchos*) between October 2010 and May 2012 in order to estimate the prevalence of ABV infection in Ontario. Swabs were evaluated for the presence of virus using ABV specific primers directed against the matrix gene (real time RT-PCR), and serum antibodies were measured using an enzyme-linked immunosorbent assay with nucleocapsid protein as antigen. At one site, 12.5 % of the geese caught shed ABV in faeces compared to none of the geese sampled at three other locations, although serum antibodies were present in birds at all four sites. The prevalences of shedding of ABV in mute swans, trumpeter swans and mallards were 9.3 %, 0 % and 0 %, respectively, despite the fact that these species share the same habitat. The reason for these differences among species and locations is unknown. Geese that were shedding the virus were more likely to have antibodies against ABV than those that were not. Evaluation of European waterfowl for the presence of ABV is underway.

# AVIAN MYCOBACTERIOSIS IN HUMBOLDT PENGUINS (*SPHENISCUS HUMBOLDTI*)

JURCZYNSKI K[1], WIDMER D[1], LANGER S[1], KEMPF H[2], BAUMGARTNER K[3], FLÜGGER M[4], PRAHL A[4]

[1]Zoo Duisburg, Mülheimer Straße 273, 47058 Duisburg, GERMANY; jurczynski@zoo-duisburg.de
[2]Tieraerztliche Klinik Gessertshausen, Grasweg 2, 86459 Gessertshausen, GERMANY
[3]Tiergarten Nürnberg, Am Tiergarten 30, 90480 Nürnberg, GERMANY
[4]Tierpark Hagenbeck, Lokstedter Granzstraße 2, 22527 Hamburg, GERMANY

Avian mycobacteriosis has been reported in several domestic and exotic birds worldwide. Some species seem to be more susceptible than others. Waterfowl, which is normally more resistant, may be infected in large numbers under captive conditions (RIGGS, 2011). In penguins, mycobacteriosis has been rarely diagnosed (NAPIER et al., 2009). Among the more common diseases in penguins are avian malaria, aspergillosis, bumble foot or foreign body ingestion. In 2011, a German Zoo received five male Humboldt penguins (*Spheniscus humboldti*) from a smaller collection. Two animals died resp. were euthanised due to poor condition in quarantine and *post-mortem* examination revealed avian mycobacteriosis caused by *Mycobacterium avium* subspecies *avium*. The health status of the remaining three animals as well as the original breeding group was assessed. All of the animals were anaesthetised, blood samples were taken, X-rays, CT-scans and MRIs were performed to help detect mycobacterial infection and granuloma formation. Suspect animals were humanely euthanised and *post-mortem* examinations were performed within 24 hours. In all euthanised animals pathological lesions were detected, samples were submitted to the Friedrich-Loeffler Institute and infection was confirmed in all of the animals. The presentation will give an overview over the pros and cons of the chosen examinations and will present the clinical signs and pathological findings of this disease in Humboldt penguins. *Ante mortem* diagnostics showed major limitations. Blood serology was negative in all cases and X-rays were often inconclusive. Computed tomography showed the most promising results. Elevated densities of lung tissue were confirmed as granulomas at necropsy.

## References

*NAPIER JE, HINRICHS SH, LAMPEN F, IWEN PC, WICKERT RS, GARRETT JL, ADEN TA, RESTIS E, CURRO TG, SIMMONS LG, ARMSTRONG DL (2009): An outbreak of avian mycobacteriosis caused by Mycobacterium intracellulare in little blue penguins (Eudyptula minor). J. Zoo. Wildl. Med.* ***40****, 680 - 686.*

*RIGGS G (2011): Avian Mycobacterial Disease. In: Fowler ME, Miller RE (Eds.). Zoo and Wild Animal Medicine. Current Therapy 7, W.B. Philadelphia: Saunders Company, 266 - 274.*

# EQUINE HERPES EYE VIEW OF ZOOS

GREENWOOD AD[1], TSANGARAS K[1], SZENTIKS CA[1], WOHLSEIN P[2], LAWRENZ A[3], EAST ML[1], HOFER H[1], OSTERRIEDER N[4]

[1]Leibniz Institute for Zoo and Wildlife Research (IZW), Dept. of Wildlife Diseases, Alfred-Kowalke-Str. 17, 10315 Berlin, GERMANY; greenwood@izw-berlin.de
[2]Stiftung Tierärztliche Hochschule Hannover, Institut für Pathologie, Bünteweg 17, 30559 Hannover, GERMANY
[3]Zoological Garden Wuppertal, Hubertusallee 30, 42117 Wuppertal-Sonnborn, GERMANY
[4]Freie Universität Berlin, Institut für Virologie, Philippstr. 13, Haus 18, 10115 Berlin, GERMANY

Pathogens of wildlife typically exhibit a degree of host specificity and mostly do not endanger the survival of reservoir host populations. This implies that the geographical range of most wildlife pathogens should largely match that of their main host species. Climate change, global trade and inadvertent translocation of infected host species can disrupt a pathogen's geographic range and allow it to spread and colonise new hosts. This also applies to environmentally unstable pathogens or those that cannot be disseminated widely. Zoos can be an extreme model of unusual virus transmission as they bring together non-sympatric animals in a restricted space. Thus, many pathogens gain opportunities to jump into new species that they would never encounter in a natural setting. As a consequence it is exceedingly difficult to predict what host-species jumps may occur and to monitor jumps when they occur.

In this context, cases of encephalitis in polar bears (*Ursus maritimus*) and other captive wildlife are illustrative of the consequences of pathogen jumps to new species and the methodological pipeline, and challenges required to identify and monitor such jumps. For example, the polar bear Jerka from the Wuppertal Zoological Garden died of encephalitis caused by infection by a zebra variant of equine herpes virus. Exposure much less infection or death could not have been encountered by polar bears in the wild.

A complex 3-step and species-neutral pipeline was developed and employed to analyse the cause of death of Jerka and other bears. Step 1 of the pipeline comprised necroscopy, bacteriological analysis and histology. Step 2 comprised immunohistochemistry and molecular techniques which included established techniques such as (A) a PCR with primers of broad specificity to directly detect pathogens, (B) two DNA-based oligonucleotide microarray methods for virus detection, and (C) two next-generation sequencing approaches. Step 3 comprised a variety of serological approaches. The pipeline represents all the most current traditional and next generation high-throughput approaches that were attempted both systematically and comparatively on the samples.

From the pathogen's point of view, Jerka was a new opportunity for viral replication that would not have been afforded if she had not been in captivity in the same zoo as zebras. Herpes viruses as a group are not known for interspecies transfer, though there are some clear exceptions. Yet herpes viruses formerly thought to have a limited range of closely related host species are circulating among diverse taxa in zoos and until now, largely undetected or undiagnosed. Many other known and unknown pathogens with less clearly defined hosts are likely in circulation among captive populations. Infection may not require direct contact and may be transmitted through water sources or by rodent or insect vectors. Thus, there are a variety of animal management concerns raised by this and other studies but with further research, effective strategies can be developed to eliminate or minimise cross species pathogen transfer in zoos.

# FELINE SARCOIDS - „CROSS-SPECIES“ INFECTION WITH BOVINE PAPILLOMAVIRUS?

FÖRSTER C[1], HENSEL C[2], KÖNIG M[1]

[1]Justus-Liebig-University, Faculty of Veterinary Medicine, Institute of Virology, Schubertstr. 81, 35392 Giessen, GERMANY; Christine.foerster@vetmed.uni-giessen.de
[2]Serengetipark Hodenhagen, Am Safaripark 1, 29693 Hodenhagen, GERMANY

Papillomaviruses generally infect only a single host species and multiplication is often restricted to specific cell types of this host. The only known exception is bovine papillomavirus, which can be detected in conjunction with equine sarcoids. Recently a papillomavirus in cutaneous lesions of cats was found (feline sarcoid-associated papillomavirus, FeSarPV). Interestingly a resembling FeSarPV virus was detected in bovine samples, which led to speculation on an aetiological association similar to the equine sarcoid. Sarcoids in association with papillomavirus were also described in tapirs and African lions. In Germany there is not much information available about occurrence of papillomavirus-associated skin lesions in felids.

Skin biopsies of three lions from the Serengetipark Hodenhagen were sent to our institute in 2010. About ten lions showed sarcoid-like tumours in head- and tail-areas. The lions were fed with beef. Our objective was to detect a broad spectrum of possible causative agents. Methods of choice were negative staining electron microscopy in combination with PAN-Papillomavirus-PCR. Besides that material of the biopsies was shredded, inactivated and homologous vaccine prepared for ten animals with the help of adjuvants. Immunisation was done twice with four-week interval.

While papillomavirus can be easily detected in wart samples by electron microscopy this method is not suitable in regard to sarcoids. Presumably there is no complete virus-replication cycle. Samples of all three animals revealed negative results by electron microscopy and were positive by the PAN-Papillomavirus-PCR. The findings corresponded to results of the histo-pathological examination. Amplification products of PAN-Papillomavirus and a FeSarPV-speccific-PCR were cloned and sequenced. Phylogenetic analysis showed a close relationship between the sequence obtained from the lion biopsies and bovine Papillomavirus.

After booster-immunisation of lions most of the sarcoids showed clear regression within the next six months.

In conclusion genus-overlapping PAN-Papillomavirus-PCR was suitable to detect sarcoid-associated papillomavirus. An immunisation trial with a homologous vaccine seemed to be successful. Further studies on papillomaviruses in Felidae should be done to understand epidemiology, disease, occurrence, recurrence and therapy-possibilities.

# TESTS AND TESTING: SAMPLING AND STORAGE DECISIONS TO MAXIMISE PATHOGEN DETECTION USING MODERN TECHNOLOGIES

BOURNE DC[1], UHLHORN H[2]

[1]Twycross Zoo – East Midland Zoological Society, Wildlife Information Network, Burton Road, Atherstone, Warwickshire CV9 3PX, UK; dbourne@wildlifeinformation.org
[2]National Veterinary Institute (SVA), Dept. Pathology and Wildlife Diseases, Travvägen 20, 75189 Uppsala, SWEDEN

## Summary

New technologies have been and are being developed for the detection of a wide variety of pathogens. Technologies such as PCR are extremely sensitive and allow the detection of very small quantities of pathogen while new technologies such as microarrays hold the potential for testing small samples for many different pathogens at one time. However, correct choice of sample still affects whether or not pathogens will be detected. No single tissue is ideal for the detection of all potential pathogens while use of tissue pools may reduce the pathogen concentration to below the detection limit even with extremely sensitive tests. Additionally, the choice of storage conditions/preservation method affects which tests can be carried out. For serological tests also, wildlife samples pose particular challenges. Inadequate labelling and accompanying information can greatly reduce the usefulness of otherwise valuable samples.

## Introduction

New technologies have been and are being developed for the detection of a wide variety of pathogens. Compared with cytological and histological staining, plates and cell cultures for the detection of bacterial, fungal and viral pathogens (WOODS and WALKER, 1996; STORCH, 2007), technologies such as PCR are extremely sensitive and allow the detection of very small quantities of pathogen (WILLOUGHBY, 2003). New technologies such as microarrays hold the potential for testing small samples for many different pathogens at one time (DONG et al., 2008; GILBERT, 2002).
A major focus of the EU-funded WildTech project has been the development of microarrays for testing samples from wildlife (particularly wild boar, cervids, lagomorphs, rodents and foxes) for large numbers of pathogens, including known pathogens and potentially novel pathogens. This has involved both collection of samples specifically for the project, and use of available samples stored in biobanks. In many cases, samples have been tested without prior knowledge or suspicion of which pathogens might be present. At the same time, multiplex miniaturised ELISAs have been developed for testing serum samples (again, both archived and newly collected) for antibodies to many different pathogens.
New technologies are extremely sensitive and detect very small quantities of pathogens, but the question remains: which tissue(s) should be collected and tested? Will the storage methods which have been used for historical samples allow the tests to be carried out, or will they interfere with the new technologies? As part of the project, information has been collated on a number of pathogens and entered into the Wildpro® electronic encyclopaedia. In compiling information on pathogen detection and identification, it became clear that data on which tissues should best be tested is not always easy to find, and tends to be passed from one researcher to the next (James Mills, pers. comm.), but often is not included in published papers, many of which simply refer to testing “tissues”. However, results of testing may vary considerably depending on **which** tissue is tested.

## Review / discussion

No single tissue is ideal for the detection of all potential pathogens (COMPTON and RILEY, 2001), not even the spleen, which contains large quantities of blood, is often targeted by viruses with lymphoid tropism, and contains phagocytic cells which may contain intracellular bacteria. Tissue pools may be used to improve the chances that one of the tissues is appropriate for the pathogen, however if the pathogen is present in appreciable quantities in only one of several tissues in the pool, then the quantity of pathogen present in the tested pool may be below the detection limit even with extremely sensitive tests such as PCR and micro-arrays.

Sometimes the localisation of the correct tissue to be tested is very precise, e.g. the brainstem for *Listeria monocytogenes* (rostral cerebrum may give a false-negative result) or the dorsal portion of the medulla oblongata at the obex for cervids in the early stages of chronic wasting disease (CWD) (WILLIAMS et al., 2002). Additionally, some pathogens may be sequestered within lesions (e.g. *Mycobacterium bovis*) and sampling of normal tissue from outside the lesion, even within the correct organ, will fail to detect the pathogen. For some pathogens, the appropriate choice of tissues varies with the host species: for example in hares (*Lepus* spp.), many pathogens result in a septicaemic infection (Dolores Gavier-Widén, pers. comm.) and the pathogen may be found in many organs. In contrast, in birds, *Salmonella* spp. may be found only in the gut, and possibly only in the caecae (SNOEYENBOS, 1994). Table 1 indicates preferred tissues for testing for selected pathogens.

Additionally, the choice of preservation method (refrigerated, frozen, preserved in formaldehyde etc.) will affect which tests can be carried out, and storage conditions may affect different pathogens differently, for example storage at -70 ˚C is recommended for preservation of most samples prior to virus isolation, but some viruses are highly sensitive to freezing (WOODS and WALKER, 1996; STORCH, 2007). Field conditions (e.g. lack of refrigeration) or cost considerations (e.g. expense of RNAlater) do not always permit the most advantageous methods of preservation.

Correct selection of materials for examination, correct sampling methods and appropriate storage and shipping of such materials has the potential to greatly improve the results obtained (DORRESTEIN and VAN DER HAGE, 2010; STORCH, 2007).

Testing of only a single tissue is inevitably going to lead to many pathogens not being detected. Testing of a pool of several tissues leads to decisions regarding: which tissues to include in the pool, what quantity of each tissue, and whether the small quantity chosen is representative of the organ/most likely to contain the pathogen (Dolores Gavier-Widén, pers. comm.).

Potentially, pools of tissues could be chosen on the basis of clinical signs, pathological findings or the agents you most wish to find, depending on the target organs of the pathogen:

- **Septicaemia:** spleen, blood, liver and bone marrow;
- **Gastroinintestinal infection:** piece of intestine, mesenteric lymph node, faecal sample);
- **Upper respiratory tract:** nasal and tracheal swabs, tonsils, retropharyngeal lymph node;
- **Lower respiratory:** lung, mediastinal lymph node
- **Hepatic:** liver, gall bladder;
- **Encephalitis:** brain, cerebrospinal fluid;
- **Urinary:** kidney, urinary bladder, urine;
- **Reproductive/abortigenic:** testis & accessory glands (male); vaginal swabs, uterus (female); and (for abortigenic) placenta, foetus/foetal tissues, vaginal swab.

Ideally, all tissues and lesions would be sampled at necropsy, but this does not always occur (DORRESTEIN and VAN DER HAGE, 2010). When faced with historical samples, both the choice of tissues and the choice of preservation method (e.g. freezing versus formaldehyde or even paraffin blocks) have been made previously. Spleen, liver, lung, faeces and possibly kidney are more likely to have been sampled and stored, while bone marrow, muscle, lymph nodes, reproductive organs, aborted

foetuses and brain samples are much less common in pathological tissue banks (Dolores Gavier-Widén, pers. comm.).
Serological testing also presents particular challenges when working with non-domestic species: often, rather than fresh blood samples from live animals, blood samples or tissue fluids must be obtained from dead animals (found dead, hunted, killed as pests) and blood may be autolysed; some assays require species-specific reagents or test components, and even when these are not needed (e.g. competitive ELISA), validation of the test in different species is still important (AFSHAR, 1994; GARDNER et al., 1996).
Finally, the usefulness of samples can be limited by inadequate identification or accompanying information. Unlabelled samples are all but useless. Many sets of data are reduced in usefulness for epidemiological studies because samples are not accompanies by all the appropriate data including species, age, sex, date and geolocation of collection. It is important that individual samples are properly labelled and that appropriate information accompanies each sample (FRANSON, 1999; OIE, 2009).

## Conclusion

It is important to remember that, whatever the test used, and however sensitive it might be, "*relevant results are ultimately reliant on the submission of quality specimens*" (TANG et al., 1997).

## Acknowledgements

The WildTech project is supported by the European Commission under the Food, Agriculture and Fisheries, and Biotechnology Theme of the 7th Framework Programme for Research and Technological Development, grant agreement no. 222633.
Many thanks to Dolores Gavier-Widén for her comments on drafts of this paper.

## References

*AFSHAR A (1994): Bluetongue: laboratory diagnosis. Comp. Imm. Microb. Inf. Dis.* ***17****, 221 - 242.*

*COMPTON SR, RILEY LK (2001): Detection of infectious agents in laboratory rodents: traditional and molecular techniques. Comp. Med.* ***51****, 113 - 119.*

*DORRESTEIN GM, VAN DER HAGE MM (2010): VII. POST-MORTEM PROCEDURES. In: Kaandorp J (Ed.): Transmissible Diseases Handbook 4th Edition. European Association of Zoo and Wildlife Veterinarians.*

*FRANSON JC (1999): Specimen Collection and Preservation. Chapter 2. In: Friend M, Franson JC: Field Manual of Wildlife Diseases. General Field Procedures and Diseases of Birds. Washington, DC: US Department of the Interior, US Geological Survey, 7 - 12.*

*GARDNER IA, HIETALA S, BOYCE WM (1996): Validity of using serological tests for diagnosis of diseases in wild animals. Revue Sci. Tech.* ***15****, 323 - 335.*

*GILBERT GL (2002): Molecular diagnostics in infectious diseases and public health microbiology: cottage industry to postgenomics. TRENDS Molec. Med.* ***8****, 280 - 287.*

*SNOEYENBOS, GH (1994) Avian Salmonellosis. In: Beran GW (Ed.): Handbook of Zoonoses Second Edition Section A: Bacterial, Rickettsial, Chlamydial, and Mycotic. Boca Raton: CRC Press, 303 - 310.*

*STORCH GA (2007): Diagnostic Virology. In: Knipe DM, Howley PM (Eds.): Philadelphia: Wolters Kluwer/Lippincott Williams & Wilkins, 565 - 604.*

*TANG Y-W, PROCOP GW, PERSING DH (1997): Molecular diagnostics of infectious diseases. Clin. Chem.* ***43****, 2021 - 2038.*

*WILLIAMS ES, MILLER MW, KREEGER TJ, KAHN RH, THORNE ET (2002): Chronic wasting disease in deer and elk: a review with recommendations for management. J. Wildl. Man.* ***66****, 551 - 563.*

*WILLOUGHBY K (2003): The ABC of PCR. Pract.* ***25****, 140 - 145.*

*WOODS GL, WALKER DH (1996): Detection of infection or infectious agents by use of cytological and histological stains. Clin. Microb. Rev.* ***9****, 382 - 404.*

*Tab. 1: Tissues recommended for testing for some example pathogens.*

| **Pathogen** | **Tissues** |
|---|---|
| African swine fever virus | Blood in anticoagulant, spleen, lymph nodes, tonsil, liver. (OURA et al., 2013). If post mortem changes are advanced, bone marrow should be submitted. In addition to these tissues shipped refrigerated or frozen, pieces of the same tissues, any lesions and the brain should be placed in 10 % formalin (USAHA, 1998). |
| *Anaplasma phagocytophila* | Blood from peripheral vessels (light microscopy of stained blood films is generally used for diagnosis), and smears from internal organs (liver, kidney, heart and lungs) (DAVIDSON and GOFF, 2001; OIE, 2009; BRANDT, 2010). |
| Avian influenza virus (HPAI) | **Birds:** Intestinal contents (faeces) or cloacal swabs and oropharyngeal swabs. Samples from the trachea, lungs, air sacs, intestine, spleen, kidney, brain, liver and heart (OIE, 2009; PANTIN-JACKWOOD et al., 2009).<br>**Mammals:** HPAI (H5N1) has variously been detected in the lungs, liver, brain, heart, kidneys, spleen, duodenum, adrenal cortex and pancreas. It has been detected in the lungs in most species (REPERANT et al., 2009). |
| *Bacillus anthacis* | Blood (sample from e.g. ear). Tissues from the extremities (sections of ear, tail) as these are the furthest from the intestines (source of other organisms which may overgrow *B. anthracis*); extracellular fluid from subcutaneous swellings (CHOQUETTE and BROUGHTON, 1981; OIE, 2009) |
| Bluetongue virus | Blood (collected into anticoagulant such as EDTA), spleen, lymph nodes. Maintain at 4°C in transport (OIE, 2009).<br>**Note:** freeze-thaw reduces virus infectivity by about 10 times, and lyses red blood cells; virus in the rbc may then be neutralised by humeral antibodies (MERTENS et al., 2009). |
| *Brucella abortus* | Spleen, lymph nodes (particularly those draining the head, genital areas and mammary glands). Also the lungs, spleen, liver, kidney, ileum, rectum, uterus, cervix, vagina, mammary gland, testis, epididymis, seminal vesicle, ampulla, prostate, bone marrow, muscle, urine, faeces, CSF, synovial fluid. In association with abortion: aborted foetuses (stomach contents, spleen and lung), foetal membranes, vaginal secretions (swabs), milk. Also semen, arthritic fluids, hygroma fluids (OIE, 2009; HUNTER and KREEGER, 1999). |

*Continuation tab. 1*

| | |
|---|---|
| *Campylobacter jejuni* | Faeces, rectal swabs, caecal contents. Inflamed mesenteric lymph nodes. In acute disease, blood. With abortion, plascenta, foetal tissues (particularly stomach contents, liver), vaginal fluid. In rodents, intestinal contents (OIE 2009, ROSEF et al., 1983; SKIRROW, 1994; MÖRNER, 2001) |
| Classical swine fever virus | The palatine tonsils; submandibular, gastro-hepatic and mesenteric lymph nodes, spleen, kidneys and lower ileum, also thymus, caecal tonsil and brain. Blood can also be used for PCR (OIE, 2009; KIUPEL, 2010; VAN CAMPER et al., 2001) |
| *Coxiella burnetii* | Milk, blood. Spleen (rodents), placenta, colostrum, faeces (ruminants) and aborted foetus liver, lung stomach contents. Blood: separate the clot from the serum and freeze separately – serum for antibodies, clot for organism detection (MAURIN and RAOULT, 1999; OIE, 2009). |
| *Echinococcus multilocularis* | Intermediate hosts (rodents): cysts in abdominal, thoracic or pelvic organs; particularly the liver. Definitive hosts (foxes): small intestines (faeces of live animals). (LEIBY and DYER, 1971; JONES and PYBUS, 2001; OIE, 2009) |
| Encephalomyocarditis virus | In pigs, heart muscle (VANDERHALLEN and KOENEN, 1998). In rodents, particularly the pancreas, also the heart, spleen, lung, liver, and thymus (DOI et al., 1995). |
| *Escherichia coli* | Faeces, intestinal contents, recto-anal mucosal swabs. Section of ileum. In septicaemic disease, visceral organs (e.g. liver, spleen, kidney, lymph nodes), heart blood (OIE, 2009, TIMONEY et al., 1988; RADOSTITS et al., 1994) |
| *Francisella tularensis* | Liver, spleen, bone marrow, kidney, lung, lymph nodes. (BELL and REILLY 1981; OIE, 2009) |
| Hantavirus | Lung, kidney, liver and spleen (JOHNSON, 2001; MILLS and CHILDS, 2001) |
| Hepatitis E virus | Liver, bile, small intestines, colon, mesenteric lymph nodes, skeletal muscle. Pig faeces (WILLIAMS et al., 2001; ROBERTSON, 2006; MENG, 2010). |
| *Leptospira* spp. | Liver, spleen, brain, lung, kidney; blood, milk, cerebro-spinal fluid, peritoneal fluid. In chronic infections (carrier state), kidney, urine, genital tract (SHOTTS, 1984; LEIGHTON and KUIKEN, 2001; OIE, 2009). |
| *Listeria monocytogenes* | Liver, spleen, kidneys, lungs, heart. In association with abortion: placenta, uterine discharges, foetal abomasal contents. In encephalitic infection: pons, medulla, CSF. For carrier detection: liver, intestinal contents and faeces. Note: maceration of tissues may be required to release organisms from tissue foci for culture. Samples should be maintained at 4 ˚C and if they have been frozen, should be kept frozen until analysed (DIJKSTRA, 1984; OIE, 2009). |
| Lymphocytic choriomeningitis virus | Liver, spleen, kidney, blood (WINKLER and LEWIS, 1981). Kidney is preferred for PCR (COMPTON and RILEY, 2001). |
| *Mycobacterium avium paratuberculosis* | Terminal ileum, associated lymph nodes, faeces, smear from terminal rectum (THOEN and JOHNSON, 1981; JESSUP and WILLIAMS 1999; MANNING and COLLINS, 1999; OIE, 2009). |

*Continuation tab. 1*

| | |
|---|---|
| *Mycobacterium bovis* | In wild mammals: Lymph nodes (mediastinal, mesenteric and tracheobronchial), lung and spleen, plus any lesions of the lungs, heart, kidneys, liver, spleen or of any lymph nodes (DELAHAY et al., 2008). |
| *Neospora caninum* | Particularly the brain. In rodents, also skeletal muscle, kidney. In dogs, also heart and skeletal muscle (and other organs). In association with bovine abortion: placenta, also foetal brain, heart and liver (DUBEY et al., 1998; FERROGLIO et al., 2007). |
| *Pasteurella multocida* | **Mammals:** Lung, blood, spleen, liver, abscesses (BUXTON and FRASER, 1977; TIMONEY et al., 1988; MILLER, 2001). In lagomorphs, particularly lungs and swabs from nasal chambers (LU et al., 1983).<br>**Fowl cholera:** lung, liver, spleen, heart blood, gonads, bone marrow. In decomposed carcasses, bone marrow (OIE, 2009) |
| Poxvirus | Skin lesions, crusts from lesions, skin biopsies. In birds with lesions of the mucous membranes, these lesions should be sampled. When generalised disease is present, lung, lymph nodes and (if CNS disease is suspected) brain (OIE, 2009; LIERZ, 2010). |
| Rabies | Brain: the whole brain in small animals; for large animals a cross section of the brain stem plus cerebellum and hippocampus. The thalamus should be included in the brain sample. In BATS in particular, the salivary glands should be sampled also (BERAN, 1994; OIE, 2009). |
| Salmonella spp. (*Salmonella enteritidis, Salmonella typhimurium*) | **Mammals:** Faeces, rectal swabs. Most of the viscera, particularly spleen, liver, kidney and lung and abdominal lymph nodes. If associated with abortion, foetal stomach contents, placenta and vaginal swabs. For rodents with chronic infection, faeces, intestinal contents (BUXTON and FRASER, 1977; WRAY, 1994; MACKINTOSH et al., 2002).<br>**Birds:** gut, particularly caecum (SNOEYENBOS, 1994). |
| Tick borne encephalitis | Brain, liver, spleen, lymph nodes and skin at the site of feeding ticks (LABUDA et al., 1996, 1997; GOLOVLJOVA et al., 2004; BAKHVALOVA et al., 2006) |
| *Toxoplasma gondii* | Brain, heart, skeletal muscle, mesenteric lymph nodes, liver, lung, ascitic fluid, other organs; placenta in the case of abortions (RADOSTITS et al., 1994; DUBEY, 1998; OIE, 2009). |
| *Trichinella spiralis* | Muscles. The site of predilection varies with species, but in most species, samples of muscle from the diaphragm pillars and the tongue will be appropriate; these and the masseter muscles may be most appropriate in herbivores and pigs, while forearm muscles may be more usefully sampled in carnivores. For rodents, the whole of the skeletal muscle may be sampled (carcass with skin and internal organs removed (DICK and POZIO, 2001; GAMBLE et al., 2000; KAPEL et al., 1995, 2005). |
| WNV | In birds, kidney, brain, heart, liver and intestine (also feather pulp from wing/tail feathers during moult). In horses, brain tissue, including brainstem, and spinal cord tissue. In other mammals, particularly the kidney and brain, but also other tissues (CDC, 2001; DOCHERTY et al., 2004; OIE, 2009). |

## Table references


*BAKHVALOVA VN, DOBROTVORSKY AK, PANOV VV, MATVEEVA VA, TKACHEV SE, MOROZOVA OV (2006): Natural tick-borne encephalitis virus infection among wild small mammals in the southeastern part of western Siberia, Russia. Vector Borne Zoonotic Dis.* ***6****, 32 - 41.*

*BELL JF, REILLY JR (1981): Tularemia. In: Davis JW, Karstad LH, Trainer DO (Eds.): Infectious Diseases of Wild Mammals Second Edition. Ames: Iowa State University Press, 213 - 231.*

*BERAN GW (1994): Rabies and Infections by Rabies-Related Viruses. In: Beran GW (Ed.): Handbook of Zoonoses Second Edition Section B: Viral. Boca Raton: CRC Press Inc., 307 - 357.*

*BRAND T (2010): Bovine Anaplasmosis Factsheet 69. In: Kaandorp J (Ed.): Transmissible Diseases Handbook 4th Edition. European Association of Zoo and Wildlife Veterinarians.*

*BUXTON A, FRASER G (1977): Animal Microbiology Volume 1. Oxford: Blackwell Scientific Publications.*

*CDC (2001): Epidemic/Epizootic West Nile Virus in the United States: Guidelines for Surveillance, Prevention, and Control Third Revision. Fort Collins: Centers for Disease Control (CDC).*

*CHOQUETTE LPE, BROUGHTON E (1981): Anthrax. In: Davis JW, Karstad LH, Trainer D. (Eds.): Infectious Diseases of Wild Mammals Second Edition. Ames: Iowa State University Press, 288 - 296.*

*COMPTON SR, RILEY LK (2001): Detection of infectious agents in laboratory rodents: traditional and molecular techniques. Comp. Med.* ***51****, 113 - 119.*

*DAVIDSON WR, GOFF WL (2001): Order Rickettsiales: Anaplasmosis. In: Williams ES, Barker IK (Eds.): Infectious Diseases of Wild Mammals Third Edition. Ames: Iowa State University Press, 455 - 466.*

*DELAHAY RJ, SMITH GC, BARLOW AM, WALKER N, HARRIS A, CLIFTON-HADLEY RS, CHEESEMAN CL (2007): Bovine tuberculosis infection in wild mammals in the South-West region of England: a survey of prevalence and a semi-quantitative assessment of the relative risks to cattle. Vet J.* ***173****, 287 - 301.*

*DICK TA, POZIO E (2001): Trichinella spp. and Trichinellosis. In: Samuel WM, Kocan AA, Pybus MJ (Eds.): Parasitic Diseases of Wild Mammals Second Edition. Ames: Iowa State University Press, 380 - 396.*

*DIJKSTRA RG (1984): Listeriosis. In: Davis JW, Karstad LH, Trainer DO (Eds.): Infectious Diseases of Wild Mammals Second Edition. Ames: Iowa State University Press, 306 - 316.*

*DOCHERTY DE, LONG RR, GRIFFIN KM, SAITO EK (2004): Corvidae feather pulp and West Nile virus detection. Emerg. Inf. Dis.* ***10****, 907 - 909.*

*DOI K, IKEGAMI H, ISHII K, DOI C, YAMANOUCHI Y, SUGANO S (1995): Encephalomyocarditis (EMC) virus infection in the common vole, Microtis arvalis. Lab. An.* ***29****, 180 - 184.*

*DUBEY J.P. (1998): Toxoplasmosis, Sarcocystosis, Isosporosis, and Cyclosporosis. In: Palmer SR, Lord Soulsby. Simpson DIH (Eds.): Zoonoses. London: WB Saunders, 577 - 597*

*DUBEY JP, DOROUGH KR, JENKINS MC, LIDDELL S, SPEER CA, KWOK OC, SHEN SK (1998): Canine neosporosis: clinical signs, diagnosis, treatment and isolation of Neospora caninum in mice and cell culture. Int. J. Parasitol.* ***28****, 1293 - 1304.*

*FERROGLIO E, PASINO M, ROMANO A, GRANDE D, PREGEL P, TRISCIUOGLIO A (2007): Evidence of Neospora caninum DNA in wild rodents. Vet. Parasitol.* ***148****, 346 - 9.*

*GAMBLE HR, BESSONOV AS, CUPERLOVIC K, GAJADHAR AA, VAN KNAPEN F, NOECKLER K, SCHENONE H, ZHU X (2000): International Commission on Trichinellosis: recommendations on methods for the control of Trichinella in domestic and wild animals intended for human consumption. Vet. Parasitol.* ***93****, 393 - 408.*

*GOLOVLJOVA I, VENE S, SJÖLANDER KB, VASILENKO V, PLYUSNIN A, LUNDKVIST A (2004): Characterization of tick-borne encephalitis virus from Estonia. J. Med. Virol.* ***74****, 580 - 588.*

*HUNTER DL, KREEGER TJ (1999): Brucellosis caused by Brucella abortus in Free-Ranging North American Artiodactylids. In: Fowler ME, Miller RE (Eds.): Zoo and Wild Animal Medicine: Current Therapy 4. Philadelphia: WB Saunders Co., 621 - 626.*

*JESSUP DA, WILLIAMS ES (1999): Paratuberculosis in Free-Ranging Wildlife in North America. In: Fowler ME, Miller RE (Eds.): Zoo and Wild Animal Medicine: Current Therapy 4. Philadelphia: WB Saunders Co., 616 - 620.*

*JOHNSON KM (2001): Hantaviruses: history and overview. Curr. Top. Microbiol. Immunol.* ***256****, 1 - 14.*

*JONES A, PYBUS, MJ (2001): Taeniasis and Echinococcosis. In: Samuel WM, Kocan AA, Pybus MJ (Eds.): Parasitic Diseases of Wild Mammals Second Edition. Ames: Iowa State University Press, 150 - 192.*

*KAPEL CMO, HENRIKSEN SA, BERG TB, NANSEN P (1995): Trichinella infections in arctic foxes from Greenland: studies and reflections on predilection sites of muscle larvae. J. Helminthol.* ***69****, 325 - 330.*

*KAPEL CM, WEBSTER P, GAMBLE HR (2005): Muscle distribution of sylvatic and domestic Trichinella larvae in production animals and wildlife. Vet. Parasitol.* ***132****, 101 - 105.*

*KIUPEL M (2010): Classical Swine Fever. Factsheet 13, In Kaandorp J (Ed). Transmissible Diseases Handbook 4th Edition, European Association of Zoo and Wildlife Veterinarians.*

*LABUDA M, KOZUCH O, ZUFFOVÁ E, ELECKOVÁ E, HAILS RS, NUTTALL PA (1997): Tick-borne encephalitis virus transmission between ticks cofeeding on specific immune natural rodent hosts. Virol.* ***235****, 138 - 143.*

*LABUDA M, AUSTYN JM, ZUFFOVA E, KOZUCH O, FUCHSBERGER N, LYSY J, NUTTALL PA (1996): Importance of localized skin infection in tick-borne encephalitis virus transmission. Virol.* ***219****, 357 - 366.*

*LEIBY PD, DYER WG (1971): Cyclophyllidean tapeworms of wild carnivores. In: Davis JW, Anderson RC (Eds.): Parasitic Diseases of Wild Mammals. Ames: Iowa State University Press, 174 - 234.*

*LEIGHTON FA, KUIKEN T (2001): Leptospirosis. In: Williams ES, Barker IK (Eds.): Infectious Diseases of Wild Mammals Third Edition. Ames: Iowa State University Press, 498 - 502.*

*LIERZ M (2010): Avian Pox. Factsheet 6. In: Kaandorp J (Ed.): Transmissible Diseases Handbook 4th Edition. European Association of Zoo and Wildlife Veterinarians.*

*LU Y-S, PAKES SP, STEFANU C (1983): Capsular and somatic serotypes of* Pasteurella multocida *isolates recovered from health and diseased rabbits in Texas. J. Clin. Microb. 18, 292 - 295.*

*MACKINTOSH C, HAIGH JC, GRIFFIN F (2002): Bacterial diseases of farmed deer and bison. Revue Sci. Tech.* ***21****, 249 - 263.*

*MANNING EJB, COLLINS MT (1999): Paratuberculosis in Zoo Animals. In: Fowler ME, Miller RE (Eds.): Zoo and Wild Animal Medicine: Current Therapy 4. Philadelphia: WB Saunders Co., 612 - 616.*

*MAURIN M, RAOULT D (1999): Q fever. Clin. Microb. Rev.* ***12****, 518 - 553.*

*MENG XJ (2010): Hepatitis E virus: animal reservoirs and zoonotic risk. Vet. Microb. 140, 256 - 265.*

*MERTENS PPC, MAAN S, BATTEN, C, DARPEL KE, SHAW A, MAAN NS, NOMIKOU K, ANTHONY SJ, VERONESI E, OURA CAL, CARPENTER S, MELLOR PS (2009): Bluetongue diagnosis. In: Mellor P, Baylis M, Mertens P (Eds.): Bluetongue. London: Academic Press, 365 - 396.*

*MILLER MW (2001): Pasteurellosis. In: Williams ES, Barker IK (Eds.): Infectious Diseases of Wild Mammals, Third Edition. Ames: Iowa State University Press, 330 - 339.*

*MILLS JN, CHILDS JE (2001): Rodent-borne hemorrhagic fever viruses. In: Williams ES, Barker IK (Eds.): Infectious Diseases of Wild Mammals, Third Edition. Ames: Iowa State University Press, 254 - 270.*

*MÖRNER T (2001): Miscellaneous Bacterial Diseases: Campylobacter Infection. In: Williams ES, Barker IK (Eds.): Infectious Diseases of Wild Mammals, Third Edition. Ames: Iowa State University Press, 488 - 489.*

*OIE (2009): Manual of Diagnostic Tests and Vaccines for Terrestrial Animals, 6th Edition, 2008, (updated 14 August 2009): Accessed from http://web.oie.int/eng/normes/MMANUAL/A_Index.htm*

*OURA CAL, EDWARDS L, BATTEN, CA (2013): Virological diagnosis of African swine fever – comparative study of available tests. Virus Res.* ***173****, 150 - 158.*

*PANTIN-JACKWOOD MJ, SWAYNE DE (2009): Pathogenesis and pathobiology of avian influenza virus infection in birds. Revue Sci. Tech.* ***28****, 113 - 136.*

*RADOSTITS OM, BLOOD DC, GAY CC (1994): Veterinary Medicine: A Textbook of the Diseases of Cattle, Sheep, Pigs, Goats and Horses, Eighth Edition. London: WB Saunders.*

*REPERANT LA, RIMMELZWAAN GF, KUIKEN T (2009): Avian influenza viruses in mammals. Revue Sci. Tech.* ***28****, 137 - 159.*

*ROBERTSON B (2006): Hepatitis A and E. Topley and Wilson's Microbiology and Microbial Infections Tenth Edition. Virology: Volume 2. Cox FEG, Wakelin D, Gillespie SH, Despommier DD (Eds.), Wiley-Blackwell, Oxford, UK. 1160 - 1188.*

*ROSEF O, GONDROSEN B, KAPPERUD G, UNDERDAL B (1983): Isolation and characterization of Campylobacter jejuni and Campylobacter coli from domestic and wild mammals in Norway. Appl. Environ. Microbiol.* ***46****, 855 - 859.*

*SHOTTS EB JR. (1984): Leptospirosis. In: Davis JW, Karstad LH, Trainer DO (Eds.): Infectious Diseases of Wild Mammals Second Edition. Iowa State University Press, Ames, Iowa, USA. 323 - 331.*

*SKIRROW MB. (1994) Diseases due to Campylobacter, Helicobacter and related bacteria. J. Comp Path.* ***111****, 113 - 49.*

*SNOEYENBOS GH (1994): Avian Salmonellosis. In: Beran GW (Ed.): Handbook of Zoonoses Second Edition Section A: Bacterial, Rickettsial, Chlamydial, and Mycotic. Boca Raton: CDC Press, 303 - 310.*

*THOEN CO, JOHNSON DW (1981): Johne's Disease (Paratuberculosis). In: Davis JW, Karstad, LH, Trainer, DO (Eds.): Infectious Diseases of Wild Mammals Second Edition. Ames: Iowa State University Press, 275 - 279.*

*TIMONEY JF, GILLESPIE JH, SCOTT FW, BARLOUGH JE (1988): Hagan and Bruner's Microbiology and Infectious Diseases of Domestic Animals, Eighth Edition, Itheca: Cornell University Press.*

*USAHA COMMITTEE ON FOREIGN ANIMAL DISEASES (1998): Foreign Animal Diseases "The Gray Book". Richmond: United States Animal Health Association (USAHA).*

*VAN CAMPER H, FRÖLICH K, HOFMANN M (2001): Pestivirus Infections. In: Williams ES, Barker IK (Eds.): Infectious Diseases of Wild Mammals Third Edition. Ames: Iowa State University Press, 232 - 244.*

*VANDERHALLEN H, KOENEN F (1998): Identification of encephalomyocarditis virus in clinical samples by reverse transcription-PCR followed by genetic typing using sequence analysis. J. Clin. Microbiol.* ***36****, 3463 - 3467.*

*WILLIAMS TP, KASORNDORKBUA C, HALBUR PG, HAQSHENAS G, GUENETTE DK, TOTH TE, MENG XJ (2001): Evidence of extrahepatic sites of replication of the hepatitis E virus in a swine model. J. Clin. Microbiol.* ***39****, 3040 - 3046.*

*WINKLER WG, LEWIS VJ (1981): Lymphocytic Choriomeningitis, CRC Handbook Series in Zoonoses Section B Volume II, Beran WG (Ed.), CRC Press, Boca Raton, Florida, USA. 33 - 40.*

*WRAY C (1994:) Mammalian Salmonellosis. In: Beran GW (Ed.): Handbook of Zoonoses, Second Edition Section A: Bacterial, Rickettsial, Chlamydial, and Mycotic. Boca Raton: CRC Press, 289 - 302.*

# SHIPPING BIOLOGICAL SPECIMENS: CRIME OR PASSION?

NIPHUIS H, FAGROUCH Z, VERSCHOOR E

Biomedical Primate Research Centre (BPRC), Dept. of Virology, Primate Viral Diagnostics Lab, Molecular Virology Unit, Lange Kleiweg 139, 2288 GJ RIJSWIJK, THE NETHERLANDS;
niphuis@bprc.nl

The Primate Viral Diagnostics Lab at the Biomedical Primate Research Centre in the Netherlands has been receiving more than 2200 parcels with biological materials over the last five to ten years.
Most parcels were correctly packed but some cases the senders urgently need some training in sending biological specimens by post or courier.

Sending parcels correctly is depending on:

Tissue type
- Serum, blood, (fixed) tissue

Transport on
- Dry ice
- Cool packs
- Room temperature

Is the transport by
- Overnight delivery
- 24-hour delivery
- Regular post?

Bio-safety level
- Is the specimen infectious, yes or no? If yes; what risk-category (CDC)?
- Just unknown?
- Is the specimen genetically modified?
- Do we need special safety documents or transport as Dangerous Goods?

CITES regulations
- Do we require CITES documents for this species?

Consequences of unauthorised and not well-packed parcels?
- Quality loss of the shipped specimen
- Fine from the authorities

We will provide inside information on all point of discussion and show pictures of well and not well-packed parcels, which arrived at our lab.

## References

*http://www.cdc.gov/az/*
*http://www.dgm.nl*
*http://www.cites.org/eng/app/appendices.php*

# RHINOCEROS FEET – NEVER ENDING STORY OR A SOLUTION? EXPERIENCES FROM MANAGEMENT CHANGES AT THE WILHELMA

KNAUF-WITZENS T[1], RIETSCHEL W[2]

[1]Wilhelma Zoological-Botanical Gardens Stuttgart, Wilhelma 13, 70376 Stuttgart, GERMANY; tobias.knauf-witzens@wilhelma.de
[2]Pferdeklinik in Kirchheim, Nürtinger Str. 200, 73230 Kirchheim/Teck, GERMANY

Problems with Rhinoceroses' feet are common. The hind feet of males are especially vulnerable. Reasons discussed are extreme strain during mating; unsuitable enclosure surfaces; inadequate management - lack of humidity, exercise, and overweight from surplus feeding. Additionally, lacks of essential vitamins, minerals, proteins, fatty acids are supposed to play a role. These result in cracks and deep fissures at the transition between the hard nail and the flexible sole of the toe leading to inflammation and bleeding. "Wild flesh" in this area causes lameness and unwillingness to mate.

At the Wilhelma we keep an Indian rhinoceros bull named "Bruno" (*Rhinoceros unicornis* - Intl Stbk # 0123, born 1985) who had problems with his feet even before his arrival with us in 1997, when he weighed approximately 2.8 tons. Symptoms observed were: lameness; proliferating spongy skin; overgrowth and cracks in the soles and horn. At first he was put on a diet to reduce his weight to approximately 2.2 tons. Local treatment was performed under anaesthesia. He was immobilised 39 times up to 2011.

In 2010 we changed his management system. He had been kept in his stable at night and during the cold season on a concrete floor. During the day, depending on the weather, he was offered a sanded outdoor enclosure. In October 2010 he was offered a mat in his stable comprising five to six bales of peat mixed with one bale of straw, which was watered. After this change his feet slowly improved. A panaritium began to heal and by three months later the observed bleeding had stopped. In May 2011 his feet had very little inflamed tissue. His nails were cut and feet treated for the last time. The cracks in the soles healed and neither bleeding nor lameness recurred. Normal growth of nails in the following years has not disturbed Bruno and he uses his four legs equally.

The idea of trying the peat mat came from domestic horse management where it is used for the treatment of hoof problems. It not only gives a soft and humid surface but also, due to the humic acids, is a local disinfectant. Initially there were concerns about its hygienic status but we found that the mat can be left for three or four weeks depending on the use of the indoor enclosure. The mat should be placed as far as possible from the feeding and defecating place and cleared daily of manure. Urinating on the mat had no negative impact. Although peat is a non-sustainable resource because of its harvesting process, we have simplified its procurement by using the same type as our gardeners.

In summary we can recommend the use of a peat mat for the problematic feet of male Indian rhinoceroses. It is an easy and cost effective change of management, which has supported the improvement in the foot condition of our bull who has had a long history of foot problems. Ongoing check-ups will establish the extent to which the inflamed areas have been stabilised. If there are no further clinical symptoms he will be spared further immobilisations.

# SUPRAOCCIPITAL CRANIECTOMY FOR TREATMENT OF CLAVARIAL HYPEROSTEOSIS IN CAPTIVE LIONS (*PANTERA LEO*)

SHAMIR HM[1], LOMBARDO R[2], MCCAIN S[3], MACKILLOP E[4]

[1]The Hebrew University of Jerusalem, The Faculty of Agriculture, Nutrition and Environmental Studies, Koret School of Veterinary Medicine, P.O. Box 12, Rehovot 76100, Israel; shamir@agri.huji.ac.il
[2]NVA Clinica Neurologica Veterinaria, Via Isaac Newton 14, 20148 Milano, ITALY
[3]Birmingham Zoo, Inc., 2630 Cahaba Road, Birmingham, AL 35223, USA
[4]Pittsburgh Veterinary Specialty & Emergency Center, 807 Camp Horne Road, Pittsburgh Allegheny, PA 15237-1207, USA

Hyperostosis of the bones surrounding the caudal fossa is a well-described abnormality causing neurological dysfunction in young captive lions. The condition has been associated with vitamin A deficiency although the precise mechanism is not clear. Clinical signs are usually referable to compression of the cerebellum and caudal brain stem and include incoordination, ataxia, opisthotonus, and head tilt. Death can occur as the disease progresses and affected animals are often euthanised due to progressive neurological deterioration. Diagnosis is typically made at necropsy by identifying thickening of the skull with secondary compression of the cerebellum, with or without herniation. In the last ten years, CT and MRI are more readily available for use in zoo animals enabling antemortem diagnosis of this disorder. Early diagnosis has prompted veterinarians to treat this disease with vitamin A supplementation. Even though it is not known at what stage vitamin A is crucial for normal development of the skull in growing lions, in some less severe cases, supplementation with vitamin A has resulted in resolving of clinical signs. No imaging is available to show an actual reduction in the size of the hyperostotic skull bones or widening the narrowed foramen magnum following the medical treatment in these cases. When conservative therapy fails, surgical decompression could be attempted. The Sub-occipital bone and dorsal aspect of the cranial cervical vertebrae are exposed through dorsal midline approach. A high speed drill is used to remove the supraoccipital part of the occipital bone to relieve compression of the cerebellum and caudal brain stem as well as widening of the foramen magnum. The lamina of C1 is also removed if indicated. Similar surgical procedure was performed in five lions in the past six years. We present the clinical signs at presentation, skull and brain imaging, surgical approach, rate of recovery; outcome and long term follow up of these lions. All lions recovered well from the procedure and improved in the weeks following the surgery. One lion deteriorated five to six weeks post-operatively but improved with broad spectrum antibiotics and corticosteroids. Vitamin A supplementation at this stage did not seem to alter the outcome. We conclude that surgical correction of the bone abnormality is warranted whenever conservative treatment fails and until more information is available on ways to prevent this disease in captive lions.

# ASIAN ANIMALS: IN SITU MEDICINE, MANAGEMENT AND CONSERVATION - WHAT ZOO VETERINARIANS CAN DO

CHAI N

Ménagerie du Jardin des Plantes, Muséum national d'Histoire naturelle, 57 Rue Cuvier 75005 Paris, FRANCE; chai@mnhn.fr

## Summary

The extensive and varied veterinary disciplines are now recognised as key to wildlife conservation. More and more zoo veterinarians are involved in *in situ* projects. However, we see that most – if not all – conservation projects have a multidisciplinary approach. If possible, a veterinarian should not be interested only in a few fields, but definitively have this "One Health" approach, if the will is to get more involved in sustainable conservation. This lecture proposes some examples of the wide range of activities that zoo veterinarians may do for Asian animals, based on the author's personal experience.

## Introduction

In general, a zoo veterinarian's role mainly focused on ex-situ populations, applying therapeutic medicine, surgical procedures for individuals and preventive medicine for populations. In the last 10 years we have seen an explosion of zoos supporting in-situ wildlife conservation, and zoo veterinarians being active participants in that dynamic (DEEM, 2007). This increasing conservation effort of the Zoo community and evolving relationship between zoo and field health work offers many opportunities for zoo veterinarians to join wildlife veterinarians in protecting the health of threatened species. And today, more zoo veterinarians have several roles within in-situ conservation projects (DEEM, 2007; LAMBERSKI et al., 2007; MAZET et al., 2007; MILLER, 1992). In addition to their basic training in veterinary medicine and surgery, most zoo veterinarians have skills in many fields like for instance, animal husbandry, biology, conservation biology or zoology. A zoo vet may be able to act as a conservation project manager, an epidemiologist, an anaesthesiologist, a researcher, a surgeon… Veterinarians performing disease research in infectious diseases of utmost importance can literally have the survival of a species depend on their expertise. Other veterinarians are involved in fundamental and applied research projects where the results are paramount for population management. In the last years, we have (finally) seen the emergence of One Health/Conservation Medicine programmes (DEEM, 2011), officially recognised by international institutions. However, we believe that the multidisciplinary approach has always been the basis, the native foundation of any conservation projects (CHAI et al., 2010). In our opinion, in-situ projects have necessarily to study the interconnection between the health of wildlife, domestic animals, humans and ecosystems. This is particularly true in Asia (CHAI, 2010).
This lecture proposes some examples of the wide range of activities that zoo veterinarians may do for Asian animals, based on the author's personal experience.

## Field health work: from animal populations to particular clinical cases

Zoo veterinarians may work in a non-governmental organisation. In Laos, ElefantAsia (http://www.elefantasia.org) concentrates efforts in three main directions: elephant veterinary care,

educational/environmental awareness and economic viability for mahouts. For the vet part, ElefantAsia have developed a highly specialised mobile veterinary care unit that travels throughout the country. Vets have in charge the development of health care programmes for elephant owners, to improve domesticated elephant health in Laos. In parallel, we have also launched an extensive research project on elephant tuberculosis. Zoo vets may also use their veterinary skills for animal population management. In Cambodia, several rescue centres have been advised in animal husbandry and welfare concerns. “Field endoscopy” is a very attractive technique to make health evaluation of bird collections, sexing, and in order to propose reproduction plan of threatened species (CHAI et al., 2006). This technique can also be taught. That has been done for some vets in Bangladesh.
Zoo vets may work as vet surgeon. There are lots of works in animal care in rescue centres: from a simple emergencies and wildlife first care to highly advanced medicine and surgery. We will give here some examples of clinical cases in birds, tigers, elephants and primates, including apes, treated in Cambodia and Indonesia.

## The zoo vet as a researcher

Genetics matters are one important topic. All the European and international breeding programmes are based on genetic parameters. Without rigorous genetic management one cannot undergo rigorous conservation projects. This is true for conservation in- and ex-situ as well. Here we give a short view of a genetic study project on Asiatic wild bovids (ROPIQUET et al., 2008), especially on the Gaurs (*Bos gaurus*). Samplings on wild specimens have been done in Laos, Bangladesh and Cambodia.

## Following the One Health philosophy

Always think of the One Health philosophy. Taking into account the cultural dimension of the human populations concerned, and their cultural identity, and favouring a true dialogue, are essential for durable projects. If possible, a veterinarian should not be interested only in conservation, but in sustainable conservation, by undertaking multidisciplinary projects. A bee-keeping programme has been launched in Cambodia to develop an alternative micro-economic activity locally, in respect of the environment (CHAI, 2010).
In 1992, Eric Miller wrote an article in the Journal of the American Veterinary Medical Association titled “Zoo Veterinarians – Doctors on the Ark?” (MILLER, 1992). Yes, we believe that we all, as zoo veterinarians should be part of the Ark. Finally, the distinction between the ‘zoo’ and ‘wildlife’ veterinarian has become increasingly less clear (DEEM, 2007). Maybe we should then only talk now about “zoo and wildlife veterinarians”.

## References

*CHAI N, ROMAN Y, PIGNON CP, SIMON R, RIGOULET J (2006): Endoscopy, a precious tool for wildlife conservation. Proc. European Association of Zoo and Wildlife Veterinarians. 6th Scientific Meeting. Budapest, Hungary. 19 - 23 May, 152 - 154.*

*CHAI N (2010): Zoo Veterinarians and Conservation, An example of a conservation project in Cambodia. EAZA Conservation Forum 2010 – Murten, Switzerland – June 29th to July 3rd.*

*CHAI N, COLLONGUES H, PALOMINO C, ROSU O, COLLARD L, RAMOS M (2010): Ikamaperu, a multidisciplinary project for conservation and sustainable development in Peruvian Amazonia.*

*Veterinary aspects of the project. Proc. International Conference on Diseases of Zoo and Wild Animals 2010, Madrid, Spain. 12 - 16 May, 162.*

*DEEM SL (2007): Role of the Zoo Veterinarian in the Conservation of Captive and Free-Ranging Wildlife. International Zoo Yearbook **41**, 3 - 11.*

*DEEM SL (2011): Disease Risk Analysis in Wildlife Health Field Studies. In: Miller RE, Fowler ME (Eds.): 7th edition of Zoo and Wild Animal Medicine, Elsevier, St. Louis, 2 - 7.*

*JAKOB-HOFF RK, WARREN S (2011): Conservation Medicine for Zoo Veterinarians. In: Miller RE, Fowler ME (Eds.): 7th edition of Zoo and Wild Animal Medicine, Elsevier, St. Louis, 15 - 23.*

*LAMBERSKI N, WEST C (2007): Role of Veterinarians in Regional Management Plans. International Zoo Yearbook **41**, 16 - 23.*

*MAZET C, JOHNSON K (2011): Approaching Health Problems at the Wildlife-Domestic Animal Interface. In: Miller RE, Fowler ME (Eds.): 7th edition of Zoo and Wild Animal Medicine, Elsevier, St. Louis, 153 - 160.*

*MILLER RE (1992): Zoo Veterinarians – Doctors of the Ark? J. Am. Vet. Med. Assoc. **200**, 642 - 647.*

*ROPIQUET A, GERBAULT-SEUREAU M, DEUVE JL, GILBERT C, PAGACOVA E, CHAI N, RUBES J, HASSANIN A (2008): Chromosome evolution in the subtribe Bovina (Mammalia, Bovidae): The karyotype of the Cambodian banteng (Bos javanicus birmanicus) suggests that Robertsonian translocations are related to interspecific hybridization. Chromosome Res. **16**, 1107 - 1118.*

# EYE PATHOLOGIES AND TREATMENTS IN BEARS RESCUED FROM THE BEAR BILE FARMING INDUSTRY IN CHINA

REYNARD J[1], BANDO M[1], HARTLEY C[2], DONALDSON D[2], BACON H[1 3], ROBINSON J[1], FIELD N[1]

[1]China Bear Rescue Centre (CBRC), Longqiao, Xindu District, Chengdu, Sichuan, 610505 CHINA; jreynard@animalsasia.org
[2]Animal Health Trust, Lanwades Park, Kentford, Newmarket, Suffolk CB8 7UU, UK
[3]The University of Edinburgh, Easter Bush Veterinary Centre, The Royal (Dick) School of Veterinary Studies, Jeanne Marchig International Centre for Animal Welfare Education, Roslin EH25 9RG, UK

## Summary

Animals Asia Foundation has rescued 285 bears from the bear bile industry in China. At the China Bear Rescue Centre (CBRC) the veterinary team has developed an extensive database on the pathologies and welfare issues associated with bear farming. This study utilises records from between October 2001 and December 2012 to determine the prevalence of eye pathologies and the success of treatments in the current living population of bears. Of the 145 resident bears at CBRC, 68 (47 %) had ophthalmic pathologies in their history. Ten bears (6.89 %) had corneal ulcers, 28 bears (18.6 %) had abnormalities of the retina, 10 bears (6.89 %) had cataracts identified, of which five were hypermature and required surgery. Of the retinal abnormalities, retinal haemorrhage was the most common finding followed by retinal detachment, chorioretinal infiltrates, retinal scarring and peri-vascular infiltrates. Four bears (2.75 %) have asymptomatic bilateral sub-luxation of the lens, two cases (1.4 %) developed acute posterior lens luxation resulting in enucleation. Five bears (3.44 %) had eyelid abnormalities causing trichiasis and chronic epiphora. These underwent HotzCelsus procedure resulting in clinical improvement or resolution. There were six blind bears living at the centre.

## Introduction

Bear bile is used in Traditional Chinese Medicine to treat illnesses from haemostatic disorders to throat disease. Due to high levels of ursodeoxycholic acid (UDCA) it is also used to treat disorders of the liver and gall bladder. Synthetic UDCA has been available since 1955 and over 54 culturally acceptable herbal alternatives also exist. It is estimated over 100 bear farms exist across China housing at least 10,000 bears in inadequate, intensive farming conditions. These bears are surgically altered to form a fistula between the gall bladder and body wall; many are housed in body sized cages to facilitate twice daily extraction. The bear bile industry in China is associated with poor health and welfare (LOEFFLER et al., 2007). Bears arrived at the centre in small cages and had severe hyperkeratosis of the pads due to inadequate wear; often bar indentations were present from the cage floor. Severe dental disease caused by poor diet and bar biting was common and most bears were malnourished. On cholecystectomy gall bladder stones, polyps, pus and foreign bodies were common findings.

A variety of ophthalmic problems have been previously reported in bears, this includes lens luxation (KAYA and DORRESTEIN, 1994; WOLFF, 1988), cataracts (KAYA and DORRESTEIN, 1994; WOLFF, 1988; KLOS and LANG, 1982), nasolachrymal duct aplasia, chronic keratitis and corneal trauma (BLAKE and COLLINS, 2002). The current CBRC population comprises 140 Asiatic black bears (*Ursus thibetanus*), three Eurasian brown bears (*Ursus arctos arctos*) and two Tibetan brown bears (*Ursus arctos*

*pruinosus*). We were interested in determining the prevalence of eye disease in our population and responses to treatment based on over ten years of veterinary records and five years of collaboration with the Animal Health Trust (AHT), UK.

## Materials and methods

Full eye exams were performed as part of routine health checks carried out every two to three years. In addition to this monthly den checks allowed early detection of eye problems by monitoring for abnormal ocular signs. From 2008, bears with abnormalities have been examined by veterinary ophthalmologists from the Animal Health Trust (AHT) on an annual to biennial basis. Bears for health check were anaesthetised with a protocol of medetomidine 0.0125-0.02 mg/kg (Sedamed®, Vet Pharm, Auckland, New Zealand) combined with tiletamine / zolazepam 1.25 mg/kg-2 mg/kg (Zoletil®, Vibac, Cedex, France) intramuscular induction, followed by endotracheal intubation and maintenance on isoflurane and oxygen. Post intubation anaesthetic reversal was performed with atipamezole 0.03 - 0.05 mg/kg (Antisedan® Pfizer, Espoo, Finland) given intravenously.

Ophthalmic exam included Schirmer tear test (MSD Animal Health, Milton Keynes, UK), intraocular pressure using a Tonopen® (Reichert Technologies, NY, USA), external eye exam and examination of the cornea, anterior chamber and lens using a slit-lamp biomicroscope (Lanling®, Jiang Su, China). Tropicamide (Hubei Qianjiang Pharmaceutical Co. Ltd. Qianjiang, China) was used to dilate the pupil to allow fundic exam using binocular indirect ophthalmoscope (WelchAllyn, NY, USA).

## Results and discussion

Ten bears had corneal ulcers, seven unilateral ulcers were identified and three other bears developed ulcers bilaterally up to a year apart. Eight bears had just a single incidence of corneal ulceration whilst two bears had two and three episodes respectively; no underlying cause could be found. Eleven superficial ulcers were identified, five of these responded to conservative medical management comprising a non-steroidal anti-inflammatory, oral meloxicam 0.1 mg/kg (Jiangsu Yunyang Group Pharmaceutical Co Ltd, Danyang, China) combined with antibiotics, either potentiated amoxicillin 15 mg/kg BID (Baiyunshan Pharmaceutical, Guangzhou, China) or doxycycline 5mg/kg BID (Heibei Dongfeng Pharmaceutical Co. Ltd. Yongnian, China). Six ulcers required surgical debridement and grid keratotomy under general anaesthesia; these were followed up with oral medication as described above and healed within one to three weeks without incident. Two deep stromal ulcers were identified, one of which had a descemetocele and these were treated with a conjuctival pedicle graft (figure 1).

Cataracts were identified in ten bears comprising six unilateral and four bilateral cataracts. Six bears were identified as having hypermature cataracts requiring surgery. AHT veterinary ophthalmologists performed four unilateral cataract surgeries and two bilateral surgeries. After surgery four of the six bears had improved sight. One bear with a unilateral cataract had severe fibrosis post-surgery and medial strabismus. One bear with bilateral cataract surgery suffered a retinal detachment in one eye post-surgery and one bear with a unilateral cataract suffered a retinal detachment post-surgery. Cataract surgery carries surgical risks but has the potential to restore sight in individuals with blindness caused by hypermature cataracts.


*Fig. 1: Descemetocoele tread by conjunctival pedicle graft. The picture on the left shows the epithelium being carefully stripped from around the descemetocoele. The picture on the right shows the sutured pedicle graft in place at the end of surgery. (Surgeon: David Donaldson, AHT, ©Joanna Reynard / AAF 2012)*

Bilateral lens subluxation was identified in five individuals. Four bears were stable and monitored at weekly den checks. A fifth individual with previously identified bilaterally subluxated lens developed an acute posterior lens luxation with an associated glaucoma and this was enucleated. A sixth bear with no previous history developed an acute posterior lens luxation which could be seen visually in the den as an aphakic crescent (figure 2). This bear developed blepharospasm, chemosis and epiphora. The eye was enucleated due to ongoing discomfort.

*Fig. 2: Posterior lens luxation demonstrating a visible aphakic crescent. (©Monica Bando / AAF 2012)*

Retinal abnormalities comprise the majority of abnormalities found in this population of bears, 28 (19.3 %) had abnormalities detected on fundic exam. Four individuals had inactive chorioretinal scarring (2.75 %), four individuals had prominent active chorioretinal infiltrates (2.75 %), and three individuals have peri-vascular infiltrates (2 %). Retinal haemorrhages were found in 20 bears (13.8 %); these varied from mild pin point haemorrhages in the retina to severe larger subretinal, preretinal or vitreal haemorrhages. One bear has had instances of hyphaema visible in the anterior chamber. Taking multiple factors in to consideration five bears with retinal haemorrhage have been started on medication for hypertension, their progress is closely monitored. Eight bears (5.5 %) were identified as having retinal detachments. In two cases these were determined to be partial and AHT ophthalmologists successfully performed laser retinopexy to prevent progression of the detachment.

Conformational causes of trichiasis were detected in five individuals with clinical signs of epiphora. Distichia were also identified in three of these individuals. Corrective surgery was performed in all of these bears. One bear was identified as having aplasia of the nasolachrymal punctae. Three bears

had wounds to the eyelid, two of these needed surgery to repair the damage. One bear was identified with a subconjuctivial fatty mass that did not need treatment. Three bears were identified with an infectious blepharitis that was refractory to doxycycline 5mg/kg BID (Heibei Dongfeng Pharmaceutical Co. Ltd. Yongnian, China).

Six blind bears live at the centre, three are centrally blind and three are blind due to acquired conditions. These six individuals are deemed to live a good quality of life and behavioural observations demonstrated these bear did not show impaired social interactions and were not competitively displaced from resources (DALLAIRE et al., 2012).

In conclusion ophthalmic disease is an important issue in ursid medicine and retinal pathologies were the most common finding in this population of bears. Corneal ulcers and cataracts were also regularly identified but appropriate treatment resulted in good clinical outcomes. Full ocular exam in bears is encouraged where resources allow. Bear farming presents a current welfare concern to bears in Asia. It is hypothesised that severe conditions on bear farms may be linked to increased incidences of pathologies in this population; comparison to a control population would be needed to confirm this.

## References


*BLAKE CN, COLLINS D (2002): Captive Ursids: results of a multi-institutional survey. Proc. Ann. Meet. Am. Assoc. Zoo Vet. Milwaukee, Wisconsin, 21 - 26.*

*DALLAIRE JA, FIELD N, MASON G (2012): Activity and enrichment use in disabled Asiatic black bears (Ursus thibetanus) rescued from bile farms. Anim. Welfare **22**, 167 - 176.*

*KAYA M, DORRESTEIN GM (1994): Dental and Eye diseases of Istanbul bears. Proceedings of the International Conference on Aspects of Bear Conservation **1**, 143 - 148.*

*KLOS H-G, LANG EM (1982): Handbook of Zoo Medicine: Diseases and treatments of wild animals in zoos, games parks, circuses and private collections. New York, USA: Van Nostrand Reinhold Company, 123 - 130.*

*LOEFFLER K, ROBINSON J, COCHRANE G (2007): Compromised health and welfare of bears in China's bear bile industry, with special reference to the free drip bile extraction method. Anim. Welfare **18**, 225 - 235.*

*WOLFF P (1988): Selected medical aspects of the spectacled bear (Tremarctos ornatus). Proceedings of the First International Symposium on the Spectacled Bear. Lincoln Park Zoo, Chicago, Illinois, USA, 313 - 317.*

# INCIDENCE AND RISK FACTORS OF AIR SACCULITIS IN BORNEAN ORANGUTANS (*PONGO PYGMAEUS*) AT AN INDONESIAN REINTRODUCTION CENTRE

DENCH R, PHILIPPA J, SULISTYO F

Borneo Orangutan Survival Foundation, Central Kalimantan Orangutan Reintroduction Project at Nyaru Menteng, Jalan Tjilik Riwut Km 29, Palangkaraya, Central Kalimantan, INDONESIA; Joost.philippa@gmail.com

Air sacculitis is a common condition affecting captive orangutans, both in zoo and rehabilitation settings, but there are no published reports of air sacculitis in wild orangutans. It is known to be a difficult disease to manage, often taking weeks to clear and with the potential to recur. Identification of risk factors for the disease is an important step in adjusting (semi) captive husbandry to reduce incidence.

More than 600 endangered Bornean orangutans (*Pongo pygmaeus*) are housed at the Central Kalimantan Orangutan Reintroduction Project at Nyaru Menteng, in preparation for their reintroduction to the forest.

We reviewed clinical records and intrinsic/extrinsic factors for orangutans diagnosed with air sacculitis between January 2010 and December 2011. In total, 62 cases were recorded; an annual incidence of 5.1 % (n = 605) and accounting for 4.6 % of all veterinary cases. Of these cases, 48 % were animals with previous history of air sacculitis, thus considered recurrent cases. Clinical signs other than “halitosis” and visible/palpable airsac distention were uncommon, but included fever (36 %), upper respiratory tract congestion/nasal discharge (13 %). There was no significant association between bodyweight and air sacculitis incidence.

Mean age was 6.7 years (range: 2 - 16 years). Air sacculitis incidence was highest in those aged 4 to 7 years and significantly lower for those aged ≥ 8 years. Males had a significantly higher incidence than females in the 4 to 7 years age group and in forest school. For the forest school group (daytime forest access), incidence (17 %) was significantly greater than in other rehabilitation stages; full forest access (1.7 %); no forest access (1.8 %). Incidence was significantly higher for larger communal overnight groups and groups with a low cage ventilation score. In months with ≥ 200mm rainfall, case incidence was significantly higher than in drier months, but there was no significant correlation between case incidence and month, monthly average maximum-, mean- and minimum temperatures, and average wind speed.

Determining risk factors for diseases like air sacculitis can guide husbandry adjustments for disease prevention.

# SLOW LORIS (*NYCTICEBUS* SPP.) UNCOMMON PATHOLOGIES REPORTED IN AN INDONESIAN PRIMATE REHABILITATION CENTRE

ROSU O[1, 2], UDRESCU AL[1], SANCHEZ KL[2]

[1]University of Agronomic Sciences and Veterinary Medicine Bucharest, Faculty of Veterinary Medicine, Splaiul Independentei 105, 050097 Buchrest, ROMANIA; rosu.ovidiu@gmail.com
[2]International Animal Rescue Indonesia, Ciapus, 16001 Bogor, INDONESIA

Slow lorises (*Nyctecebus* spp.) are listed as vulnerable or endangered (IUCN Red List) endemic primate species in Indonesia, heavily hunted for the pet trade. During a six-months-period of medical assistance at IAR Ciapus primate centre - West Java, a series of Slow Loris uncommon pathologies were reported.

Case 1: Adult 700 g female presented several progressive plantar, limb and lumbar ulcerations with overlapping *Klebsiella pneumoniae*, *Candida albicans* and *Escherichia coli* infection. The degenerative process involved several finger muscles and tendons, with loss of mobility leading to dry gangrene that required amputation. The ulcers evolved during a five-months time frame and followed several specific and nonspecific treatment schemes: Amoxicillin/Clavulanic acid (62.5 mg PO q 12h, 7 days), Neomycin/placenta extract (topically, with change of bandage), Enrofloxacin (5 mg/kg IM q 24h), Miconazole ointment (topically, 10 days), dressing Farmycetin gauze (changed daily, 10 days), Meloxicam (0.2 mg/kg PO, q 24h, 3 days), Chinese herbal powder (topically, 10 days), Neomycin/placenta extract mixed gel (topically, 10 days).
Case 2: Adult 530 g male developed an infection following a tooth extraction which relapsed into a massive cheek septic abscess, regardless of the ongoing general antibiotic therapy. The pus samples showed that *Klebsiella pneumoniae* was responsible. Putting in place a drain and changing the antibiotic with Chloramphenicol (topically, q 24h, 7 days) in respect with the antibiogram, led to the full recovery.
Case 3: Adult 650 g female arrived with multiple lacerations due to several lead bullets, showing muscle stiffness that in time evolved into prolonged systemic contractions. Lead poisoning, *Clostridium tetani* or radiant pain from the wounds was considered. Despite local and general treatment (wound dressing, antibiotic treatment Amoxicillin/Clavulanic acid 62.5 mg PO q 12h, 7 days, and pain management with Meloxicam 0.2 mg/kg PO, 3 days, Bupivacaine 1m/kg local infiltrations and Buprenorphine 0.02 mg/kg IM q 12h, 2 days) the wound edges form one affected limb did not close and started to retract exposing the muscle and bone structures. After a lidocaine nerve block test, a complete, sudden relaxation of the entire body muscle was observed. It was then decided to perform a mid-femoral amputation.
Case 4: Adult male 780 g, first arrived at the centre 1.5 years ago, treated for corneal ulceration and dental abscess, with good development and body weight gain. Keepers observed a slightly altered behaviour and movement difficulties. Following an X-ray examination, a lumbar alteration was observed that could explain the clinical signs. Based on the absence of systemic alterations he was given Meloxicam (0.2 mg/kg PO, q 12h, 3 days) and put back to his outdoor enclosure under close observation.

# HEALTH SCREENING OF A LEMUR POPULATION (*EULEMUR* SP.) ON MBOUZI ISLET (MAYOTTE ISLAND)

ORTIZ K[1], QUINTARD B[2], LEFAUX B[2], LÉCU A[3]

[1]Réserve de la Haute Touche, UMR 7205 CNRS/MNHN, 36290 Obterre, FRANCE; ortiz@mnhn.fr
[2]Parc zoologique et botanique de Mulhouse, 51 rue du jardin zoologique, 68100 Mulhouse, FRANCE
[3]Parc zoologique de Paris, 53 avenue de Saint Maurice, 75012 Paris, FRANCE

Mbouzi islet (part of Mayotte island in the Pacific Ocean) is an 82 ha « Natural Reserve » where lemurs (*Eulemurs*) have been artificially introduced since 1997. Because of regular supplemental feeding and a lacking birth control, the lemur population has rapidly increased and was estimated to 700 animals in 2010. Artificial feeding performed by an NGO has also led to the parallel increase of a black rat population (*Rattus* sp.), and concentrated the lemurs on an area of two hectares, creating an environmentally unsustainable situation and increasing the risk of zoonotic diseases.

The AFVPZ (Association francophone des vétérinaires de parcs zoologiques) was then asked by the French National Council on Nature Protection to assist with managing this situation due to its expertise in exotic animals' health and management. The goal was to assess the health status of these lemurs, irrespective of their destination chosen by the French authorities.

A planning trip was undertaken by two vets in June 2012 to assess the field area, to meet the stakeholders involved in the project and to evaluate the material and participants available. A second trip was made in October to perform the health assessments.

There were two teams of two vets, a secretary and an animal handler in each. One vet took care of anaesthesia, health screening, sampling and measurements while the other took care of sampling packaging and identification. Within two days, 25 % of the estimated population on the islet (50 animals) was caught. Animals were trapped in a box where they were used to being fed in. For each animal, a 15 minutes pulse oxymetry monitored gas anaesthesia was performed. A clinical and ophthalmological exam was performed, morphometric measurements were taken and external parasites presence was evaluated. Blood was taken for blood smears (haemoparasites research, blood count), biochemical analysis, and viral serology. Faeces samples were taken for bacteriology and parasitology. To complete the check-up, a comparative tuberculosis skin test was conducted, and hair follicles were harvested for a genetic analysis. Tests conducted were based on recommendations from exotic pathology and lemurs experts.

All animals were kept under observation during the recovery period and then released. They were observed on the islet for the following three days.

Some of the samples were analysed on Mayotte Island by the vets, and, when possible, in the Mayotte Hospital Centre. The others samples needing special labs were packaged and sent in France, in Reunion Island and in the Netherland. CITES and IATA regulations were followed. Results will be presented at the conference.

The logistical and political aspects of this project were very challenging. Mbouzi islet has no inhabitants. Mayotte Main Island has also a lemur population, but a simple transfer was not possible without health and genetics assessment. A possibility to transfer to EAZA zoos was considered but the RCP do not include this species. Organisation of the entire project was conducted from France. Equipment and supplies were largely carried in with the team, due to poor infrastructure on Mayotte Island. The achieved goal was to introduce a rigorous and scientific process in a difficult political situation.

# ANTHROPOZOONOTIC RESPIRATORY DISEASE IN HABITUATED WILD GREAT APES – CURRENT KNOWLEDGE AND PREVENTIVE MEASURES

GRÜTZMACHER KS, KÖNDGEN S, LEENDERTZ FH

Robert Koch Institute, P23, Nordufer 20, 13353 Berlin, GERMANY; gruetzmacherk@rki.de

Infectious diseases have joined habitat loss and hunting as one of the major threats to the survival of wild great apes. Partly those diseases are enzootic such as Ebola or Anthrax, most likely originating from different sources within the great ape habitat. Others are of human origin. Because of the genetic proximity there is an enhanced risk for disease transmission from humans to closely related nonhuman primates, especially apes.

In great ape communities, habituated to humans for tourism or research, respiratory disease (RD) is the most frequent cause of morbidity and mortality. Nearly half of all long-term chimpanzee research populations have shown major declines, likely as a consequence of RD.

RD has also affected the health of mountain gorillas (*Gorilla beringei*) in the Virunga Volcanoes of Rwanda, where mortalities have been observed. Similarly, among bonobos (*Pan paniscus*) at Wamba, Democratic Republic of Congo, RD and RD-associated deaths have been reported.

Recent studies have demonstrated that such RDs can be caused by the transmission of either of the two human paramyxoviruses, the respiratory syncytial virus (RSV) and the human metapneumovirus (HMPV). These viruses had a considerable impact on the development of invasive disease leading to pneumonia and death in chimpanzees and mountain gorilla. To monitor such respiratory viruses in life animals/outbreak survivors, non-invasive methods have been established to detect the pathogens in faecal samples of wild great apes.

Disease transmission has raised concerns that the risk associated with habituation might outweigh the benefits. Survey data show, however, that research presence has had a strong positive effect in suppressing poaching around a research site. To minimise the negative side effects of research and tourism, different approaches for the prevention of disease spread from humans have been suggested. These include e.g., that only humans free of clinical signs of disease enter great ape habitat, minimum distance (> 7 m), wearing of surgical masks, removal of all human faeces and food remains from the forest, hygiene barriers at periphery of territories and overall good hygiene in camps.

However, conclusive pathogen data from both captive and wild great apes is still scarce and factors determining severity of outbreaks (secondary infections, immunity, demography) are missing. Also risk factors associated with transmission, such as pathogen incidence in certain relevant groups of people (e.g. tourists, trackers, researchers and assistants) as well as properties of the pathogens, survival in the environment and the efficiency of hygiene measures warrant further investigation.

# DIAGNOSIS AND PROPHYLAXIS OF ALVEOLAR ECHINOCOCCOSIS IN OLD WORLD MONKEYS AT THE GERMAN PRIMATE CENTRE

LAMPE K[1], MÄTZ-RENSING K[1], BECKER T[1], SCHROD A[1], BREHM K[2], GOTTSTEIN B[3], JANKO C[4], KAUP FJ[1]

[1]Deutsches Primatenzentrum (DPZ), Abteilung Infektionspathologie, Kellnerweg 4, 37077 Göttingen, GERMANY; klampe@dpz.eu

[2]Institut für Hygiene und Mikrobiologie, Josef-Schneider-Straße 2, 97080 Würzburg, GERMANY

[3]Universität Bern, Vetsuisse Fakultät, Institut für Parasitologie, Länggassstrasse 122, 3012 Bern, SWITZERLAND

[4]Technische Universität München, Lehrstuhl für Tierökologie, Hans-Carl-von-Carlowitz-Platz 2, 85354 Freising, GERMANY

Alveolar echinococcosis (AE), caused by the metacestode stage of the small fox tapeworm *Echinococcus multilocularis*, is one of the most serious helminthic diseases of the northern hemisphere. *E. multilocularis* is usually limited to a sylvatic life cycle including foxes as final hosts and rodents as intermediate hosts. However, humans and non-human primates may acquire the infection by accidental ingestion of fox tapeworm eggs, resulting in alveolar echinococcosis (AE) which is characterised by an inapparent incubation period of 5 to 15 years and a progressive course of disease with severe liver alterations and a high mortality rate in untreated patients. AE in non-human primates has been reported from zoological gardens in Europe and Japan. At the Deutsches Primatenzentrum (DPZ; German Primate Centre), 25 cases of AE in macaques (including *Macaca mulatta, Macaca fascicularis* and *Macaca silenus*) have occurred since 1994. Infected animals showed no or unspecific clinical symptoms. Constant metacestode growth led to progressive abdominal distension in most animals. Heterogenous abdominal masses without clear demarcation could be demonstrated by means of various imaging techniques. Due to the late diagnosis in affected non-human primates, therapeutic intervention was not promising. Thus, animals were euthanised at the time of diagnosis. Upon necropsy, extensive multivesicular parasitic proliferations in the liver and occasionally in additional organs, e.g. lungs and pancreas, were observed. Histological examination revealed multiple cystic structures of different size with a characteristic architecture and protoscoleces in variable numbers. Thus, infections in macaques are usually fertile, which is a contrast to human AE cases. PCR with specific primers and subsequent sequencing confirmed the diagnosis of AE. To promote an earlier intravital diagnosis, we adopted a crude antigen ELISA, which was originally designed for serodiagnosis of AE in human patients. All non-human primates of the DPZ were tested for antibodies against *E. multilocularis* by means of ELISA, yielding 44 serologically positive macaques. In order to assess the abundance of foxes, the main final hosts, in the vicinity of the enclosures, camera traps have been installed on the grounds of the DPZ. The pictures showed that certain places are regularly visited by a number of foxes, strongly indicating a direct route of transmission. Given the poor prognosis and the usually late diagnosis, we evaluated different prophylactic measures. In a pilot study, five rhesus macaques have been vaccinated with a purified recombinant 14 - 3 - 3 *E. multilocularis* antigen emulsified in 2 % alhydrogel, in order to evaluate safety and immunogenicity of the vaccine. Subsequently performed 14 - 3 - 3 ELISA revealed antibody formation. It remains to be elucidated to what extent the vaccination induces a protective immunity. Another prophylactic approach was to reduce the infection pressure by means of deworming foxes with anthelminthic baits. However, deworming baits are currently not commercially available for small-scale projects. In conclusion, our results indicate that AE represents an ongoing hazard for the health of non-human primates in areas where *E. multilocularis* is endemic.

# ULTRASONIC VOCALISATION IS ONLY PRESENT IN A LIMITED VOCAL REPERTOIRE OF COMMON MARMOSETS (*CALLITHRIX JACCHUS*)

BAKKER J[1], VAN NIJNATTEN TJM[2], BROK HPM[1], LOUWERSE AL[1], BAARENDS G[3], ARNDT SS[2], LANGERMANS JAM[1]

[1]Biomedical Primate Research Centre (BPRC), Dept. of Animal Science, Lange Kleiweg 161, 2288GJ, Rijswijk, THE NETHERLANDS; bakker@bprc.nl

[2]Faculty of Veterinary Medicine Utrecht University, Dept. of Animals in Science & Society, Division of Animal Welfare & Laboratory Animal Science, THE NETHERLANDS

[3]University of Applied Sciences HAS, Onderwijsboulevard 221, 5223 DE 's-Hertogenbosch, THE NETHERLANDS

## Summary

Limited data are available on production of ultrasonic vocalisations (USV) by common marmosets (*Callithrix jacchus*). Moreover, in contrast to rats and mice, nothing is known about USV and their potential use as indicator for their emotional state. To fill in this knowledge gap, audible and USV, were recorded during different settings. Analysis of the data shows that USV is part of the normal vocal repertoire of marmosets and are extensions of audible vocalisations. We conclude that for common marmosets USV do not provide additional information compared to audible vocalisations to assess their emotional state.

## Introduction

Vocalisations in common marmosets and their relation to behaviour are well described in the literature (BEZZERRA and SOUTO, 2007). The vocal repertoire is assumed to exist not only of audible vocalisations but also of UVS, however this has not been studied in detail (EPPLE, 1968). This study was performed to study the vocal repertoire of marmosets. First attempts were performed to create insight in the relevance of potential ultrasonic components for these animals in welfare monitoring. Laboratory rats have been shown to produce vocalisations in an ultrasonic frequency in response to painful procedures, which provides additional information about their acute emotional state (PORTFORS, 2007; KUSUI et al., 2003; BURMAN et al., 2007; MANTEUFFEL et al., 2007).

## Material and methods

Captive marmosets bred and housed at the Biomedical Primate Research Centre (BPRC, Rijswijk, The Netherlands) were recorded in their home cages during normal behaviour in family groups and in same-sex housed groups. They were exposed to assumed positive and negative stimuli while the produced vocalisations were recorded. Sound recording took place in the morning. Audible vocalisations were set as vocalisations lower than 20 kHz and were recorded with a Sony Handycam DCR-SR72E. The audible vocalisations were classified according to the description on the common marmoset website of the University of Stirling (www.marmosetcare.com). USV were defined as vocalisations higher than 20 kHz and were recorded using the Sonotrack™ (Metris B.V., Hoofddorp, The Netherlands) with an upper limit of 100 kHz; the maximum frequency detectable by the Sonotrack™.

## Results and discussion

In total, thirteen audible vocalisation types that were each recorded more than 400 times could be defined. Surprisingly, we consistently observed that only four defined call types extended into the ultrasonic range. Analysis of data recorded during undisturbed behaviour demonstrated that marmosets produced USV only as extension of audible vocalisations, but not every audible vocalisation extended into the ultrasonic range. The four vocalisation types that were found to extend into the ultrasonic range were also observed without extension into the ultrasonic range, one example is shown in figure 1A and figure 1B. Animals exposed to various assumed positive and negative stimuli produced only USV in response to negative stimuli.

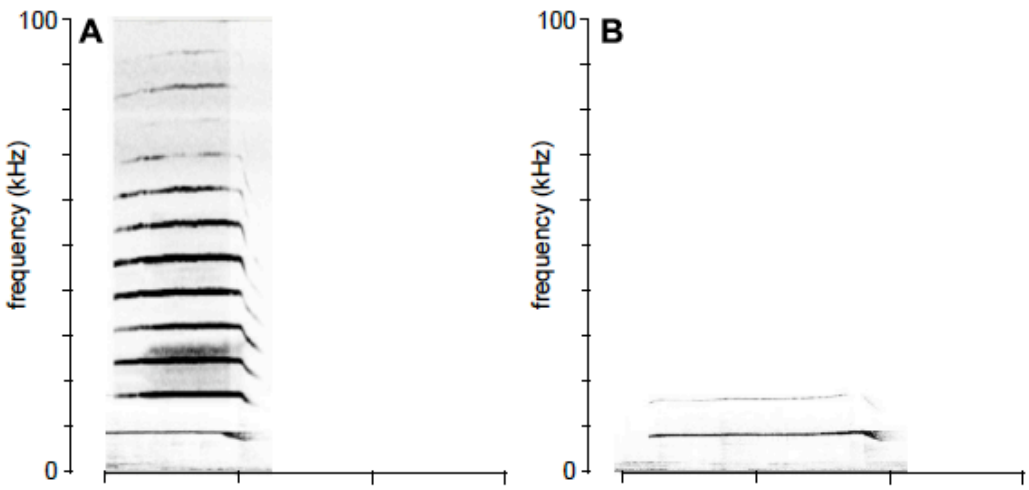


*Fig. 1A and 1B: Typical audiograms of two defined audible vocalisations;*
*(A) loud shrill with extension into the ultrasonic range;*
*(B) loud shrill without extension into the ultrasonic range.*

Our data demonstrate that common marmosets produce USV in both undisturbed and assumed stressful situations. All USV were always extensions of specific audible vocalisations and consisted of multiple frequency levels, ranging from 20 to 100 kHz. This is to the best of our knowledge the first report of the fact that USV are not produced singularly in marmosets, in contrast to rats and mice. However, the frequency of appearance of USV in the vocal repertoire seems limited. USV production in undisturbed settings showed that USV is part of the normal communication of marmosets, as reported earlier (EPPLE, 1968). Our data shows that production of USV cannot be used as reliable objective parameter for the assessment of the emotional or motivational state in the marmoset. We show that for common marmosets USV do not provide additional information compared to audible vocalisations to assess pain or distress. We cannot exclude that USV are only an associated product of audible vocalisations with potentially limited value for the animals.

## Acknowledgements

We thank Herma van der Wiel and Thea de Koning for critical reading and comments on the manuscript and Henk van Westbroek for optimising the figures.

## References

*BEZERRA BM, SOUTO A (2008): Structure and Usage of the Vocal Repertoire of Callithrix jacchus. Int. J. Primatol.* ***29****, 671 - 701.*

*BURMAN OHP, ILYAT A, JONES G, MENDL M (2007): Ultrasonic vocalizations as indicators of welfare for laboratory rats (Rattus norvegicus). Appl. Anim. Behav. Sci.* ***104****, 116 - 129.*

*EPPLE G (1968): Comparative studies on vocalization in marmoset monkeys (Hapalidae). Folia Primatol.* ***8****, 1 - 40.*

*KIKUSUI T, NISHIZAWA D, TAKEUCHI Y, MORI Y (2003): Conditioned fear-related ultrasonic vocalizations are emitted as an emotional response. J. Vet. Med. Sci.* ***65****, 1299 - 1305.*

*MANTEUFFEL G, PUPPE B, SCHÖN PC (2004): Vocalization of farm animals as a measure of welfare. Appl. Anim. Behav. Sci.* ***88****, 163 - 182.*

*PORTFORS CV (2007): Types and functions of ultrasonic vocalizations in laboratory rats and mice. JAALAS.* ***46****, 28 - 34.*

# A CONSERVATION MEDICINE APPROACH TO MANAGING DISEASE IN ALPINE UNGULATES

WALZER C

University of Veterinary Medicine Vienna, Research Institute of Wildlife Ecology, Savoyenstr.1, 1160 Vienna, AUSTRIA; chris.walzer@fiwi.at

The European Alps span eight countries, from the Mediterranean shores of Southern France to Slovenia and link with adjacent mountain ranges such as the Carpathians, Balkans and Apennines. The Alps harbour an extraordinary diversity of habitats, plants and animals including many endemics. The Alps are exceptionally rich in biodiversity, mainly due to geo-morphological structuring with pronounced differences in altitude, geology and climate, which give rise to many different habitats (LASSEN and SAVOIA, 2005). They host about 4,500 plant species and an estimated 30,000 animal species. They are considered as one of the most important regions for the preservation of biodiversity in Europe (KOHLER et al., 1990). However, the Alps are also the home and workplace of up to 14 million people and a holiday destination for more than 100 million tourists each year. Anthropogenic land-use changes, urbanisation and the development of transport infrastructure have fragmented the ecological continuum - the connectedness of ecological processes across many scales including trophic relationship and disturbance processes and hydro-ecological flows of the Alps (LINDENMAYER and FISCHER, 2006). Plant and animal populations become increasingly isolated on ever-smaller remnant habitat patches in a human-dominated landscape. Isolation leads to increased vulnerability in the face of stochastic events and decreased genetic diversity.
The red deer (*Cervus elaphus*) is a major game species in the Alpine region and has significant direct and indirect economic importance. The abundance and geographic range of red deer in Europe has increased dramatically in the last decades due to intense management as well as land use changes (COTÉ et al., 2004; MILNER et al., 2006; VICENTE et al., 2007). In contrast to the increase in population numbers, the harvest numbers have not dramatically increased in countries such as Austria and Germany (MILNER et al., 2006). The intense and unilateral management of the red deer population, the lack of natural predators and ecological population regulation as well as the translocation of animals has led to numerous problems related to the overabundance of the species (GORTAZÁR et al., 2006). Beyond contributing towards economic losses in forestry and impacting Alpine ecosystems the over-abundance and changes in spatial use of red deer contributes to the transmission and maintenance of several diseases. Various studies have shown a clear correlation between host density and/or host aggregation and disease prevalence in wildlife populations (ROSSI et al., 2005). Host density and aggregation increase disease transmission rate due to the increase of the contact rate and therefore the disease´s basic reproductive rate ($R_0$) (GORTAZÁR et al., 2006). For bTB a positive correlation between deer density and disease prevalence of bTB has been clearly demonstrated and high host densities is clearly defined as a major risk factor (HICKLING, 2002).

Conservation of the Alpine biodiversity during the past 100 years has been driven by a “protected areas” approach - isolated reserves, separated from the rest of the Alpine space. However, in today's increasingly human-dominated landscapes and in the face of global climate change this approach is being revised. Today conservation efforts aim at preserving and restoring a permeable landscape-matrix where the movement of flora and fauna is not hampered by barriers through the implementation of ecological networks. Conventions, such as the CBD, the Alpine Convention and directives like the “Habitat Directive” (92/43/EEC) and “Water Framework directive” (2000/60/EC), emphasise the importance of the ecological networks. Additionally, numerous EU-funded projects and initiatives (e.g.

Green Infrastructure Initiative) strive to enhance ecological continuity across the Alps and Europe. While landscape-level connectivity clearly benefits biodiversity it inherently facilitates the exchange and movement of pathogens. For example an enhanced continuum from western Austria towards Switzerland will quite possibly accelerate the spread of tuberculosis in wildlife to the west. It appears essential that the notions of potential disease emergence hotspots and pathogen dispersal are firmly integrated into these European programmes and that supra-regional strategies are considered in regional, national disease management programmes. A clear understanding of the interaction of pathogens and enhanced ecological connectivity appears critical to human health and economic well-being in the Alps and beyond.

In order to assess wildlife diseases in the alpine arch, the impact of anthropogenic, environmental and ecological risk factors on a regional and supra-regional scale must be considered. Possible risk factors like: location, densities, habitat types, home range, wildlife management practices including supplemental feeding, host abundance, host ecology, interface and the potential to infect other wildlife species, livestock or humans must be explored and defined. The overbearing socio-economic and socio-political importance of the red deer as a major game species in the Alpine region, the highly fragmented legal structures and the inherent solidly fixated stakeholder conflicts are today a major barrier in the control of tuberculosis and other diseases in the Alpine arch. Disease ecology of bTB and most other wildlife diseases is complex and disease eradication needs to be circumspect and necessarily must include all stakeholders to be effective and sustainable in the long term. In this author's view it is obvious that conservative solutions based in backward-looking explanatory theory are doomed from the onset (BERNSTEIN et al., 2000). The impacts of increasing anthropogenic change are cumulative and thus require interventions today that will constrain our future. This need contradicts predominant policy formulation, which is oriented towards short-term gains and discounts future benefits. Hyperbolic discounting the future is prevalent in our society and a root cause for ineffective measures in alleviating urgent environmental problems, which also include many of the wildlife disease issues.

## References


*BERNSTEIN S, LEBOW RN, STEIN JG, WEBER S (2000): God gave physics the easy problems: adapting social science to an unpredictable world. Eur. J. Int. Relat.* ***6****, 43 - 76.*

*CÔTÉ SD, ROONEY TP, TREMBLAY JP, DUSSAULT C, WALLER DM (2004): Ecological impacts of deer overabundance. Annu. Rev. Ecol. Evol. S.* ***35****, 113 - 147.*

*GORTAZAR C, ACEVEDO P, RUIZ-FONS F, VICENTE J (2006): Disease risks and overabundance of game species. Eur. J. Wildlife Res.* ***52****, 81 - 87.*

*HICKLING GJ (2002): Dynamics of Bovine Tuberculosis in Wild White-tailed Deer in Michigan. Wildlife Division Report No. 3363. Michigan Department of Natural Resources, Lansing, MI. 1 - 36.*

*KOHLER Y, SCHEURER T, ULLRICH A (2009): Ecological networks in the Alpine Arc. Innovative approaches for safeguarding biodiversity. J. Alp. Res.* ***97****, doi: 10.4000/rga.808.*

*LASSEN B, SAVOIA S (2005): European Alpine Programme. Ecoregion Conservation Plan for the Alps, Bellinzona, Switzerland: WWF.*

*LINDENMAYER D, FISCHER J (2006): Habitat fragmentation and landscape change: an ecological and conservation synthesis. Melbourne: CSIRO Publishing.*

*MILNER JM, BONENFANT C, MYSTERUD A, GAILLARD, JM, CSÁNYI S, STENSETH NC (2006): Temporal and spatial development of red deer harvesting in Europe: biological and cultural factors. J. Appl. Ecol.* ***43****, 721 - 734.*

*ROSSI S, FROMONT E, PONTIER D, CRUCIÈRE C, HARS J, BARRAT J, PACHOLEK X, ARTOIS M (2005): Incidence and persistence of classical swine fever in free-ranging wild boar (Sus scrofa). Epidemiol. Infect.* ***133****, 559 - 568.*

*SOULÉ ME, MACKEY BG, RECHER HF, WOINARSKI JC (2006): The role of connectivity in Autralian conservation. In: CROOKS KR, SANJAYAN M (Eds.): Conservation biology 14, connectivity conservation: Cambridge University Press, 649 - 675.*

*VICENTE J, HÖFLE U, GARRIDO JM, FERNÁNDEZ-DE-MERA IG, ACEVEDO P, JUSTE R, BARRAL M, GORTAZAR C (2007): Risk factors associated with the prevalence of tuberculosis-like lesions in fenced wild boar and red deer in south central Spain. Vet. Res.* ***38****, 451 - 464.*

# SUPPLEMENTAL WINTER FEEDING IN HUNTED ROE DEER (*CAPREOLUS CAPREOLUS*): EFFECTS ON FORESTOMACH PH AND MUCOSA HEALTH

CLAUSS M[1], RITZ J[2], HOFER K[3], HOFER E[3], HACKLÄNDER K[4], IMMEKUS D[5], CODRON D[1], POSPISCHIL A[6]

[1]University of Zurich, Vetsuisse Faculty, Clinic for Zoo Animals, Exotic and Wildlife, Winterthurerstrasse 260, 8057 Zurich, SWITZERLAND; mclauss@vetclinics.uzh.ch
[2]University of Zurich, Vetsuisse Faculty, Dept. of Farm Animals, Winterthurerstrasse 260, 8057 Zurich, SWITZERLAND
[3]FAIR HUNT e.U., Wolkersbergenstraße 152, 1130 Vienna, AUSTRIA
[4]University of Natural Resources and Life Sciences, Institute of Wildlife Biology and Game Management, Vienna, Gregor-Mendel-Straße 33, 1180 Vienna, AUSTRIA
[5]Labor für Umweltschutz und chemische Analytik, Riedholz 36, 88167 Maierhöfen Allgäu, GERMANY
[6]University of Zurich, Vetsuisse Faculty, Institute of Veterinary Pathology, Winterthurerstrasse 260, 8057 Zurich, SWITZERLAND

When discussing pros and cons of supplemental feeding of deer, the potential of inducing health problems, in particular rumen acidosis, is frequently mentioned. We compare the pH in the forestomach of 213 free-ranging roe deer (*Capreolus capreolus*) from areas with and without supplemental feeding hunted from hides or by stalking in northern Lower Austria in 2010/2011 from May to October when no, and in November when supplemental feed (a mixture of ensiled apple pomace, sugar beets, oats and other grains) was provided in some but not all districts. Recording the time between death and measurement, pH was measured in contents of the dorsal and ventral sac of the rumen, in the *Atrium ruminis* and the reticulum. Data were analysed with repeated-measurement and hierarchical nested-design ANOVAs. Samples of dorsal, ventral and *Atrium* rumen mucosa were analysed histologically for ten animals each from November without and with supplemental feeding, scoring the severity of inflammation and hyper-/parakeratosis. These data were compared by nonparametric tests. The pH was similar in the dorsal and ventral sac, but lower than in the *Atrium ruminis*, where it was again lower than in the reticulum. This pattern corresponds to expectations based on differences in the presence of saliva at the different compartments of the forestomach. The pH was lower with increasing time that elapsed between death of the animal and measuring pH in unsupplemented animals. Animals with supplemental winter feeding had significantly lower rumen pH than animals without food supplementation, in the same range as summer pH values. Histological findings were generally uniform across the three rumen sampling sites. While inflammation was hardly seen, hyper-/parakeratosis was more pronounced in the supplemented animals, with a significant difference in the severity score. This score was also significantly correlated to the rumen pH. The data suggest that supplemental feeding of roe deer has the potential to lower forestomach pH. Although pH values measured in this study would be considered indicative of rumen acidosis in domestic cattle, they are within the range previously measured in various free-ranging Odocoilid species including roe deer and must be considered with respect to potentially rapid declines in pH between death of the animal and pH measurement. The slight but significant differences in histological scoring indicate that supplemental feeding affects the rumen mucosa, even if only in a putatively chronic way that is unlikely to have direct clinical effects. Adjustments of the supplemental feeding regime such as including higher fibre levels could possibly reduce the differences documented between the groups in this study.

# MORTALITY OF SCIMITAR-HORNED ORYX (*ORYX DAMMAH*) AT ZSL WHIPSNADE ZOO, 1987 - 2011

FLACH E

Zoological Society of London, Veterinary Dept., Whipsnade, Dunstable, Bedfordshire LU7 4SQ UK & Regents Park, London, NW1 4RY, UK; Edmund.Flach@zsl.org

ZSL Whipsnade zoo has held scimitar-horned oryx (*Oryx dammah*) since 1976 and, over 35 years, 56 animals were imported from other zoos, 88 calves were born, 73 animals died and 63 were exported, resulting in a herd of eight at the end of 2011. Due to the incomplete nature of some early necropsy reports, the 25 years from 1987 to 2011 were selected for a review of findings. Sixty oryx died or were euthanised, but unfortunately, an adult male euthanised in 1989, and a juvenile male euthanised in 1991 (both surplus) were not examined. The 58 reports covered gross findings in two foetuses, 15 neonates (0 to 10 days old), 12 juveniles (11 days to 11 months) and 29 adults (one year and above). Histopathological findings were reported in 25 cases (21 of which were adults).

The foetuses were aborted, but no cause could be established. One neonate was markedly under-weight and was potentially a late abortion. Three neonates were newborn and had not yet breathed. In one case there were traumatic lesions compatible with dystocia, but it was not possible to say whether the other two were stillborn or died during parturition. Six of the neonates died within 48 hours of birth and had failed to suck adequately, if at all. In two cases in 1987, recent very wet weather was considered the main cause, while in the others low birth weights, exposure and poor mothering were possibly involved. One calf, which was assist-fed whilst attempts were made to re-integrate it with the mother, died of aspiration pneumonia. Three older neonates also showed poor growth and weight-gain, with one calf affected by the wet weather in 1987. Two neonates died of bacterial infections (listeriosis and an umbilical infection).

The majority (9 of 12) of the juveniles died of bacterial infections, often involving multiple abdominal organs, especially the intestines and associated with micro-abscessation. Yersiniosis (infection with *Yersinia pseudotuberculosis*) was suspected in many cases, but the bacterium was only cultured in two. *Escherichia coli* in pure or predominant growth were isolated from four others. One under-weight 14-day-old calf was euthanised and found to have pneumonic-looking lungs (histology not done), a 5-month-old was euthanised after fracturing its lumbar spine during a catch-up, and no cause of death could be established in the final calf.

Similar multi-centric bacterial infections were found in three 2- and 3-year-old oryx, again with a suspicion of yersiniosis and/or colibacillosis. Three young adults in poor body condition were thought to have copper deficiency and parasitic gastroenteritis, whilst older animals, which had been euthanised due to poor body condition, had a wide variety of pathological findings, including missing or infected teeth, kidney failure, bronchopneumonia, splenitis, chronic arthritis, granulomatous infection and neoplasia. Trauma was the cause of death, or euthanasia, in seven cases, but there was evidence of trauma in many others, often herd members attacking weak or old individuals. Other conditions noted *post mortem* were hoof lesions, including solar necrosis/abscessation, inter-digital gland impaction, adrenal enlargement, abdominal tapeworm cysts, thickened heart valves, fat necrosis and haemorrhage, and abomasitis.

# MORTALITY OF CAPTIVE SAND GAZELLES *GAZELLA MARICA* AT KING KHALID WILDLIFE RESEARCH CENTRE, 1988 - 2011

SOARES JF[1, 2], PEREIRA HA[3], DESTA FS[1,2], SANDOUKA M[1,2], MACASSERO W[1,2]

[1]King Khalid Wildlife Center, Saudi Wildlife Authority, Thumamah P. O. Box 61681, Riyadh, KINGDOM OF SAUDI ARABIA; grec31@yahoo.com
[2]Conservation Projects, Zoological Society of London, Regents Park, NW1 4RY London, UK
[3]Université de Lyon, VetAgro Sup, 69280 Marcy L'Etoile, FRANCE

*Brucella melitensis* appears to be a common disease in domestic ruminants in the Kingdom of Saudi Arabia, but is rarely diagnosed in wild ruminants, especially under remote field conditions. A herd of 16 adult female breeding sand gazelles (*Gazella marica*), kept in three adjacent pens at the Prince Mohammed Al-Sudairi Gazelle Breeding Center (PMSGBC), Qassim, Kingdom of Saudi Arabia, were presented with anorexia, poor body condition and reluctance to walk, generalised lymphadenopathy and both carpal joints enlarged. At necropsy both carpal joints revealed non-suppurative arthritis and hepatomegaly, but no further pathologic changes. Serological investigations used a qualitative card test, a *B. abortus* and *B. melitensis* complement fixation test. Both tests showed positive animals. A polymerase chain reaction was used to test liver, spleen, kidney, ovary, mammary gland, pre-scapular lymph nodes, carpal joint from euthanised animals. Comparison of resulting DNA sequences confirmed *Brucella melitensis*. In addition, sera from sheep and goat farms in the vicinity also tested 33 % serologically positives for *B. melitensis* (card agglutination and complement fixation test), with many showing clinical symptoms compatible with brucellosis, which was assumed to be the origin of this outbreak. This case is noteworthy as it affected a vulnerable species during a reintroduction programme.

Additionally, Sand gazelles mortality was investigated based on pathology records of 1938 captive animals at King Khalid Wildlife Research Center from 1988 through 2011. The largest number of deaths was due to trauma (n = 700; 36 %). Trauma was subdivided in three different categories: self-inflicted (n = 243; 12.5 %); predation (n = 210; 10.8 %) and exhibit mate aggression (n = 247; 12.7 %). Self-inflicted trauma decreased during the study period to near zero in 2011, since over the years appropriate capture techniques have been implemented. Respiratory infection was another major cause of mortality, accounting for 159 (8.2 %) deaths. Respiratory infection was more prevalent during spring (March - May). Other causes of death included gastro-intestinal diseases (n = 108, 5.6 %) and sepsis (n = 146, 7.5 %), such as *Pasteurella multocida*. Maternal neglect (n = 164, 8 %) and euthanasia due to disease management (n = 74, 3.8 %), like tuberculosis (n = 38) and brucellosis (n = 36) were also important causes of mortality. We discuss here the significant of these findings for the improved captive management of this vulnerable Arabian species.

# CYCLOPIA IN ALPACA (*LAMA PACOS*)

RIETSCHEL W

Pferdeklinik in Kirchheim, Nürtinger Straße 200, 73230 Kirchheim/Teck, GERMANY;
rietschelwolf@kabelbw.de

## Summary

Two cases of cyclopia completa are described in a herd of 0.12 alpacas (*Lama pacos*) with reduced fertility. Intake of teratogenic agents during early pregnancy is suspected as possible cause.

## Introduction

About 2700 years ago Homer described the fight of Odysseus with a cyclops, a cannibalistic grumpy giant with one central eye (SCHWAB et al., 2006). In ALDROVANDIS „Monstrorum Historica“ (1667) there is a copperplate print of a cyclops as a full grown man. But in contrary to Homer and Aldrovandi cyclops are nonviable.
Cyclopia is a congenital disorder, quite common in animals and quite rare in humans. Typically, the face is either missing or replaced with a non-functioning nose in the form of a proboscis. Such a proboscis generally appears above the central eye and is characteristic of a form of cyclopia called rhinencephaly or rhinocephaly. Most cyclopia are combined with pathological alterations of eyes, skull and other parts of the body (NIEBERLE et al., 1961). Such embryos are either naturally aborted or are stillborn. In animals, cyclopia is the most common congenital disorder with an incidence of 1:250 embryos, 1:2500 abortions and 1:16000 deliveries. In literature there are various reports of cyclopia in humans, cattle, sheep, goats, cats and in a shark. In zoo veterinary medicine there is one report of cyclopia in a One-horned rhinoceros (Indian rhinoceros, *Rhinoceros unicornis*) from Berlin Zoo (OCHS, 2010). Overdosing of vitamin A during early pregnancy was suspected as a possible cause.
In sheep cyclopia can be caused by ingestion of Corn lilly (*Veratrum californicum*) and other *Liliaceae* (*V. viride*, und *V. japonoicum*) on day 14 of pregnancy. Additionally there might be anophthalmia, cleft palate, shortening of the maxilla, deformities of the legs and arthrogryposis (KEELER et al., 1987). There are reports about cyclopia in horses, cattle, goats and humans induced by cyclopamin, a teratogenic toxin of *V. californicum*. Until recently preparations of Corn lilly had been used as a natural health product against nausea, circulatory insufficiency and convulsions in human medicine. FOWLER (2010) describes cyclopia in South American camelids (SAC) with foetal agenesis of the skull and dysgenesis of other tissues. According to FOWLER (2010) the aethiology of craniofacial birth defects in camelids is unknown. But in the third edition of „Medicine and Surgery of Camelids“, a table includes cyclopia in sheep and SAC after ingestion of teratogen plants (*V. californicum*) on day 14 of gestation. In guinea pigs and rabbits cyclopia might be caused by genetic factors (WIESNER, 1960).

## Case reports

In summer 2012 a herd of 0.12 alpacas showed reproductive disorders. From June 2011 to September 2011 the alpaca mares had been transferred from Stuttgart (Germany) to a pasture on the Swabian Alp (Germany) for mating**.** All animals had been mated by the same proven stallion. In five

animals no pregnancy could be observed, four calves had been born alive and there had been three stillbirths, two of them with a complete cyclopia:
26.05.2012: 0.1 stillbirth in a six year old alpaca mare, mating date 28.06.2011, white colour, length 50 cm, stillbirth with facial and brain deformity, proboscislike nose, central eye, cerebrum of walnut size, shortened maxilla, only one *Nervus opticus*, *Cyclopia completa* (figures 1 to 3). No bacteriological and virological examination of the foetus.
30.05.2012: stillbirth in a 10 year old alpaca mare, mating date 13.06.2011, completely covered in the amniotic sac, length 50 cm, no pathomorphological cause diagnosable.

*Fig. 1: Aborted Alpaca cyclops, female, 11 months old.*

*Fig. 2: Aborted Alpaca cyclops, female, head.*

*Fig. 3: Aborted Alpaca cyclops, female, cranial skeleton.*

**Bacteriology of aborted Alpaca**

| Organ | Method | Parameter | Results | Remarks |
|---|---|---|---|---|
| Placenta | Bacterial cultivation, aerob | Unspecific germs | ++ | |
| Stomach | Bacterial cultivation | Bacteria | negative | |
| Organs | *Salmonella*-enrichment | *Salmonella* sp. | negative | |

**Bacteriology (PCR) of placenta and stomach**

| Organ | Method | Parameter | Results | Remarks |
|---|---|---|---|---|
| Organs | Chlamydia-PCR | Chlamydia | negative | |
| Organs | *Coxiella burnetii* PCR | *C. burnetii* | negative | |

**Virology (PCR) of aborted Alpaca**

| Organ | Method | Parameter | Results | Remarks |
|---|---|---|---|---|
| Brain | Orthobunya-(Schmallenberg virus) virus - PCR | Schmallenberg virus | negative | |
| Spleen | BTV8-VP2-Realtime PCR | BTV-8 | negative | |
| Spleen | Pan-BTV Realtime-PCR | BTV | negative | |

The mare died two weeks later due to anaemia caused by an extreme infestation with endoparasites (*Haemonchus contortus*).
16.07.2012: 0.1 stillbirth in a 7-years old alpaca mare, mating date 10.09.2011. Craniofacial malformation, no maxilla, cerebral agenesis, central eye: *Cyclopia completa* (figure 4).

**Bacteriology of aborted Alpaca**

| Organ | Method | Parameter | Results | Remarks |
|---|---|---|---|---|
| Placenta | Aerob bacterial cultivation | Unspecific germs | ++++ | Due to an overgrowth with environmental / contaminating germs, overgrowth or inhibition of pathogen germs cannot be excluded. |
| Placenta | Microaerophil bacterial cultivation | Campylobacter foetus | negative | |
| Stomach | Aerob bacterial cultivation | *Staph. aureus* | + | |
| Stomach | Microaerophil bacterial cultivation | Campylobacter foetus | negative | |
| Organs | *Salmonella*-enrichment | *Salmonella* sp. | negative | |

**Virology (PCR) of aborted Alpaca**

| Organ | Method | Parameter | Results | Remarks |
|---|---|---|---|---|
| Brain | Orthobunya-(Schmallenberg virus) virus - PCR | Schmallenberg-virus | negative | |


*Fig. 4: Alpaka cyclops, female, 10 months old. (Photo: Chemical and Veterinary Investigatory Office (CVUA) of Stuttgart)*

## Discussion

Although both mares with cyclopic stillbirths had been mated by the same stallion a genetic cause seems to be highly unlikely. The stallion had never been associated with fertility problems and calves with birth defects before. Probably the reduced fertility and the cyclopia in 2012 had been caused by the intake of teratogenic agents during early pregnancy in 2011. Beside plants containing cyclopamin like Germer (*Veratrum album*), a toxic plant, which can be found in Swabian Alp (FROHNE et al., 2004) and local *Liliaceae*, other toxins of plant and non-plant origin might have been involved. Unfortunately due to a pending legal procedure and the death of the holder of the stallion a check up of the location and a plant analysis of the pasture was not possible in 2012 but might be done in 2013.

## Acknowledgement

I thank Dr. Birgit Blaszey, Dr. Christine Süß-Dombrowski and Dr. Ingo Schwabe of the Chemical and Veterinary Diagnostic Laboratory Stuttgart for pathological, bacteriological and virological diagnostics.

## References

*ALDROVANDI U (1667): Monstrorum historica cum paralipomenis historiae omnium animalium. Bologna.*

*FOWLER M (2010): Medicine and Surgery of Camelids. Wiley-Blackwell.*

*FROHNE D, PFÄNDER HJ ( 2004): Giftpflanzen. Ein Handbuch für Apotheker, Ärzte, Toxikologen und Biologen. Wissenschaftliche Verlagsgesellschaft mbH Stuttgart.*

*KEELER RF, STUART LD (1987): The nature of congenital limb defects induced in lambs by maternal ingestion of Veratrum californicum. Clin. Toxicol.* ***25****, 273 - 286:*

*NIEBERLE K, COHRS P (1961): Lehrbuch der speziellen pathologischen Anatomie der Haustiere. VEB Gustav Fischer Verlag Jena.*

*OCHS A (2010): First description of cyclopia in an Indian rhinoceros (Rhinoceros unicornis) at Berlin Zoo. Proc. Int. Conf. Zoo Wild Anim., 242 - 244.*

*SCHWAB G (Ed.), GUGGENMOOS J (2006): Die schönsten Sagen des klassischen Altertums. (1838 - 1848). Ravensburger Buchverlag, Ravensburg.*

*WIESNER E (1960): Die Erbschäden der landwirtschaftlichen Nutztiere. VEB Gustav Fischer Verlag Jena.*

# EVOLUTION OF T-REGULATORY CELL MEDIATED FOETAL-TOLERANCE IN MAMMALS

BUENTJEN I[1], DREWS B[1], RENFREE MB[2], ROELLIG K[1], MENZIES BR[2]

[1]Leibniz Institute for Zoo and Wildlife Research (IZW), Alfred-Kowalke-Str. 17, 10315 Berlin, GERMANY; buentjen@izw-berlin.de
[2]The University of Melbourne, Dept. of Zoology, Melbourne, Victoria 3010, AUSTRALIA

The therian semi-allograft foetus must avoid rejection by the maternal immune system. T-regulatory cells ($T_{REG}$), a specific subset of T-cells that suppress immune responses and promote self-immune tolerance, have been shown to suppress the action of natural killer cells in mice and humans (ZENCLUSSEN et al., 2005). The forkhead box protein 3 (FOXP3) gene is necessary to upregulate and expand the active $T_{REG}$ pool. However, a 'c-Rel' binding motif within the non-coding 5' region of FOXP3 that is critical for thymic $T_{REG}$ expansion is not conserved in marsupials and non-mammalian vertebrates (ZHENG et al., 2010). Thus, $T_{REG}$ may not be required for successful pregnancy in marsupials.

To understand the evolution and molecular conservation of $T_{REG}$-mediated foetal-tolerance, we sequenced FOXP3 from cDNA in a marsupial, the tammar wallaby (*Macropus eugenii*). Lymphocytes of the systemic blood from 18 pregnant and 2 non-pregnant tammars did not express RNA of FOXP3 but in RNA pools from other tissues including adrenal and thymus it was highly expressed. Phylogenetic comparison of vertebrate FOXP3-sequences also showed differential evolution of this regulatory domain. These results suggest that $T_{REG}$-induced foetal-tolerance may be a unique adaptation of eutherian mammals to support longer pregnancies or more invasive placentation.

## References

*Zenclussen AC, Gerlof K, Zenclussen ML, Sollwedel A, Bertoja AZ, Ritter T, Kotsch K, Leber J, Volk HD (2005): Abnormal T-Cell Reactivity against Paternal Antigens in Spontaneous Abortion: Adoptive Transfer of Pregnancy-Induced CD4+CD25+ T Regulatory Cells Prevents Fetal Rejection in a Murine Abortion Model. Am. J. Pathol.* ***166****, 811 - 822.*

*Zheng Y, Josefowicz S, Chaudhry A, Peng XP, Korbush K, Rudensky AY (2010): Role of conserved non-coding DNA elements in the Foxp3 gene in regulatory T-cell fate. Nature* ***463****, 808 - 812.*

# USE OF AVIAN RECOMBINANT GONADOTROPIN FOR GONADAL STIMULATION IN LOGGERHEAD SEA TURTLES (*CARETTA CARETTA*)

CRESPO-PICAZO JL[1,2], GARCÍA-PARRAGA D[1,2], GIMENEZ I[3], ALVARO T[1], VALLS M[1], CORPA JM[4], ORTEGA J[4], SÁNCHEZ-VIZCAÍNO JM[2]

[1]Veterinary Services, Oceanogràfic, Ciudad de las Artes y las Ciencias, C/ Eduardo Primo Yúfera (Científic), 46013 Valencia, SPAIN; jlcrespo@sanidadanimal.info

[2]Complutense University of Madrid, Veterinary School, VISAVET Center and Animal Health Dept., Avda Puerta del Hierro, 28040 Madrid, SPAIN

[3]Rara Avis Biotec, C/ Moratin 17, 46002 Valencia, SPAIN

[4]Universidad CEU Cardenal Herrera, Biomedical Sciences Research Institute, Histología y Anatomía Patológica, Facultad de Veterinaria, 46113 Moncada, Valencia, SPAIN

In order to evaluate the effectiveness of recombinant follicle-stimulant hormone (FSH) for the potential use in breeding and conservation programmes, experimental injection of avian gonadotropin was carried out in a group of loggerhead sea turtles (*Caretta caretta*) from the rehabilitation centre of the Oceanographic of Valencia. Complete health assessment was performed before, during and after the treatment, including whole physical examination, blood work (haematology, biochemistry and hormone determination), ultrasound examination of the coelomic cavity and behavioural observations.

Nine sea turtles were included as a part of the preliminary study. In one experiment a female adult unreleasable loggerhead sea turtle was regularly treated every forty-eight hours during eight months with FSH in an attempt to stimulate folliculogenesis. In a second experiment eight juveniles' loggerheads received a single dosage of FSH in order to evaluate the hormone response for sex determination.

Effects on the gonads of the adult sea turtle were assessed measuring serum concentrations of estradiol and triglycerides (among other determinations) and by evaluating follicle development by ultrasound examination. Those determinations allow us to monitor the normal reproductive cycle including the ovulation phase.

On the juvenile group, intramuscular injection of FSH induced a rise oestrogen and androgen levels 24 h post injection, as compared to baseline serum hormone levels. These preliminary results point out an alternative technique for gender determination in young sea turtles. No detrimental effects were observed in any of the turtles treated with gonadotropins.

Based on the presented results, we consider that using recombinant gonadotropins in sea turtles through stimulation of reproduction and gender determination in young sea turtles, could serve as useful additional tool to be considered in the present conservation programmes.

# A CASE OF DYSTOCIA IN AN AFRICAN ELEPHANT (*LOXODONTA AFRICANA*)

BLANC B[1], MULOT B[1], HILDEBRANDT T[2], GÖRITZ F[2], POTIER R[1]

[1]Zooparc Beauval, Nationale 25, 41110 Saint Aignan-Sur-Cher, FRANCE; barbarablanc85@hotmail.fr
[2]Leibniz Institute for Zoo and Wildlife Research (IZW), Alfred-Kowalke-Straße 17, 10315 Berlin, GERMANY

A 23-years-old nulliparous female African elephant (*Loxodonta africana*) was successfully inseminated with fresh semen. Husbandry and training protocol were adjusted to allow a close monitoring of the resulting pregnancy.

After 22 months of pregnancy, a 50 % drop in progesterone level was observed as a first indication of the upcoming birth. Subsequently, modification of the genital tract, size and position of the foetus were monitored with daily ultrasound exam. Mucous plug morphological changes as well as cervix opening and foetal progression into the vagina were first noticed on ultrasound exam three days after progesterone drop. Although the foetus was well-positioned and the size seemed to be optimal, the mother exhibited only mild signs of labour. Four days after the progesterone drop, mucoïd vaginal discharge was observed for three consecutive days. The repeated ultrasound examinations did not seem to induce additional labour in the female. One week after the progesterone drop, a single observation of the bulge in the perineum was noticed, but no followed by a true labour activity. Eight days after the progesterone drop, Ferguson's reflex was first initiated with transrectal cervix massage and led to a rupture of the foetal membranes. However position of the foetus in the birth canal remained the same and no further sign of labour were observed in the mother. Lumps of membrane were partially expelled. This languid parturition began to affect the general condition of the animal. Ten days after the progesterone drop, a systemic medical treatment was established based on broad-spectrum antibiotic, steroidal anti-inflammatory, and transrectal rehydration. Although Calcium blood values were within normal limits throughout the pregnancy and at the time of birth, supplemental Calcium was administered intravenously ten days after the progesterone drop. Transrectal cervical massages were repeated after oestrogens gel application on the pelvic area in order to soften tissues around the birth channel. All medical treatments failed 12 days after the progesterone drop and the female died before a vestibulotomy attempt could be undertaken. The necropsy revealed a foetus fully developed with no abnormalities and a septicaemia secondary to a metro-peritonitis. Bacterial analysis was in agreement with an ascending infection due to dystocia.

Reasons, which led to this fatal outcome, remain unclear. Risks of dystocia are notoriously high among old nulliparous African elephant. However this female was elected for artificial insemination after a thorough assessment of her clinical condition, which included an ultrasound exam of her genital tract. Behavioural factors, as tolerance to pain or general demeanour of the specimen cannot be excluded as aggravating factors in this case of dystocia.

# POSTPARTUM DISEASES IN STRIPED SKUNKS (*MEPHITIS MEPHITIS*): TWO CASE REPORTS AND COMPARATIVE REVIEW OF THE LITERATURE

D'OVIDIO D[1], NOVIELLO E[1], MEOMARTINO L[2]

[1]Parco delle Maitine, Via Fontana dell'Occhio 1, 82020, Pesco Sannita, BN, ITALY; dariodovidio@yahoo.it
[2]University of Naples Federico II, School of Veterinary Medicine, Veterinary Radiology Centre, Via F. Delpino 1, 80137 Naples, ITALY

Two unreported postpartum diseases in striped skunks (*Mephitis mephitis*) are described. A partial uterine prolapse occurred in a 2-years-old striped skunk after recent parturition of five healthy puppies. The prolapse occurred after a normal pregnancy and natural delivery. Two days elapsed between the uterine prolapse and presentation. During these two days the prolapsed uterine horn was mechanically damaged and became partially necrotic. A complete blood count and serum biochemical analysis showed leucocytosis and mild hypocalcemia. Supportive care, a prophylactic antibiotic, analgesic drugs, calcium gluconate and vitamin D3 were started before surgery and were continued during the following days. A case of endometritis occurred in a 4-years-old striped skunk after a prolonged delivery of four kits. The whelping had been prolonged and an undetermined amount of time elapsed between the expulsion of the third and the last kit. A foul-smelling vaginal discharge was evident from the dam. Abdominal ultrasound showed enlarged uterine horns filled with intraluminal fluid. A vaginal swab, collected for cytological examination as well as for culture and sensitivity, showed the presence of degenerate neutrophils and macrophages and isolation of *Staphylococcus* spp. bacteria respectively. Intravenous fluid therapy as well as a broadspectrum antibiotic were promptly started at presentation and continued during the following days. Similar clinical signs were observed in both animals including depression, lethargy, inappetence, poor lactation and neglect of offspring. After stabilisation of the patients an ovariohysterectomy was performed in both cases. Both the animals survived the surgery and no complications were noticed on the following rechecks.

# BLAST INJURY AND SEA TURTLES

AIZENBERG I[1,3], KING R[2], GRUNDLAND Y[3], LEVI Y[3]

[1]Hebrew University of Jerusalem, Koret School of Veterinary Medicine, Veterinary Teaching Hospital, P.O. Box 12, Rehovot 76100, ISRAEL; aizenber@agri.huji.ac.ili
[2]Israel Nature and Park Authority, 3 Adam Veolamo St., Jerusalem 95463, ISRAEL
[3]The Sea Turtle Rescue Center, Nature & Parks Authority. Mevoot Yam, P.O. Box 1174, Mikhmoret 40297, ISRAEL

## Summary

Underwater blast injury is one of many threats on sea turtles population. During December 2012 and January 2013 eight turtles were found along the sea shore of Israel in different locations with signs resembling unconsciousness. Clinical investigations included physical examination, blood tests and computed tomography (CT) scanning revealed lesions similar to those described in human as a result of blast injuries. The findings included pulmonary haemorrhage, middle ear fluid collection and elevated creatine kinase. For the best of our knowledge this is the first report of blast injury CT findings in alive turtles.

## Introduction

Sea turtles (seven species) are under many threats like fisheries by-catch, pollution, ecosystem alterations, traumas, diseases, constructions and more (BOLTEN et al., 2010). Underwater blast injuries are one of those risks to sea turtles as for other aquatic animals.
Underwater blasting is conducted for a number of uses like rock excavation, grade preparation for foundations, structural rehabilitation, waterway applications, geophysical exploration, fish sampling, military operations, and other uses. Shock-wave pressures in column from explosions can have adverse impacts on nearby submerged structures and on aquatic life (KEEVIN and HEMPEN, 1997).
Most of the reports on blast injuries in sea turtles are post mortem reports with comparison to lesions in human beings. For the best of our knowledge this is the first report on live turtles that underwent blast injury including computed tomography images.

## Case History

During December 2012 and January 2013, eight turtles (seven loggerhead turtles and one green turtle) were found along the seashore in different locations. Opening their mouth for breathing every few minutes was the only sign for being alive. On physical examination there were almost no reflexes. There was no sign for drowning or severe hypothermia. Bloody secretions were observed in one turtle during expiration. Blood results showed no anaemia, normal to high glucose but elevated CK. Following initial treatment, they were scanned by a dual slice helical CT (CT-Twin Flash, Elscint, ISRAEL) in the Veterinary Teaching Hospital.
Pulmonary infiltration was observed in all turtles representing pulmonary haemorrhage with different severity. Emphysematotic bullae was observed in one case. Middle ears with different amount of fluids were observed in those turtles. Free coelomic fluid was found as well.

The turtles got supportive treatment including heating, fluid therapy antibiotics and forced feeding. Unfortunately two turtles died after a few days. Those individual had the most severe pulmonary findings.
Post mortem findings included pulmonary haemorrhage with bleeding and necrotic tissue in the main bronchi. Free coelomic blood with blood clot was found in one as well as pericardial effusion. In the green turtles there was fibrin clots in the CSF.

## Conclusion

Very little information exists regarding the impacts of underwater explosions on sea turtles. These effects of explosions on turtles often must be inferred from documented effects to other vertebrates, including humans, marine mammals, and fish with lungs or other gas-containing organs. However, impacts to these other vertebrates may not be reliably extrapolated to sea turtles (VIADA et al., 2008). Potential impacts to sea turtles are categorised as non-injurious and injurious effects. Injury resulting from PBI is almost totally limited to gas-containing organs. For sea turtles, this would be primarily the auditory system and lungs (GERACI and ST. AUBIN, 1985). Severe injuries, even if not fatal, would probably put the animal at increased risk of predation, secondary infection, or disease.
In our collection of cases we found pulmonary haemorrhage in all of the turtles with fluid fill tympanic bullae in most of the turtles. Although computed tomography is not as sensitive as MRI in detection of brain lesion, we suspect that brain injuries are also a serious result in the case of underwater explosions in sea turtles.

## References

*BOLTEN AB, CROWDER LB, DODD MG, MACPHERSON SL, MUSICK JA, SCHROEDER BA, WITHERINGTON BE, LONG KJ, SNOVER ML (2010): Quantifying multiple threats to endangered species: an example from loggerhead sea turtles. Front. Ecol. Environ.* ***9****, 295 - 301.*

*GERACI JR, ST. AUBIN DJ (1985): Effects of offshore oil and gas development on marine mammals and turtles. In: BOESCH DF, RABALAIS NN (Eds.): The long-term effects of offshore oil and gas development: an assessment and a research strategy. Rockville, MD: National Marine Pollution Office, National Oceanic and Atmospheric Administration, 121 - 1234.*

*KEEVIN TM, HEMPEN GL (1997): The Environmental Effects of Underwater Explosions With Methods to Mitigate Impacts. U.S. Army Corps of Engineers, St. Louis District, 1222 Spruce Street, St. Louis, Missouri, 63103 - 2833.*

*VIADA ST, HAMMER RM, RACCA R, HANNAY D, THOMPSON MJ, BALCOM BJ, PHILLIPS NW (2008): Review of potential impacts to sea turtles from underwater explosive removal of offshore structures. Environ. Impact Assess.* ***28****, 267 - 285.*

# SILVER-IMPREGNATED HYDROFIBER® DRESSING (AQUACEL Ag®) USE IN COMPLICATED WOUNDS IN ZOO ANIMALS

ALMAGRO V, HUZMAN M, FERNÁNDEZ-BELLON H

Parc Zoològic de Barcelona, Ciudadela s/n 08003 Barcelona, SPAIN; valmagro@bsmsa.cat

## Summary

Wounds and soft tissue abscesses are common problems in zoo animals. Despite veterinary care is not always required; intervention may be warranted if infection becomes rampant. However, these cases can prove to be challenging, as intensive treatment of wounds is not always feasible in zoo animals, or it may be counterproductive.
We have used silver-impregnated Hydrofiber (Aquacel Ag®, Convatec Ltd. Skillman,NJ 08558 USA) dressings to treat wounds or abscesses, providing satisfactory local therapy while eliminating the need for intensive nursing. Here we present cases of this treatment in traumatic wounds in a Galápagos giant tortoise (*Chelonoidis nigra*), dental abscess in a red kangaroo (*Macropus rufus*), and an abscess in a Barbary sheep (*Ammotragus lervia*).

## Introduction

One of the most common veterinary problems in captive wildlife populations are wounds or abscesses in soft tissues. These lesions do not always require veterinary intervention, but complicated wounds or soft tissue abscesses can require repeated (i.e. daily) treatments. Such intensive care is undesirable in wildlife medicine because it requires physical or chemical immobilisation, jeopardising the healing process and animal welfare.
In an attempt to minimise need for capturing and manipulating animals for treating wounds and soft tissue infection, we have introduced the use of a silver-impregnated Hydrofiber® dressing (Aquacel Ag®, Convatec Ltd Skillman, NJ 08558, USA) (COUTTS and SIBBALD, 2005). These dressings provide a sustained anti-microbial environment, and aid the removal of non-viable tissue from the wound (autolytic debridement), supporting the healing process.

**Case 1**
A male 6-years-old red kangaroo was treated for molar root infection. This is a common and challenging disease for which no single therapeutic approach has proven entirely successful.
The kangaroo was presented with a mild weight loss. On inspection under general anaesthesia, the first upper right molar was found to be infected. Extraction revealed an incipient abscess. Routine cleansing was followed by packing with Aquacel Ag® drenched in gentamycin (Gentasol-80®, LABIANA Life Sciences S.A. C/Venus, 26 08228 Terrasa, Spain), and kept in place with stitches. Systemic antibiotic (Amoxicillin LA 525 mg IM TD q 48 h Amoxoil retard®, Laboratorios Syva S.A. 24010 León, Spain), topical gentamycin and analgesic (Meloxicam 15 mg IM TD once a week (Meloxidyl® Ceva Santé Animale 33500 Libourne France), Buprenorphine 0.9 mg IM TD once a week (Buprex®, RB Pharmaceuticals Limited, Berkshire SL1 3UH, UK) treatments were administered. Analgesic treatment was done once a week only after surgical procedure, daily oral analgesia was not required as the animal was eating without problems. After three weekly applications of this treatment under general anaesthesia, complete healing was observed on the fourth week. After 16 months, recurrence has still not been observed.

**Case 2**

A 7-years-old female Barbary sheep was presented with unthriftiness. The animal was examined under general anaesthesia. Inspection showed two encapsulated abscesses caudal to the right angle of the mandible. The lesser abscess drained through a fistulous tract whereas the larger abscess was completely encapsulated. In our experience, these kinds of lesions are traumatic in origin, usually by goring and will chronify unless treated aggressively. Blood tests showed severe anaemia (18 % PCV). Both abscesses were surgically drained, and after standard cleansing and disinfection, the surgical wounds were packed with gentamycin-drenched Aquacel Ag®. This was replaced under physical immobilisation twice weekly following conservative wound cleansing. Systemic antibiotic therapy (depot oxytetracycline, 1500 mg IM TD once a week Solmycin®, 300 Norbrook Laboratories Newry, Ireland) was provided for two weeks. Within three weeks the wounds had resolved satisfactorily, the haematocrit increased (32.2 %) and the treatment was suspended.

**Case 3**

A 70 kg 9-years-old Galápagos giant tortoise was presented with injuries by another tortoise, resulting in two penetrating wounds on either side of the neck. The severity of the wounds prevented extension of the neck, and the animal was anorectic. An initial treatment regime with systemic antibiotic (Ceftazidime 800 mg IM TD q72 h Ceftacidima Normon®, Laboratorios Normon S.A. 28160 Madrid, Spain) and anti-inflammatory (Meloxicam 8 mg IM TD q72h Meloxidyl®, Ceva Santé Animale, 33500 Libourne, France) therapy coupled with daily debridement and dressing of the wounds produced almost no improvement after one month. The treatment regimen was changed to wound conservative cleansing of the wounds, followed by packing with Aquacel Ag® drenched in gentamycin twice a week. Voluntary feeding resumed after this change in regime, and the wounds steadily improved over the following five months. At the time of writing, weekly dressings are still applied to a remaining area of healing.

## Discussion

The use Aquacel Ag® substantially reduced the need for frequent treatments, while allowing satisfactory healing of otherwise challenging infected lesions. This dressing helps keep microbial overgrowth under control for several days. It also aids the removal of dead tissue, supporting the healing process, and eliminating the need for aggressive debridement. These characteristics make it very adequate for managing infected lesions in wildlife. Stress due to immobilisation, manipulation, and social disruption severely limits the efficacy of more aggressive and intensive treatment regimes (drainages, daily treatments).

## Reference

*COUTTS P, SIBBALD RG (2005): The effect of a silver-containing Hydrofiber® dressing on superficial wound bed and bacterial balance of chronic wounds. International Wound Journal **2**, 348 - 356.*

# T-CELL LYMPHOMA IN A LEOPARD TORTOISE (*STIGMOCHELYS PARDALIS*) – A CASE REPORT

ARIF A[1], HEBEL C[1], SCHMIDT V[2], SCHILP C[1], BOUTS T[1]

[1]Al Wabra Wildlife Preservation, P.O. Box 44069 Doha, STATE OF QATAR; aarif@alwabra.com
[2]University of Leipzig, Clinic for Birds and Reptiles, An den Tierkliniken 17, 04103 Leipzig, GERMANY

A 6-years-old female Leopard tortoise (*Stigmochelys pardalis*) was presented at the Al Wabra Wildlife Preservation (AWWP) hospital in Qatar with a soft swelling of the eyelid surrounding the complete right eye, as well as the surrounding skin. Behaviour and appetite were normal. As an infected ant-bite was suspected an initial treatment with topical and systemic antibiotics and anti-inflammatory drugs was initiated without clinical improvement. Further examinations under anaesthesia excluded involvement of the eyeball, and no abscess or foreign body could be detected. Blood results revealed lymphocytosis and increased GGT and LDH values. The treatment was changed to topical dexamethasone-gentamycin eye ointment without any improvement.

During a second diagnostic procedure a biopsy of the conjunctiva was taken. Histopathology results revealed marked infiltration of pleomorphic neoplastic lymphocytes. The neoplastic cells had round to oval hypochromatic nuclei with numerous nucleoli, small to moderate amounts of cytoplasm and distinct cell borders. Single mitotic figures and single apoptotic cells were present. T-cell lymphoma was diagnosed by detection of CD 3 antigen. CD 45 and CD 79 antigens were not detected.

Due to the bad prognosis the tortoise was euthanised. On gross pathology the liver revealed white patches in the parenchyma and the spleen and colon were surrounded by white hard tissue with nodules of different size. Virologic examinations with PCR and cell culture were negative. Histopathologic and immunohistopathologic examinations of lesions in liver, spleen and intestine confirmed multiple malignant multicentric T-cell lymphomas in these organs.

# SOCIAL DEPRIVATION ASSOCIATED WITH REDUCED TELOMERE LENGTH IN AFRICAN GREY PARROTS (*PSITTACUS ERITHACUS ERITHACUS*)

AYDINONAT D[1], PENN DJ[2], MOODLEY Y[2], HOELZL F[3], SCHWARZENBERGER F[1]

[1]University of Veterinary Medicine, Institute of Medical Biochemistry, Dept. of Biomedical Sciences, Veterinärplatz 1, 1210 Vienna, AUSTRIA;
Denise.Aydinonat@vetmeduni.ac.at; Franz.Schwarzenberger@vetmeduni.ac.at

[2]University of Veterinary Medicine, Konrad Lorenz Institute of Ethology, Dept. of Integrative Biology and Evolution, Savoyenstraße 1a, 1160 Vienna, AUSTRIA

[3]University of Veterinary Medicine, Research Institute of Wildlife Ecology, Dept. of Integrative Biology and Evolution, Savoyenstraße 1a, 1160 Vienna, AUSTRIA

Telomeres, the protective caps of eukaryotic chromosomes, usually shorten at each cell division due to the “end-replication problem” of linear DNA, and once a critical telomere length (TL) is reached, cells enter replicative senescence. Telomere shortening is associated with ageing, and some studies suggest that it is exacerbated by chronic physiological and psychological stress (e.g., oxidative stress may impair telomerase-mediated repair). In this study we tested whether social isolation is associated with telomere shortening in African Grey parrots. These birds are highly intelligent and are one of the most popular parrots in animal husbandry, and though they are highly social, they are often kept solitary in captivity. We collected blood for DNA extraction from 55 pet birds whose ages varied from 2 to 45 years during check-ups in a Small Animal Clinic. Only individuals with known ages and living in single or pair housing from the beginning of animal husbandry were included. Relative telomere length was measured by quantitative PCR assay. Sex was determined by standard PCR protocol. As predicted, TLs were shorter in older than younger birds and we found significant differences in TL between single-housed versus pair-housed birds (GLM, $p < 0.001$): single-housed birds had significantly shorter telomeres on average compared to pair-housed birds of the same age. We found no evidence for sex-dependant telomere shortening, however. Our results indicate that most telomere shortening occurs in the first five to ten years of life, suggesting that an intact social environment in early life influences later health and cellular ageing.

# LONG-TERM HEALTH MONITORING IN AN ALPINE UNGULATE POPULATION

BEIGLBÖCK C, KÜBBER-HEISS A, WALZER C

University of Veterinary Medicine Vienna, Research Institute of Wildlife Ecology, Dept. of Integrative Biology and Evolution, Savoyenstraße 1, 1160 Vienna, AUSTRIA; christoph.beiglboeck@fiwi.at

Long-term monitoring of wildlife health is an important instrument in both veterinary and ecological research. Occurrence of disease and its underlying ecology in wildlife is often elusive and the lack of long-term observations hampers systematic research.

In 2001, a longitudinal monitoring programme was initiated in the Carinthian part of the national park Hohe Tauern, Austria, focussing on the health status of the local ungulate population (estimated population size: Red deer (*Cervus elaphus*) 1000, chamois (*Rupicapra rupicapra)* 3000, alpine ibex (*Capra ibex*) 300). Here we present the results obtained between the years 2006 and 2008. In total, 745 organ samples from 86 representative individuals shot during routine hunting were harvested by trained park wardens and submitted in 4 % neutral buffered formalin for histopathological investigations. Samples originated from 14 red deer, 58 chamois and 14 alpine ibex. The samples included heart, lung, liver, spleen, kidney, rumen, small and large intestine, testes/uterus, mammary gland and skin. Sex, age, date and exact location of harvest were documented on standardised protocols. Obvious macroscopic lesions were recorded during gutting by specially trained park wardens. Samples were embedded in paraffin wax, and sections (4 µm) were stained with haematoxylin and eosin followed by a thorough histopathological examination.

Our main findings were lesions in the lungs and intestines due to various parasites. Eggs and larvae of lungworms were present in lung tissues in 38 % of chamois and 21 % each in red deer and ibex. The associated pathological lesions were manifold and ranged from hypertrophy of the bronchial musculature to diffuse or focal, mostly non suppurative, inflammation. Non-purulent enteritis was observed in 19 % of chamois, 21 % of red deer and 14 % of ibex, supposedly caused by intestinal parasites. Sarcoptic mange, an often fatal disease in chamois, was found in only two individuals in mild form. In the heart muscle, we observed *Sarcosporidia* cysts in chamois (69 %), red deer (36 %) and ibex (29 %), although no pathological reaction was detected.

Histopathological investigations are well suited to detect viral and bacteriological diseases, hence no serological or microbiological tests were performed. In case of suspicious histopathological samples, supplementary sampling can easily be implemented since long-term monitoring regimes enhances awareness of all people involved in the respective investigations.

The results of our histopathological investigations corresponded well with the findings of a previous study in the same area (HOBY et al., 2006). We conclude that the health status of the ungulate population in Hohe Tauern national park is similar to other wild populations and that the animals are able to react appropriately to ubiquitous pathogens such as lungworms. Gaining this long-term, baseline information may become crucial in case of new or reoccurring pathogens.

## Reference

*HOBY S, WALZER C, SLOTTA-BACHMAYR L, SEGNER H, ROBERT N (2006): Untersuchungen zur Pathologie von Wildungulaten im Nationalpark Hohe Tauern, Österreich. Wiener Tierärztliche Monatsschrift* ***93****, 104 – 112.*

## HELMINTHOFAUNA OF MAMMALS HOSTED IN GARDA ZOOLOGICAL PARK

BERALDO P[1], TREVISAN S[1], MAGNONE W[2], SANDRI C[2], CODOLO R[1], PASCOTTO E[1]

[1]University of Udine, DIAL-Division of Veterinary Pathology, via Sondrio 2, 33100 Udine, ITALY; paola.beraldo@uniud.it
[2]Parco Natura Viva - Garda Zoological Park, Loc. Figara, 40, 37012 Bussolengo (VR), ITALY

The helminthofauna identification is important to increase the scientific knowledge about the relationship host/parasite in captivity, to define any pathological complications and to provide appropriate therapy protocols, so that appropriate measures can be taken for health management (PEREC-MATYSIAK et al., 2007; LIM et al., 2008; AJIBADE et al., 2010). The diagnostic-scientific collaboration between the staff of the Division of Veterinary Pathology (DIAL) of the University of Udine and veterinarians of the Garda Zoological Park of Bussolengo (VR) allowed this parasitological survey, the aim of which was to identify the helminthofauna of some dead mammals, which were necropsied to determine the cause of death. The investigated host population was composed of 13 animals (between 2006 and 2011), belonging to the order Carnivora (*Panthera tigris, Puma concolor, Nasua nasua, Ailurus fulgens*), Artiodactyla (*Cervicapra antelope, Kobus leche, Potamochoerus porcus*) and Primates (*Macaca sylvanus, Lemur catta, Eulemur macaco macaco, Eulemur albifrons*). After *post-mortem* examination, procedure for Total Worm Count (MAFF, 1986) was performed on gastro-intestinal tracts and in some cases also on lungs. Samples of two animals (Barbary macaque and black macaco) came to the laboratory fixed in 4 % buffered formaldehyde. The parasitological survey revealed that 8 out of 13 animals were parasitised by nematodes in the gastro-intestinal tract and in the lung. In particular, nine species of gastrointestinal nematodes and three species in the lungs were identified: *Camelostrongylus mentulatus, Teladorsagia circumcincta* in *C. antilope* and *K. leche*; *Nematodirus spathiger, Trichostrongylus colubriformis Trichuris cervicapra* in *C. antilope*; *Ascaris sum* in *P. porcus*; *Eucoleus aerophilus, Crenosoma striatum* and unidentified species belonging to the superfamily Metastrongyloidea in lung and *Aonchotheca putorii* in the gut of *A. fulgens*; *Trichuris trichiura* in *M. sylvanus*; *Physaloptera sibirica* in the two lemurs and *Physaloptera* sp. in tiger. The parasitological adopted approach has allowed us to calculate the reliable worm burden of the host and to identify helminthofauna. The survey has highlighted a new species of parasite and record the presence of known species (such as *C. mentulatus*) in new hosts (*Kobus leche*).

## References

*AJIBADE WA, ADEYEMO OK, AGBEDE SA (2010): Coprological survey and inventory of animals at Obafemi Awolowo, and University of Ibadan Zoological Gardens. World Journal of Zoology **5**, 266 - 271.*

*LIM YAL, NGUIA R, SHUKRIA J, ROHLEAA M, MATNAIMB HR (2008): Intestinal parasites in various animals at a zoo in Malaysia. Vet. Parasitol. **157**, 154 - 159.*

*MINISTRY OF AGRICULTURE, FISHERIES AND FOOD. Manual of veterinary parasitological laboratory techniques. London: Her Majesty's Stationery Office, 1986.*

*PEREC−MATYSIAK A, OKULEWICZ A, HILDEBRAND J, ZALEŚNY G (2007): Helminth parasites of mammals in zoological gardens. Wiadomooeci Parazytologiczne **53**, 15 - 20.*

# CAN INTRAVENOUS BUTORPHANOL IMPROVE THE SAFETY OF ANAESTHETIC PROCEDURES IN WHITE RHINOCEROSES?

BOARDMAN W[1], VAN ZIJLL LANGHOUT MH[2], RAATH JP[2]

[1]University of Adelaide, School of Animal and Veterinary Sciences, Roseworthy, Adelaide, AUSTRALIA; wayne.boardman@adelaide.edu.au
[2]WildlifeVets, P.O. Box 90, Karino, REPUBLIC OF SOUTH AFRICA

White rhinoceros (*Ceratotherium simum*) are the subject of widespread poaching particularly in South Africa. In 2012, over 600 animals were poached in South Africa alone. One particular procedure aimed at preventing poaching is to dehorn the animals on a regular basis. This technique is not without controversy and safety issues. At present most animals undergo an anaesthetic procedure so that dehorning can be performed. This is usually done every three years but can be done on males as frequently as yearly.

Anaesthesia of free ranging white rhinoceros has met with many challenges over the years. Sedation and anaesthesia are complicated by the large size of all rhinoceros species and their sensitivity to potent opioids. Potential complications include respiratory depression, hypoxaemia, hypertension, pulmonary shunting and ventilation/perfusion mismatch. White rhinoceros anaesthetised with etorphine and azaperone combination develop adverse physiological changes including hypoxia, hypercapnia, acidosis, tachycardia and hypertension. As a consequence a safe and reliable anaesthesia of rhinoceros is an important tool for health care of both captive and free-ranging animals and for conservation-based programmes.

Many combinations of anaesthetic agents have been used in free ranging white rhinoceroses based on the potent opioid etorphine because it can be concentrated into a small volume, induces immobilisation quickly and can be completely reversed using naltrexone. However in all combinations using etorphine the undesirable respiratory depressant effects associated with the mu receptor has led to concerns on the safety of the drug combinations. Oxygen insufflation improved ventilation on recumbent white rhinoceroses but this has the disadvantage of how to provide oxygen in field conditions.

Butorphanol tartrate (50 mg/ml, Butonil®, Wildlife Pharmaceuticals, South Africa) has been used alone or in combination with azaperone to sedate or anaesthetise rhinoceros species. It acts as a kappa-receptor agonist and mu-receptor antagonist. One of its major advantages as an anaesthetic agent is its minimal respiratory and cardiovascular side effects and can be used in theory to reverse the undesirable mu effects of etorphine. However, butorphanol administered intramuscularly in combination with etorphine, detomidine and azaperone to anaesthetise white rhinoceroses provided no benefits to ventilation.

This presentation provides a brief overview of the dehorning procedure and provides preliminary data on the effect of intravenous butorphanol tartrate (at the rate of 10 mg per mg of etorphine) ad-ministered post recumbency on white rhinoceroses immobilised with combinations etorphine, azaperone +/- hyaluronidase and etorphine, midazolam +/- hyaluronidase. Physiological measurements included heart and respiratory rate, oxygen saturation, temperature, blood pressure and arterial blood gas analysis were taken five minutes after recumbancy and ten minutes later after intravenous butorphanol was given. Real time blood gas analysis was performed using an Epoc blood analysis system (Epocal, Ottawa, Canada). Preliminary analysis of the data indicates there was a statistically significant improvement in pH, $pO_2$, and $pCO_2$ in all anaesthetic procedures ten minutes after intravenous butorphanol was given.

# SHIGATOXIGENIC AND ENTEROPATHOGENIC *ESCHERICHIA COLI* IN WILD FISH

CARDOZO MV, BORGES CA, BERALDO LG, OLIVEIRA FE, ÁVILA FA

Universidade Estadual Paulista (UNESP), Faculty of Agricultural and Veterinary Sciences, Dept. of Veterinary Pathology, Via de Acesso Paulo Donato Castellane s/n, 14884-900, Jaboticabal-SP, BRAZIL; maritavedovelli@yahoo.com.br

Shigatoxigenic (STEC) and enteropathogenic (EPEC) *Escherichia coli* are pathogens that stand out because of their zoonotic potential through the transmission of enteric diseases to humans. Along with this and the accuracy of molecular biology techniques, there is a global need and trend for researches related to the virulence genes in animal products. Although *E. coli* is not a natural organism in the intestinal tract of fish, it is known that the microbiota of these animals is directly connected to the quality of the river water in which they live. Based on this, the study aims to analyse the frequency of STEC and EPEC and the virulence genes related to these pathogens in fish and also determine the resistance profile against several antimicrobial isolates.

Ninety samples of intestinal content from fish were collected in three different rivers in the state of São Paulo, Brazil. At the laboratory, DNA extraction and PCR screening were performed, directly through pooled PCR from the intestinal content, aiming to detect the presence of STEC and EPEC. The following genes were examined: *stx1*, *stx*2 and *eae*. In the PCR for detection of virulence genes in isolates, were investigated for *bfp*, *ehxA*, *saa*, *iha, toxB*, *paa*, *efa1*, $lpfA_{O113}$, $lpfA_{O157/OI-141}$, $lpfA_{O157/OI-154}$, and *astA* genes. For determination of antimicrobial susceptibility the following agents were tested via agar disc diffusion method: ampicillin (10 µg), cephalothin (30 µg), streptomycin (10 µg), gentamicin (10 µg), ciprofloxacin (5 µg), chloramphenicol (30 µg), tetracycline (30 µg), nitrofurantoin (300 µg), trimethoprim-sulfamethoxazole (25 µg) and nalidixic acid (30 µg).

Of the 90 fish samples analysed, six (6.6 %) were positive for at least one of the genes related to STEC and EPEC and were also positive for virulence genes *ehx*A, *ast*A, *efa*1, $lpfA_{O113}$ and *saa*. Each strain had a resistance profile, however, the antimicrobials that were not able to eliminate growth of isolated pathogens were: ampicillin, cephalothin, streptomycin, gentamicin, ciprofloxacin, chloramphenicol, tetracycline and nitrofurantoin. Mammals like bubaline, cattle and sheep that live in the area around the rivers, are the main animals carriers of these pathogens and they are potential sources of infection of fish.

The presence of these pathogens and their virulence genes show that fish can carry STEC and EPEC, able to affect the health of humans. The resistance of these strains to several antimicrobial agents further aggravates the results found, as these animals can possibly transmit multiresistant isolates, causing a problem in public health.

# ISOLATION OF *KLEBSIELLA* SPP. AND *ESCHERICHIA COLI* FROM RECTAL SWABS OF FREE-RANGING GOLDEN-HEADED LION TAMARIN (*LEONTOPITHECUS CHRYSOMELAS*) DURING A TRANSLOCATION PROGRAMME, BRAZIL

CARVALHO VM[1], CROCE AP[1,2], PISSINATTI A[3,4], CATÃO-DIAS JL[2], BUENO MG[5]

[1]Universidade Paulista, Laboratório de Biologia Molecular e Celular, Instituto de Ciências da Saúde. Av. José Maria Whitaker, 290, São Paulo, SP, BRAZIL; vaniamc@uol.com.br

[2]Universidade de São Paulo, Departamento de Patologia, Laboratório de Patologia Comparada de Animais Selvagens – LAPCOM, Faculdade de Medicina Veterinária e Zootecnia. Av. Orlando Marques de Paiva 87, São Paulo, SP, BRAZIL

[3]Centro de Primatologia do Rio de Janeiro (CPRJ-GEUSO-DIBAP), Instituto Estadual do Ambiente (INEA), Estrada do Paraiso, s/n, Guapimirim, RJ, BRAZIL

[4]Centro Universitário Serra dos Órgãos (UNIFESO), Quinta Paraiso, Teresópolis, RJ, BRAZIL

[5]Instituto Pri-Matas para Conservação da Biodiversidade, R. Ponte Nova 255, Belo Horizonte, MG, BRAZIL

## Summary

Wild animals can be reservoirs of pathogens, including of zoonotic feature. They can carry and spread them from one place to another, particularly when handling animal populations. Enterobacteria are a large and heterogeneous group of Gram-negative bacteria and, although normally colonising the gastrointestinal tract of humans and animals, they can cause a variety of diseases and serve as indicators of environmental contamination and antimicrobial resistance. The present study aimed to investigate *Escherichia coli* and *Klebsiella* spp., and their antibiotic resistance in a free-ranging population of golden-headed lion tamarins (*L. chrysomelas* - GHLT) captured in fragments of the Atlantic forest in the state of Rio de Janeiro, for subsequent translocation to the state of Bahia, Brazil. Rectal swab samples of 36 GHLT were analysed, with the isolation and identification of 22 (61 %) *E. coli* and 17 (47 %) *Klebsiella* spp strains. Of these 88.2 % (15/17) were *K. pneumoniae* ssp. *pneumoniae*. The highest resistance rate obtained was to beta-lactam antibiotics, once 59 % of *E. coli* strains were resistant to at least one of beta-lactam antibiotics tested.

## Introduction

Epidemiological studies on potential pathogens in wild animals, either *in situ* or *ex situ*, are fundamental to the implementation of programmes for the prevention, control and monitoring of diseases and for developing public and animal health policies. In addition, the knowledge on pathogens that can impact human health and the conservation of species has been increasingly important within the One Health concept (JORGE et al., 2010). Golden-headed Lion Tamarins (*Leontopithecus chrysomelas* - GHLT) are endangered species whose the endemic population from Bahia state, Brazil, is in sharp decline (IUCN, 2012). Although some GHLT groups were released in an urban Atlantic forest remnants from Rio de Janeiro state. Nowadays, approximately 150 individuals reside in this area, being considered an exotic invasive species. Due to the risk of hybridisation with local and endangered *Leontopithecus* species (*Leontopithecus rosalia*, Golden-Lion Tamarin), environmental authorities have proposed the translocation of this invasive GHLT population to their region of origin. However, the translocations of free-living wild animals can present significant disease risks, not only to other wild

animals but also to livestock and humans population, specially, when zoonotic disease is involved. Within the Enterobacteriaceae family, genera *Escherichia* and *Klebsiella* stand out; the first, besides being linked to disease in non-human primates (CARVALHO et al., 2003), is used as indicator in the investigation of antibiotic resistance (COSTA et al., 2008), the genus *Klebsiella* has been linked to severe pulmonary processes and death in neotropical primates kept in captivity (Pissinatti, personal communication; ABEE et al., 2012), and is also important public health problem, especially due to antimicrobial resistance (MINISTRY OF HEALTH, 2010). Thus the present study aimed to investigate *E. coli* and *Klebsiella* spp. and their antibiotic resistance in a free-living population of GHLT that is being translocated from fragments of the Atlantic Forest in the state of Rio de Janeiro to their natural area in Bahia State.

## Material and methods

Stool samples were collected from 36 free-living GHLT belonging to eight different family groups, from the Serra da Tiririca State Park in the state of Rio de Janeiro. Samples were collected using sterile rectal swabs kept in Stuart transport medium (MEUS, Piove di Sacco, Italy). Samples were cultured on McConkey agar plates (Difco, Detroit, USA) and incubated under anaerobe conditions for 24 - 48 hours at 37°C. The identification of bacteria was performed using API-20E galleries (bio-Mérieux, Marcy l'Etoile, France) and the sensitivity test to 12 different antibiotics, belonging to six different classes: beta-lactams (ampicillin, amoxicillin, cephalexin, cefoxitin and ceftiofour); fluoroquinolones (enrofloxacin and ciprofloxacin), aminoglycosides (streptomycin and gentamicin), tetracycline; chloramphenicol and potentiated sulphonamides (sulfamethoxazole+trimethoprim) was performed according to international standards (CLSI, 2008a; CLSI, 2008b).

## Results and discussion

Of the 36 samples, 22 (61 %) *E. coli* and 17 (47 %) *Klebsiella* strains were isolated and identified, distributed equally by all groups of animals. *K. pneumonia* ssp. *pneumoniae* was isolated in 15 animals and *K. terrigena* in two of them. The pathogenic potential of *E. coli* strains will be subject of future studies; however, the presence of *K. pneumoniae* ssp. *pneumoniae* in the intestinal microbiota of apparently healthy animals deserves attention during capture, quarantine and translocation processes, since infections caused by *Klebsiella* tend to occur primarily in individuals with depressed immune system (DIENSTMANN et al., 2010). The highest resistance rate was related to beta-lactams, once 59 % of *E. coli* strains were resistant to at least to one aminopenicillins (4 strains were resistant only to ampicillin, 03 only to amoxicillin and 07 to both- table 1). This class of antibiotics is widely used in the treatment of diseases in humans, pets and production animals (GUENTHER et al., 2010). Taking into consideration both bacteria genera, antibiotic resistance was verified in all classes tested except for potentiated sulfonamides. Due to the fact that these are free-living animals that do not have direct contact with antimicrobial agents, it is inferred that the local human action promotes the emergence of resistant strains, because forest fragments where these animals live are located in an urban area and this situation enables animals in close contact with humans and domesticated animals residing nearby.

*Table 1: Absolute number and percentage of E. coli and Klebsiella* spp. *strains resistant to different antimicrobial agents.*

| | | *Klebsiella* resistance # *(%)* | *E. coli* resistance # *(%)* |
|---|---|---|---|
| **Aminopenicillins** | Ampicillin | -[a] | 11(50) |
| | Amoxicillin | -[a] | 10(45) |
| **Cephalosporins** | Cephalexin | 1(6) | 0(0) |
| | Cefoxitin | 0(0) | 0(0) |
| | Ceftiofour | 0(0) | 0(0) |
| **Fluoroquinolones** | Ciprofloxacin | 0(0) | 1(4) |
| | Enrofloxacin | 0(0) | 0(0) |
| **Aminoglycosides** | Streptomycin | 3(18) | 1(4) |
| | Gentamicin | 0(0) | 1(4) |
| **Tetracycline** | Oxytetracycline | 2(12) | 2(9) |
| **Chloramphenicol** | | 0(0) | 1(4) |
| **Sulphonamide+tri methoprim** | Sulfamethoxazole +trimethoprim | 0(0) | 0(0) |

[a]Intrinsically resistant

The above results besides providing subsides to eventually treat animals with a possible opportunistic infection during translocation process, also give insights about the anthropogenic action on wildlife in the referred natural area. We believe the study on potential pathogens, particularly those related to resistance to antimicrobial agents of routine use in human and animal health, offers relevant data for understanding the dynamic interaction between the various links that compose the Environmental Health.

## References


*ABEE C, MANSFIELD K, TARDIF S, MORRIS T (2012): Nonhuman Primates in Biomedical Research, Diseases. London, Waltham, San Diego. Elsevier Inc., 128 - 130.*

*CARVALHO VM, GYLES CL, ZIEBELL K, RIBEIRO MA, CATÃO-DIAS JL, SINHORINI IL, OTMAN J, KELLER R, TRABULSI RL, CASTRO AFP (2003): Characterization of monkey enteropathogenic Escherichia coli (EPEC) and human typical and atypical EPEC serotype isolates from neotropical nonhuman primates. J. Clin. Microbiol.* ***41****, 1225 - 1234.*

*CLS (2008a): Performance standards for antimicrobial disk and dilution susceptibility tests for bacteria isolated from animals; approved standard - third edition. CLSI document M31 - A3. Wayne, PA: Clinical and Laboratory Standards Institute.*

*CLS (2008b): Performance standards for antimicrobial susceptibility testing. CLSI document M100 - S18 e M100 - 15. Wayne, PA: Clinical and Laboratory Standards Institute.*

*COSTA D, POETA P, SÁENZ Y, VINUÉ L, COELHO AC, MATOS M, ROJO- BEZARES B, RODRIGUES J, TORRES C (2008): Mechanisms of antibiotic resistance in Escherichia coli isolates recovered from wild animal. Microb. Drug Resist.* ***14****, 71 - 77.*

*DIENSTMANN R, PICOLI SU, MEYER G, SCHENKEL T, STEYER J (2010): Phenotypic research on Klebsiella pneumoniae carbapenemase (KPC) enzyme in Enterobacteriaceae from hospitals. J. Bras. Patol. Med. Lab.* ***46****, 23 - 27.*

*GUENTHER S, GROBBEL M, HEIDEMANNS K, SCHLEGEL M, ULRICH RG, EWERS C, WIELER LH (2010): First insights into antimicrobial resistance among faecal Escherichia coli isolates from small wild mammals in rural areas. Sci. Total Environ.* ***408****, 3519 - 3522.*

*JORGE RSP, ROCHA FL, JUNIOR JAM, MORATO RG (2010): Occurrence of pathogens in wild carnivores and their implications for conservation and public health. Oecologia Australis.* ***14****, 686-710.*

*KIERULLF MCM, RYLANDS AB, MENDES SL, OLIVEIRA MM (2008): Leonthopithecus chrysomelas. In: IUCN 2012. IUCN Red List of Threatened Species. Version 2012.2. www.iucnredlist.org. Downloaded on 07th January 2013.*

*MINISTRY OF HEALTH (2010): National Health Council. http://conselho.saude.gov.br/. Downloaded on 24th December 2012.*

# DIURNAL RHYTHM OF SALIVARY CORTISOL SECRETION IN CAPTIVE AFRICAN ELEPHANTS (*LOXODONTA AFRICANA*)

CASARES M[1], SILVÁN G[2], CARBONELL MD[1], GERIQUE C[1], MARTINEZ-FERNANDEZ L[2], CÁCERES S[2], ILLERA JC[2]

[1]Bioparc Valencia, Avda Pío Baroja 3, 46015 Valencia, SPAIN; miguel.casares@bioparcvalencia.es
[2]Universidad Complutense de Madrid, Facultad de Veterinaria, Departamento de Fisiología Animal, Avda. Puerta de Hierro s/n, 28040 Madrid, SPAIN

Non-invasive glucocorticoid analysing techniques allow accurate monitoring of stress responses in several species. In African elephants, cortisol has already been measured in faecal and urinary samples, but not in salivary samples. However, knowledge of the basal secretory diurnal rhythm is necessary to evaluate the significance of fluctuations in cortisol concentrations as a stress indicator. In this study, non-invasive salivary samples from nine non-pregnant African elephant females (ages range between 7 and 25 years), *Loxodonta africana*, were collected during May, June and November 2012 (n = 133) and cortisol was measured in unextracted samples by enzyme immunoassay technique, previously validated for this species. Salivary samples were collected using cotton swabs at two hours intervals from 08:00 to 20:00 and in November also at four hours intervals from 20:00 to 08:00 (over-night), samples were centrifuged after collection and stored the samples at -20ºC until the hormonal analysis. Animals are kept at Zoological Garden “Bioparc Valencia” under identical circumstances: the herd is maintained in their indoor enclosures until 10:00 and then released to the outdoor enclosures until 21:00 (May/June) and 19:00 (November). No adult elephant bull was present at the zoo during this time. No differences were noted between the different sampling periods. The results demonstrate a clear diurnal pattern of cortisol secretion with the lowest concentration observed at 20:00 (1.08 ± 0.46 ng/ml saliva) and the peak concentrations at 10:00 (3.65 ± 0.66 ng/ml saliva), similar to that described for other diurnal species. Thus, zoo elephants follow a circadian rhythm (sleep-wake cycle) adapted to daily zoo husbandry routines.

## Acknowledgements

This study is founded in part by a grant of the Barcelona Zoo Foundation (PRIC 2012).

# GALLBLADDER STONES IN A BEARDED DRAGON (*POGONA VITTICEPS*)

COLON V

Barrier Animal Care Clinic, 32 Hardens Manor Way, Eastmoor Place, Charlton, SE7 8LP, LONDON, UK; vio36000@gmail.com

## Summary

In this case report, choleliths were diagnosed in a pet bearded dragon. Gallstones have been reported several times in reptiles, but are still considered uncommon. In dogs and cats, choleliths are asymptomatic in the majority of cases and are a fortuitous finding. A gallbladder is present in many animals, including all adult lizards, snakes and chelonians. In reptiles, gallstones have been associated with parasitic infection. Many protozoan and metazoan have been found to infect the bile duct and gallbladder. For example, Coccidia have been identified in the bile and gallbladder of reptiles for several years. In this case, a bearded dragon (*Pogona vitticeps*) was presented with anorexia and weight loss. After the initial diagnostic test, an exploratory surgery was performed. The only abnormality found was a gallbladder much distended containing numerous calcium oxalate stones. The clinical significance of choleliths in reptiles is still unknown.

## Introduction

A gallbladder is an organ present throughout animal species. Indeed this organ has been found in most fish, all adult reptiles, amphibians and in most mammals (OLDHAM-OTT and GILLOTEAUX, 1997).The function of this gland is essentially the same in all animals: storing bile, concentrating it by removing water and exchanging electrolytes. The gallbladder acts as a reservoir and mechanical pump (GILLOTEAUX, 1997).The variability in gallbladder morphology is dependent mainly on diet: most of the carnivores have one, but it is more variant in omnivorous and herbivorous (OLDHAM-OTT and GILLOTEAUX, 1997).

A gallbladder is present in lizards, snakes and chelonians (DIAZ-FIGUEROA and MITCHELL, 2006). In reptiles, the gallbladder is connected with the liver. Bile, which is stored in the gallbladder, has primary roles: to excrete fat as well as helping digestion and absorption of fat. Triglycerides are digested with a mixture of lipases and bile into a solution of bile salts, monoglycerides and fatty acids (DIAZ-FIGUEROA and MITCHELL, 2006).

Gallstones are principally known as a disease affecting dogs and cats. Choleliths are less commonly seen in reptiles, but they have been reported several times (FRYE, 1991). Cholelithiasis is uncommon in dogs and cats and many animals with choleliths are asymptomatic. In cats, choleliths are generally associated with cholangitis and cholangiohepatitis. Clinical signs include vomiting, icterus, abdominal pain, and fever (WILLIAMS, 2009). In humans gallbladder stones are classified into two categories: cholesterol stones and pigment stones (WILLIAMS, 2009). In dogs and cats, choleliths are principally formed of bilirubin pigments (CENTER, 2012). Pigment stones rarely produce clinical signs unless they cause obstruction or infection of the biliary system. The gallbladder is the site of formation of most choleliths but they can be formed in the duct. This normally requires an abnormality that produces bile stasis, such as partial obstruction or marked dilatation (WILLIAMS, 2009).

## Case

A 6-years-old male pet bearded dragon (*Pogona vitticeps*) was presented for lethargy, anorexia for a month and weight loss. A review of the husbandry was undertaken as part of the initial consultation and was found adequate. Physical and radiographic examinations were performed.

On clinical examination, the lizard was found underweight at a weight of 250 g. A mass quite mobile was felt in the coelomic cavity. Conscious X-rays were taken. On the lateral and dorso-ventral view, the mass was visible in the caudal part of the coelomic cavity. The bearded dragon was sent home on covering antibiotic ceftazidime 20 mg/kg of body weight by intramuscular injection every 72 hours as well as syringe feeding with critical care.

An exploratory surgery was scheduled a few days after. The bearded dragon had an intramuscular injection of buprenorphine at the dose of 0.01 mg/kg of body weight as premedication. Anaesthesia was induced intravenously using the ventral tail vein with propofol at the dose of 10 mg/kg of body weight. It was then intubatedand connected to an IPPV (intermittent positive pressure ventilation) anaesthetic machine. The anaesthesia was maintained with isoflurane 4 % in oxygen. The patient had intramuscular injections of meloxicam at a dose of 0.2 mg/kg of body weight and of ceftazidime at a dose of 20 mg/kg of body weight. The skin was prepared for aseptic surgery. A paramedian incision was performed.

On opening of the coelomic cavity, the gallbladder was found to be distended (see figure 1). The rest of the internal organs were examined and no obvious abnormalities were found. A cholecystotomy was performed. Seven elongated stones were present in the gallbladder (see figure 2). An ulcer was found on the mucosa of the gallbladder. A continuous wedge biopsy of the liver and the gallbladder was taken. The coelomic cavity was flushed copiously with saline fluid. The muscle and skin were closed with interrupted horizontal mattress sutures using an absorbable suture material (Vicry®l 5/0 Ethicon Inc.). The patient had a very slow recovery. It was hospitalised overnight in a vivarium heated to 32°C.

The next day, the bearded dragon was found bright, alert and responsive. It was discharged with routine covering antibiotic (metronidazole at dose of 20 mg/kg of body weight and ceftazidime injection), non-steroidal anti-inflammatory (meloxicam 0.2 mg/kg of body weight per os SID) and liver supplement (milk thistle). Intensive nursing care was prescribed as part of the lizard recovery treatment.

The bearded dragon had regular post-operative checkup for the next two weeks. It was found to being well at home and started eating on its own ten days post-surgery. A faecal analysis to check for coccidiosis was offered to the owner a few days after the surgery but was declined due to limited finances. A course of anticoccidial drug was then prescribed (trimethoprim/sulphamethazole at a dose of 30 mg/kg of body weight SID for seven days) as a preventative measure.

The gallbladder stones were sent for analysis and were confirmed as calcium oxalate. The histology report on the gallbladder sample determined a cholecystitis ulcerative, chronic. No visible infectious agents or inclusions agents were found. The liver was found congested and a cholestasis was diagnosed.

The bearded dragon was doing well at home but unfortunately died two months after the surgery without showing any clinical signs before death.

*Fig. 1: Gallbladder enlarged.*
*(Photo: Violaine Colon)*

*Fig. 2: Gallstones removed.*
*(Photo: Violaine Colon)*

## Discussion

Choleliths indicate chronic inflammation of the gallbladder. In reptiles, they tend to be large, soft and friable rather than lithic, and are yellow to green. When analysed, gallstones are found to be made of inspissated bile and cellular debris formed into a dense amorphous matrix (FRYE, 1991).
Choleliths have been reported several times in reptiles (FRYE, 1991). In a study realised by BEMIS et al. (2011), choleliths measuring from two to five millimeter where found post mortem in a female bearded dragon. The animal had presented with lethargy, anorexia and weight loss prior to death. It also suffered from pneumonia and the gallstones might just have been an incidental finding (BEMIS, GREENACRE et al., 2011). A gallbladder stone of the same composition (calcium carbonate) was found in a red-eye tree frog (*Agalychnis callidryas*) with also no association to a parasitic infection (STETTER, 1994). In painted turtle, calculi were found, they measured between 20 and 50 mm and were similar to the small gallstones described in humans (OLDHAM-OTT and GILLOTEAUX, 1997).
Humans commonly develop dietary-induced cholesterol gallstones. Whereas in dogs, gallstones contain mainly bilirubin, calcium and mucin (WILLARD and FOSSUM, 2000). The fact that gallstones are uncommon in dogs could be due to decreasing concentrations of cholesterol in canine bile, absorption of ionised calcium from the gallbladder, and failure to diagnose them (WILLARD and FOSSUM, 2000). Calcium salts are the major elements of pigment gallstones. Availability of ionised calcium may therefore be important in canine gallstones formation. In this case, the gallstones were formed of calcium oxalate, which differ from the ones found in humans, dogs and cats. Reptiles in captivity receive calcium supplementation as part of their normal diet. Most of the owners do find difficult to correctly dose the calcium powder (which is the most common form of calcium supplementation). Maybe, in this case, an excess of calcium could have been a factor to the formation of those stones. Unfortunately the calcemy of this particular animal was not checked due to limited finances.
Another factor of formation of gallstone in this bearded dragon is that it was fed mainly on insects and did not eat much of its vegetables, which are essential for the nutritional requirement of an omnivorous lizard (SCHILLIGER et al., 2010). Diet of carnivorous reptiles has a high lipid content (OLDHAM-OTT and GILLOTEAUX, 1997) which has an influence on the cholesterol level in the blood. Indeed, mild hypercholesterolemia and atherosclerosis was diagnosed in a bearded dragon that was exclusively fed on insects (SCHILLIGER et al., 2010).
Furthermore, in animals that eat periodically, the bile received from the liver becomes more concentrated and is stored for longer period of times. Since reptiles eat infrequently, a large amount of bile will be required for each meal (OLDHAM-OTT and GILLOTEAUX, 1997).

It has been reported that gallbladder stones are associated with parasitic infection or inspissated bile (STETTER, 1994). Moreover, in reptiles, gallstones have been associated with infection of the liver and gallbladder with trematodes (SMITH and COATES, 1939). In reptiles, many protozoan and metazoan have been found to infect the bile duct and gallbladder. For example, *Eimeria* sp, *Hexamita* sp (OLDHAM-OTT and GILLOTEAUX, 1997), *Trichomonas* sp. and many tremadotes have a predilection for the biliary system (FRYE, 1991). Coccidia have been identified in the bile and gallbladder of reptiles since the 20$^{th}$ century (LAINSON and PAPERNA, 1999). For example, *Eimeria* have been reported in gallbladder of Californian night lizard (BOVEE and TELFORD JR, 1965).

Parasites that infect the biliary tree do not always cause disease. Indeed, in a study realised in Brazil in wild geckos, all the infected individuals appeared healthy, even though heavy infection and considerable damage to the gallbladder epithelium were noticed on histological sections (LAINSON and PAPERNA, 1999). On the contrary, CIMON et al. (1996, have diagnosed two corn snakes (*Pantherophis guttatus*) with biliary cryptosporidiosis. Both of these individuals where affected chronic debilitating gastric cryptosporidiosis. At the present, the relation between immunodeficiency and predisposition of snakes for biliary cryptosporidiosis is unknown (CIMON et al., 1996). In primate and mice, cryptosporidiosis of the hepatic bile and pancreatic ducts has been reported. In primates, biliary infection usually happens in immunodeficient animals especially in individuals afflicted with simian immunodeficiency virus (CIMON et al., 1996).

Choleliths are often fortuitous findings at necropsy or during imaging. They often cause no issues. However, they may be associated with cholecystitis (WILLARD and FOSSUM, 2000). In this case, the gallstone was not associated with any infectious disease. The bearded dragon displayed only anorexia as a clinical symptom. The gallstone could have been a fortuitous finding caused by a possible underlying condition. Pain can be associated with the presence of gallstones in humans. In this case, the gallbladder was much distended and numerous stones were present, which probably induced pain, leading to anorexia. The clinical significance of choleliths in reptiles is still unknown.

## References


*BEMIS D, GREENACRE C, BRYANT M, JONES RKANIA S (2011): Isolation of a Variant Porphyromonas Sp. from Polymicrobial Infections in Central Bearded Dragons (Pogona Vitticeps). J. Vet. Diag. Invest.* ***23****, 99 - 104.*

*BOVEE ETELFORD Jr S (1965): Eimeria noctisauris sp. n., a coccidian from the lizard, Klauberina riversiana. J. Parasitol, 325 - 330.*

*CENTER S (2012): Cholelithiasis in Small Animals. In: Aiello SE, Moses MA (Eds.): The Merck Veterinary Manual.*

*CIMON KY, OBERST RD, UPTON SJMOSIER DA (1996): Biliary cryptosporidiosis in two corn snakes (Elaphe guttata) J. Vet. Diag. Invest.* ***8****, 398 - 399.*

*DIAZ-FIGUEROA O, MITCHELL MA (2006): Chapter 12 - Gastrointestinal Anatomy and Physiology. In: MADER DR: Reptile Medicine and Surgery (Second Edition). Saint Louis, WB Saunders, 148.*

*FRYE FL (1991): Chap 16: common pathologic lesions and disease processes. In: FRYE FL: Reptile care and Atlas of diseases and treatment. TFH Publications, Incorporated.* ***2****, 529 - 610.*

*GILLOTEAUX J (1997): Introduction to the biliary tract, the gallbladder, and gallstones. Microsc. Res. Techniq.* ***38****, 547 - 551.*

*LAINSON RPAPERNA I (1999): Some Coccidia from the gall-bladder and intestine of the Teiid lizard Ameiva ameiva ameiva and the gecko Hemidactylus mabouia in north Brazil. Parasite* ***6****, 151 - 162.*

*OLDHAM-OTT CKGILLOTEAUX J (1997): Comparative morphology of the gallbladder and biliary tract in vertebrates: variation in structure, homology in function and gallstones. Microsc. Res. Techniq.* ***38****, 571 - 597.*

*SCHILLIGER L, LEMBERGER K, CHAI N, BOURGEOIS ACHARPENTIER M (2010): Atherosclerosis Associated with Pericardial Effusion in a Central Bearded Dragon (Pogona Vitticeps). J. Vet. Diag. Invest.* ***22****, 789 - 792.*

*SMITH GCOATES C (1939): The occurrence of trematode ova, Hapalotrema constrictum (Leared), in fibroepithelial tumours of the marine turtle, Chelonia mydas (Linnaeus). Zoologica (New York)* ***24****, 379 - 380.*

*STETTER MD (1994): Clinical Challenge: Case 2. J. Zoo Wildlife Med.* ***25****, 177 - 178.*

*WILLARD MDFOSSUM TW (2000): Chapter 145: Diseases of the gallbladder and extrahepatic biliary system. In: Ettinger SJ, Feldman EC (2000). Textbook of Veterinary Internal Medicine: Diseases of the Dog and Cat., Saunders, 5th edition****:*** *1340 - 1344.*

*WILLIAMS JM (2009): Hepatobiolary surgery in cats. Southern European Veterinary Conference, Barcelona, Spain.*

# CONSERVATION IN THE ISLAND OF THE GODS: VETERINARY WORK OF THE FRIENDS OF THE NATIONAL PARKS FOUNDATION

DOUAY G[1], WIRAYUDHA B[2], LEHTINEN J[2], CHAI N[3]

[1]Zoo Lyon, Mairie de Lyon, 69205 Lyon cedex 01, FRANCE; guillaume.douay@mairie-lyon.fr
[2]Friends of the National Parks Foundation (FNPF), Jalan Bisma no. 3, Ubud, Gianyar, Bali, INDONESIA
[3]Ménagerie du Jardin des Plantes, 57 rue Cuvier, 75055 Paris, FRANCE

FNPF (Friends of the National Parks Foundation) is a local Indonesian non-profit organisation founded in 1997 by a group of veterinarians and conservation / community-minded Indonesians. (Drh. (Veterinary) I. Gede Nyoman Bayu Wirayudha, Leksmono Santoso and Drh. (Veterinary) Nyoman Budiartha)
The goal is to create and community-based run conservation that respects the interdependence of wildlife, habitat and the local community. The different programmes directly improve local community well-being (education scholarships, agro-forestry, eco-tourism) to motivate and mobilise the communities to protect wildlife, restore habitat, and support conservation work. This holistic approach, including understanding of local Indonesian communities, culture, spirituality, needs and challenges, gives the ability to work closely with the local communities to design programmes that benefit them, and the wildlife and habitats located around them.
Veterinary work is really important in these programmes and directly helps in the Bali Starling conservation work in Nusa Penida, relocation of orangutans from Palm oil plantation to Tanjung Puting National Park and Lamandau River Wildlife Reserve, wellbeing of local communities by introducing health survey on cattle and promoting sustainable and organic farming.

In 2011, FNPF took over the management of the only Wildlife Rescue Centre in Bali, one of eight across Indonesia. The centre's goal is to rescue, rehabilitate and release native wildlife. Most animals received are victims of habitat loss and animal trade. Our involvement with the FNPF took place there. We spent a few days assessing the help we could provide in the future and we evaluated the available amenities. We also had the chance to meet and teach some basics in wildlife medicine to very motivated local veterinary students. We also provided small logistical support by purchasing drugs and performing some veterinary work: faecal parasitology on residents animals, health check-up on new rescued animals (slow loris, palm cockatoo), small surgery (removal of lead shot from a white-bellied sea eagle).

# SCIATIC-FEMORAL NERVE BLOCK FOR SURGICAL TREATMENT OF BUMBLEFOOT IN CAPTIVE RAPTORS

D'OVIDIO D[1], NOVIELLO E[1], ADAMI C[2]

[1]Parco delle Maitine, Via Fontana dell'Occhio 1, 82020 Pesco Sannita (BN), ITALY; dariodovidio@yahoo.it
[2]University of Berne, Vetsuisse Faculty, Dept. of Clinical Veterinary Science, Berne, SWITZERLAND

Bumblefoot is a common disease of large species of raptors maintained in captivity such as long-winged falcons and larger owls. This inflammatory condition typically affects the plantar aspect of the feet and tends to become chronic, progressive, invasive and eventually disabling. The treatment of bumblefoot involves removal of the underlying causes and management of the wound. Surgical resection of the affected areas is strongly recommended in moderate to severe cases. We describe the clinical applicability of a nerve stimulator-guided technique, previously described in dogs, to block the sciatic and the femoral nerves in five (four females, one male; average age 7.8 ± 1.2 years) captive raptors (*Falco peregrinus)*, kept at the Parco delle Maitine, undergoing surgical treatment of bumblefoot. The trial was performed under ethical permission of the responsible institution and under signed, written informed owner consent. General anaesthesia was induced with 5 % isoflurane (Isoba, Intervet s.r.l., Milano, Italia) delivered in 100 % oxygen by face mask. After achieving adequate muscle relaxation, the raptors were intubated and the isoflurane vaporizer setting was decreased to 1.5 % - 2.0 %. The sciatic-femoral nerve block was performed with 2 % lidocaine (lidocaina, Molteni, Scandicci, ITA) at a volume of 0.05 ml/kg/nerve as the sole analgesic treatment applied during surgery. A nerve locator (Stimuplex ® HNS 12, BBraun, Melsungen, Germany) was used in order to improve the accuracy of the block. Sciatic-femoral block was feasible in raptors and the motoric responses following electrical stimulation of both nerves were consistent with those reported in dogs after successful nerve location. Iatrogenic complications, namely nerve damage and local anaesthetic toxicity, did not occur. We conclude that the technique described in dogs can be performed in raptors as well. Clinical trials are required to assess the analgesic efficacy of the combined sciatic-femoral nerve block in raptors as a part of multimodal pain management.

# GLASS FOREIGN BODY IN A GREEK TORTOISE AFFECTED BY PREOVULATORY FOLLICULAR STASIS

D'OVIDIO D[1], NOVIELLO E[1], MEOMARTINO L[2], SELLERI P[3]

[1]Parco delle Maitine, Via Fontana dell'Occhio 1, 82020 Pesco Sannita (BN), ITALY; dariodovidio@yahoo.it
[2]University of Naples Federico II, School of Veterinary Medicine, Veterinary Radiology Centre, Via F. Delpino 1, 80137, Naples, ITALY
[3]Clinica per Animali Esotici, Via Sandro Giovannini 53, 00137 Roma, ITALY

A 50-years-old female greek tortoise (*Testudo graeca*), kept at the Parco delle Maitine, was evaluated for anorexia, weakness, constipation and hindlimb paresis of approximately seven days duration. On physical examination the tortoise was lethargic, apparently dehydrated and weighted 2100 g. A blood sample was collected from the right jugular vein for a complete blood count and serum biochemical analysis. The results revealed mild dehydration with a PCV of 42 % (reference range 28 - 34 %) and TS of 80 g/L (reference range 31 - 54 g/L) as well as mild hypercalcemia with a ionised calcium of 2.3 mmol/L (reference range 0.82 - 1.78 mmol/L) but resulted overall unremarkable. Whole body survey radiographs in laterolateral, dorsoventral and anteroposterior projections showed intestinal dilatation and the presence of a trapezoid radiodense material in the intestine. Parenteral rehydration (Lactate Ringer Solution 20 ml/kg IC), oral fluids, mineral oil (5 ml/kg), lactulose (0.5 ml/kg) and mineral oil/water enemas were started. After three days the tortoise expelled a fragment of a glass bottleneck. The grossly shape of glass piece was compatible with the radiodense area observed in X-rays. Approximately two weeks later, on a follow-up recheck, the animal was still lethargic and anorectic. Ultrasonography and CT scan were performed to evaluate the presence of several rounded (about 15 to 20 mm), soft tissue opacities within the coelomic cavity. A tentative diagnosis of preovulatory follicular stasis was established and surgical treatment was scheduled. Despite a supportive treatment, started before surgery, the clinical conditions of the reptile worsened and the animal died five days later. A complete necropsy was performed and the preovulatory stasis was confirmed by the presence of about 50 enlarged (15 – 20 mm-diameter), round, bright-yellow vitellogenic follicles. An increased metabolic demand of calcium should always be considered when a foreign body is ingested and therefore an underlying reproductive disorder such as a preovulatory stasis (in females) should be suspect in foreign body cases.

# A SURVEY OF PARASITIC DISEASE IN WILD EUROPEAN HEDGEHOGS (*ERINACEUS EUROPAEUS*) ADMITTED FOR REHABILITATION IN NORTHERN ENGLAND

DRAKE GJ[1], SMITH A[2], PINBOROUGH M[3]

[1]Chester Zoo, Caughall road, Upton-by-Chester, CH2 1LH, UK; g.drake@chesterzoo.org
[2]RSPCA Stapeley Grange Wildlife Hospital, Stapeley Grange, London Road, Stapeley, Nantwich, CW5 7JW, UK
[3]Pinmoore Animal Laboratories (PALS), PALS Ltd, The Coach House, Town House Barn, Clotton, Tarporley, Cheshire, CW6 0EG, UK

European hedgehogs (*Erinaceus europaeus*) are commonly admitted to wildlife hospitals for rehabilitation in the United Kingdom. RSPCA Stapeley Grange Wildlife Hospital (SGWH) admits up to 600 casualty wild hedgehogs annually. Review of three years of records prior to this study showed that about 46 % are released. A significant number of hedgehogs are admitted for traumatic reasons (e.g. road traffic accidents (RTA) or entrapment) and are deemed otherwise healthy representatives of the wild population. Of the remaining admissions, the majority are orphans and/or sick. From these records at SGWH, within the hedgehog population in rehabilitation, there was an estimated 11.5 % morbidity for respiratory disease and 15.1 % morbidity for gastrointestinal disease, characterised by diarrhoea. Subsequent mortality was 36.7 % and 63.0 % respectively. Respiratory disease and diarrhoea were believed to be the two most significant medical causes of disease and death in these hedgehogs, but aetiology was mostly unknown.

This study surveyed hedgehogs for background respiratory and gastrointestinal parasite burdens, then analysed this data against morbidity and mortality records to assess the contribution to these diseases.

Data was recorded for all hedgehogs admitted during 2010 (n = 512), including sex, age (adult, juvenile in its first calendar year or neonate weighing < 90 g), location and circumstances of rescue and admission weight. All hedgehogs were examined by a vet and any diarrhoea or respiratory disease during rehabilitation recorded and treated. Final outcome of release, death or euthanasia was recorded.

A faecal sample was collected from hedgehogs on admission (n = 343) if they received no prior treatment and the staff member admitting the animal remembered to follow the protocol. Faeces was examined for protozoa, nematode, trematode and cestode eggs or larvae by direct smear, faecal concentration technique and a modified Ziehl-Neelsen stained smear for *Cryptosporidium* spp.

The overall mortality was 53.6 % (275/512), therefore release rate was 46.4 %, in line with previous data, suggesting 2010 was a representative year. In total, 33.6 % (n = 172) of hedgehogs admitted were representative of the general population, i.e. they had suffered mis-adventure such as RTA, but were medically well. Of the remaining admissions 53.9 % (276/512) were mixed health status, 8.4 % (43/512) were sick and for 1.6 % (8/512) data was deficient. During rehabilitation, 18.4 % (n = 94) developed diarrhoea, 21.9 % (n = 112) showed respiratory signs and 21.5 % (n = 110) were diagnosed with trauma.

Faecal samples identified three main parasites, *Capillaria* spp. 55.7 % (n = 191), *Crenosoma striatum* 35.6 % (n = 122) and *Cryptosporidium* spp. 19.8 % (n = 68). In addition, single instances of *Giardia,* three of *coccidia* (*Isospora* spp.), and three unidentified nematode infections were found. Further analysis and discussion of these data will be presented at the conference regarding parasite burdens, health status, time of year and signalment.

# CASTRATION OF IMMATURE MALES AS A MANAGEMENT TOOL OF SURPLUS *LEMUR CATTA*

FERNÁNDEZ-BELLON H[1], MAYA-SORIANO MJ[2], TABERNER E[2], ALMAGRO V[1], LÓPEZ-BEJAR M[2], ABELLÓ MT[1]

[1]Parc Zoològic de Barcelona, Parc de la Ciutadella s/n, 08003 Barcelona, SPAIN; hfernandez@bsmsa.cat
[2]Universitat Autònoma de Barcelona, Dept. of Animal Health and Anatomy, 08193 Bellaterra, SPAIN

Surplus males pose a generalised management challenge in zoos. On reaching maturity, these animals are usually at the centre of sexual aggression and in most cases are expelled from their family group. Establishment of bachelor groups, or culling, have been advanced to address this problem. Alternatively, neutering can reduce or even suppress sexual behaviour, as well as secretion of pheromones and other markers of sexual maturity. Castration of young immature surplus *Lemur catta* males has allowed keeping these surplus males within their family group at Barcelona Zoo, while maintaining a stable social structure. The group is currently composed of a breeding male, seven adult females, four neutered adult males, and seven offspring younger than two years. The neutered *L. catta* males were castrated at ages ranging from 0.5 year to 1.5 years. Histological and immuno-histochemical evaluation of the testes (lumen of spermatic tubes, mitotic index of spermatogonies and androgenic activity of interstitial cells) showed development ranging from immature testes (ages six and eight months) to incipient testicular development and active spermatogenesis (ages 1 year and 1.5 years). The two males castrated at one year of age or older had been attacked and wounded, presumably by the breeding male prior to castration. After castration, the older individual was only readmitted into the group after prolonged protected contact coupled with treatment with medroxy-progesterone and treatment of the breeding male with zuclopenthixol decanoate. This was avoided by early castration of the younger animals, although they required a surgical inguinal approach to the immature testicles. On follow-up, all four animals developed fully, albeit with underdeveloped penis and scent glands, and displayed the tendency to obesity characteristic of castrated animals. These data suggest castration as early as before one year of age may be suitable to maintain surplus male lemurs within a breeding group and prevent social distress due to sexual competition. Long term follow-up of physiological and social consequences in these and other neutered individuals of this procedure is ongoing.

# URINE PROTEOME EVALUATION IN LARGE FELINES

FERRARI G[1], DI CERBO P[2], ISANI G[1], FERLIZZA E[1], FRIEDRICH KG[2]

[1]University of Bologna, Dept. of Veterinary Medical Sciences, Via Tolara di sopra, 50 Ozzano Emilia, Bologna, ITALY
[2]Fondazione Bioparco di Roma, Viale del Giardino Zoologico, 20, 00197 Rome, ITALY; klaus.friedrich@bioparco.it

Data on urine proteome in large felines are lacking in literature, therefore the aim of our research is to study urine proteomes with sensitive analytical methods to monitor the health status in lions (*Panthera leo*), tigers (*Panthera tigris*) and leopards (*Panthera pardus*). Four urine samples were collected from May to December 2012, via non-invasive methods (from urine pools on the ground by a syringe) from two tigers, two lions and three leopards from Rome's Bioparco (Italy). Urinary total proteins (UTP), creatinine and the urine protein to creatinine ratio (UP/C) were measured by automated methods (Olympus AU400) routinely used in small animal practice. In order to separate urinary proteins, samples were analysed with sodium-dodecyl-sulphate poliacrilamide gel electrophoresis (SDS-PAGE, Invitrogen®). Mean UTP values were not significantly different in lions, tigers and leopards (40, 43, 46 mg/dL respectively), while mean UP/C values were significantly lower in lions (0.11) than in tigers (0.28) but not than in leopards (0.22). These values could be considered as representative of animals with no clinical signs of disease. Regarding qualitative proteinuria, with SDS-PAGE, 29 different protein bands were separated in lions, 26 in tigers and 30 in leopards (figure 1). Urine protein patterns resulted reproducible and species-specific; our preliminary data suggest the use of urine proteome as a tool to evaluate the health status in large felines.

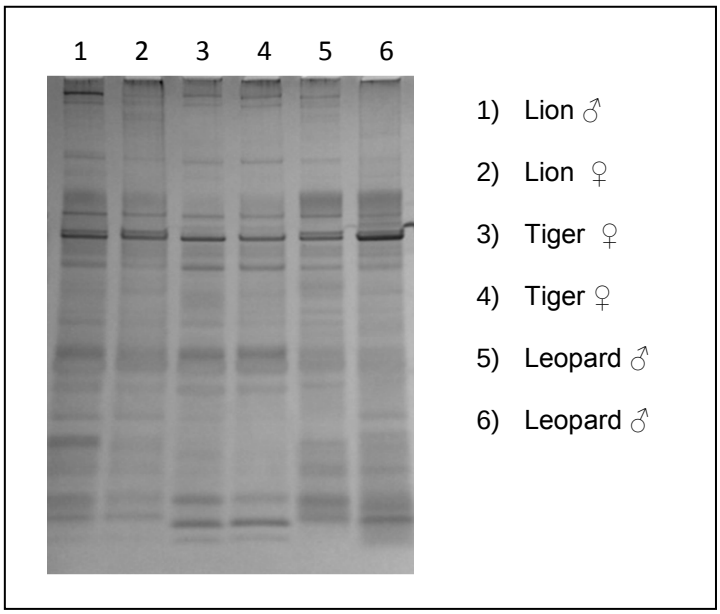


*Fig. 1: SDS-PAGE of urine samples from large felines.*

# PROTEIN ELECTROPHORESIS IN THE SERUM OF HERMANN'S TORTOISE (*TESTUDO HERMANNI*)

FIORUCCI L[1], CECCARELLI M[1], MACRELLI R[1], CROSTA L[2]

[1]Clinica Veterinaria "S. Teresa", via Piave 23, 61032, Fano (PU) ITALY; letiziafiorucci@gmail.com
[2]Clinica Veterinaria "Valcurone", via Kennedy s/n 1, 23873, Missaglia (LC), ITALY

In veterinary medicine protein electrophoresis has become a routine test, but the use of electrophoresis in exotic animals is often controversial, especially because of the lack of reference values for most of the less common species. A scale of reference values, obtained from healthy Hermann's tortoises (*Testudo hermanni*) can be a very useful tool for the assessment of the health status in tortoises of this endangered species. The aim of this study is to establish a preliminary reference interval for the protein fractions, in specimens of Hermann's tortoises in normal conditions.
Serum samples from asymptomatic (n = 37) and symptomatic (n = 7) adult Hermann's tortoises were analysed by cellulose acetate electrophoresis (CAE). Symptomatic animals were presented for a general health check, whereas, the diseased animals were presented with different clinical signs. Clinical diagnosis in the symptomatic tortoises included intestinal obstruction due to foreign bodies, lethargy, dysorexia, bilateral conjunctivitis, deep wounds, perineal myiasis, plastron hyperaemia and diffuse dermatitis. The health status of the specimens was determined on the basis of a thorough clinical evaluation. Electrophoresis results were compared using the Mann-Whitney test (independent samples).
Four protein fractions were identified: albumins, α-globulins, β-globulins, γ-globulins and the albumin-globulin ratio (A/G). Total protein concentration (Min - Max: 0.90 – 7.80 g/dl for healthy tortoises, 4.15 – 11.20 g/dl for diseased ones) was measured by the biuret method. The Mann-Whitney test between asymptomatic and symptomatic tortoises found a significant variation in α-globulins (P = 0.0047), in total globulins (P = 0.0030), and in A/G (P = 0.0045). The α-globulins fraction was higher for symptomatic tortoises (23.56 % [n = 7]) than asymptomatic ones (37.17 % [n = 37]). The α-globulins are the predominant globulin fraction. In symptomatic tortoises the α-globulins fraction is higher (Mean: 1.98 g/dl, standard deviation: 0.65 g/dl) than in the asymptomatic tortoises (Mean: 1.19 g/dl, standard deviation: 0.63 g/dl). Symptomatic animals had a lower value (Mean: 0.69 g/dl, standard deviation: 0.32 g/dl) than asymptomatic ones (Mean: 1.12 g/dl, standard deviation: 0.32 g/dl) of A/G ratio. To our knowledge, this is the first study that identified the reference values for the proteinogram of *Testudo hermanni.*

# EARLY DETECTION OF EMBRYONIC POST IMPLANTATION FAILURES BY ULTRASOUND BIOMICROSCOPY AND HISTOLOGICAL CORRELATION IN MURINE PREGNANCY

FLORES LE[1], HILDEBRANDT TB[1], KÜHL AA[2], DREWS B[1]

[1]Leibniz Institute for Zoo and Wildlife Research (IZW), Alfred-Kowalke-Str. 17, 10315 Berlin, GERMANY; flores@izw-berlin.de

[2]Charité – Universitätsmedizin Berlin, Campus Benjamin Franklin, Institute of Pathology/Research Center ImmunoSciences. Hindenburgdamm 30, 12203 Berlin, GERMANY

Ultra-high frequency ultrasound examinations (Ultrasound Biomicroscopy, UBM, 70 MHz, Vevo1200, VisualSonics Inc. Canada) were performed to monitor the pregnancy of 32 mice (C57BL/6) to identify conceptuses undergoing resorption at the earliest stage possible. Each individual was examined 7.6 times on average. Normally developing embryos (n = 9) were compared to embryos under resorption. Embryo resorptions were classified into early and advanced stages according to their ultrasonographic appearance and were evaluated by histology to verify UBM data. Total of 25 embryonic resorptions were identified in a time interval from day 7 to day 14 of gestation, resulting in a resorption rate of 11.4 %. Between days 7 to 8, the resorption proceeded at a fast rate and early stages could only be identified with certainty by retrospective analysis. After the diagnosis of embryo resorption, the embryo and its membranes disappeared within the next 24 hours. Between days 9 to 14 the embryo and its membranes were still present in early stages, the placental barrier was intact and only few leucocytes were detected. In two cases (day 9 and 10) a rupture of the decidua capsularis occurred, leaving the embryo exposed into the uterine lumen. This could not be attributed as a normal process since it is not up until day 11 that the decidua capsularis and giant trophoblast cell layer start to disappear. In advanced stages, only the Reichert´s membrane was evident and a generalised immune response characterised by phagocytes for clearance of apoptotic tissue and cellular debris was observed.

In our study, we showed that UBM is a reliable means to diagnose embryo resorption in vivo in a very small model animal. With this method, we can target specific animals that exhibit embryo resorption and exactly determine the start of the process.

# SHEEP-ASSOCIATED MALIGNANT CATARRHAL FEVER (MCF) IN CAPTIVE BANTENG (*BOS JAVANICUS*)

FRIEDRICH KG[1], DI CERBO P[1], FRONTOSO R[2], SCICLUNA MT[2], MANNA G[2], ELENI C[2], ROSONE F[2], LORENZETTI R[2], AUTORINO GL[2]

[1]Fondazione Bioparco di Roma, Viale del Giardino Zoologico, 20, 00197 Rome, ITALY; klaus.friedrich@bioparco.it

[2]Istituto Zooprofilattico Sperimentale delle Regioni Lazio e Toscana, Via Appia Nuova 1411, Rome, ITALY

## Summary

The report describes the first diagnosis of a Catarrhal malignant fever outbreak occurred in a group of Banteng, kept in captivity, confirmed by the detection of *Ovine herpesvirus 2* in specimens collected from dead animals by molecular assays other than following the clinical and pathological suspect. Among the neighbouring ruminant species reared, sheep resulted latently OvHV-2 infected and therefore were considered the most probable source of infections, even if the presence of other reservoirs among the wild ruminant population of the park cannot be excluded.

## Introduction

MCF is a fatal, systemic disease affecting several species of Artiodactyla, i.e. domestic and wild ruminants, and is mainly associated to infections caused by Alcelaphine herpesvirus (AlHV-1) and Ovine herpesvirus (OvHV-2). In Asia, Banteng (*Bos javanicus*) is considered one of the most susceptible species to the acute disease. This report describes an outbreak of SA-MCF in bantengs maintained in the zoo of Rome and the preliminary epidemiological findings.

## Materials and methods

The group of five banteng (*Bos javanicus*) was kept between two pens in which bison and domestic cattle were maintained respectively. Sheep and goats were reared 20 metres away separately and not in direct contact. Three banteng died between July and September 2011, following 12 to18 hours of illness, showing neurological signs and catarrhal nasal discharge. Necropsies for gross lesion observations were carried out and specimens were collected for histopathological, virological and microbiological examinations. In particular, for the detection of the OvHV-2 genome, a one-step PCR for the amplification of a 301 bp DNA fragment of the ORF75 was used. To evaluate the presence of possible latent viral reservoir species, whole blood samples and biological swabs, collected from bison, sheep and goats, were examined in PCR. The purified PCR products obtained were sequenced and compared in Nucleotide BLAST (blastn), using the DNASTAR Lasergene® software 8, to verify their identity with OvHV-2 sequences already available, as well as, conduct homology evaluations.

## Results

Consistent gross findings were mainly characterised by general hyperemic, haemorrhagic, degenerative and catarrhal lesions. Vasculitis and haemorrhages in multiple tissues and multifocal lymphohistiocytic infiltrates were the principal microscopic lesions.
The specific OvHV-2 PCR reacted positive for all organs of the three banteng, for 6 of the 19 sheep blood samples and for the nasal and ocular swabs of one of them. The sequence PCR products showed a 98 % homology with strain 1256 OvHV - 2 (a.n. EU851177.1). Molecular assays directed to other viral ruminant agents resulted negative and no significant bacterial organisms were isolated.

## Conclusions

Severity of the clinical signs and histological lesions in banteng were characteristic of acute MCF. Molecular assays confirm the clinical and pathological suspect. At the period of first diagnosis, among the neighbouring species reared, sheep were considered the most possible source of OvHV-2, with a probable indirect transmission of infection by the personnel having common access to the ruminants maintained in the area. However, due to new cases occurring later in time, in deer, further investigations are at the moment ongoing to establish if these are due to a long incubation of the disease or to the presence of other reservoirs remaining among the wild ruminant population of the park, even if the sheep and goats had been removed after the MCF outbreak.
This report confirms that MCF can be particularly destructive in zoos and that maintenance of host species constitutes a high risk source of diffusion for susceptible species in danger of extinction.

# DIAGNOSTIC IMAGING OF NORMAL ANATOMY AND PATHOLOGY IN GIRAFFE'S DISTAL LIMB

GALATEANU G, GÖRITZ F, SZENTIKS CA, HILDEBRANDT TB

Leibniz Institute for Zoo and Wildlife Research (IZW), Alfred-Kowalke-Str. 17, 10315 Berlin, GERMANY; galateanu@izw-berlin.de

Radiographic depiction of chronic foot disease in megavertebrates in captivity poses technical challenges due to the massive size of these animals. One case in point is chronic foot disease in captive giraffes (*Giraffa camelopardus*), which is frequently reported and often a reason for euthanasia, yet, the radiologic diagnosis is performed merely in very few isolated cases. Radiography and computed tomography were long proved as useful diagnostic tools for the assessment of normal anatomy and bone diseases in distal limbs of some megavertebrates (e.g. elephants). In giraffes there is thus far no recorded information on either radiographic techniques and protocols, or on normal radiographic anatomy or pathology of the distal limb. Furthermore, the imaging techniques and radiographic interpretation of the autopodial unique features known in giraffe, the tallest living terrestrial animal, need further research as the extrapolation from its domestic relatives, is not always straightforward.

To that end, the authors initiated a study, using synchronised computed tomography (CT) and digital radiography (DR), on 16 distal limbs of four giraffes, including the following sub-species: Rothschild giraffe (G. c. *rothschildi*; n = 3) and hybrid between Rothschild giraffe (75 %) and Kordofan giraffe (G. c. *antiquorum*; 25 %; n = 1). There were two males and two females with age ranging between one day and 24 years. Distal limbs included the autopodium, which consists of podial elements (carpus / tarsus), metapodials (metacarpal / metatarsal bones) and phalanges. Based on tridimensional CT images, we generated eight synchronised radiographies for each foot (four orthogonal and four oblique standard radiographic views).

Analysis of the CT and DR images searched for, and identified, the following criteria: 1) number of autopodial elements that can be depicted with maximal detail and minimal superimposition for each projection; 2) radiographic appearance of giraffe's autopodial elements associated with different developmental phases (neonatal, juvenile, adult); 3) normal radiographic aspect of the autopodium in correlation with each DR view; 4) radiographic evaluation and depiction of different bone pathologies identified first based on CT images. Since CT images provide excellent bone details of distal limbs, we were able to depict a large number of bone pathologies, which are radiographically described here for the first time in giraffes. These include: different types of fractures, bone fragments and mineralised bodies in and near joints (enthesiophytes and osteophytes), periosteal reaction, cortical remodelling, cortical sclerosis, extensive new bone production, bone cysts and osteolysis.

In light of these findings, the authors conclude that high-resolution CT and innovative, synchronised CT-DR imaging can be used as supportive, non-invasive diagnostic tools, providing valuable reference data for imaging distal limbs in giraffe as well as for studying its normal anatomy and pathology. As radiography remains the only imaging technique to be used for bone pathology diagnosis in these large, wild animals situated under "field conditions", this study provides all-important diagnostic tools for the clinician, allowing a better clinical management and improved animal welfare.

# NEW CLINICAL TOOLS IN RHINOCEROSES' MANAGEMENT: IMAGING DIAGNOSIS APPLYING SYNCHRONISED COMPUTED TOMOGRAPHY AND DIGITAL RADIOGRAPHY

GALATEANU G, HILDEBRANDT TB, HERMES R

Leibniz Institute for Zoo and Wildlife Research (IZW), Alfred-Kowalke-Str. 17, 10315 Berlin, GERMANY; galateanu@izw-berlin.de

Chronic foot disease poses a threat to the general health, represents a tremendous clinical challenge and often is a reason for euthanasia in captive rhinoceroses. Nevertheless, there is paucity of medical documented information regarding the radiographic imaging of both normal anatomy and pathology of the rhinoceros foot. Due to difficulties in approaching non-domestic animals, particularly mega-vertebrates, many diagnostic procedures are simply not done, overlooked or performed too late.

Therefore, the authors discovered and used a pioneering approach based on X-ray projections derived from tri-dimensional computed tomographic (CT) reconstructed images, applying a CT-digital radiography (DR) synchronisation. Using the state-of-the-art tools of high-resolution, 128-slices CT, we investigated and portrayed the normal radiographic anatomy and the radiographic features of bone pathology in eight distal limbs from two white (*Ceratotherium simum*) and one Indian rhinoceroses (*Rhinoceros unicornis*).

For the first time in rhinoceroses, the radiographic anatomy of the distal limb including carpal and tarsal joints was depicted both in CT and DR images.
A total of 203 autopodial (hand and foot) bones were investigated in this study. Bone lesions were present in both Indian and white rhinoceroses. Bone pathologies were discovered in 58 bones (28.5 %) at 95 different sites and comprised of a large variety of lesions including cortical sclerosis, proliferative new bone formation and bone remodelling with loss of normal shape (25/95; 26.3 %), intra- and periarticular mineralised bodies or bony fragments (23/95; 24.2 %), fractures (19/95; 20.0 %), periosteal proliferation (continuous and interrupted; 15/95; 15.7 %), osteolysis and bone rarefaction (11/95; 11.7 %). Bone cystic formation, ankylosis, enlargement of the linear radiolucent areas along the distal border of the distal phalanx termed "vascular channels", and changes in the trabecular pattern were also found. Concomitant presence of several lesions was similar in appearance to end stage degenerative joint disease (DJD), osteoarthrosis and/or osteoarthritis.
The radiographic appearance of these lesions was illustrated both in CT and DR images.

Acknowledging that digital radiography was able to depict both normal anatomy and several of the encountered bone lesions, the authors strongly recommend the establishment of radiographic examinations as a standard diagnostic procedure in rhinoceroses' distal limb assessment. The anticipated improvements on radiologic diagnosis will increase the effectiveness of their management and husbandry, are important for the animal's welfare and should be used when developing the most appropriate wildlife management and conservation strategies.

# COMPARATIVE MORPHOLOGY OF THE SCAPULAR ARCHITECTURE IN BEARS (*URSIDAE*) AS REVEALED BY HIGH-RESOLUTION COMPUTED TOMOGRAPHY

GALATEANU G, HILDEBRANDT TB, SZENTIKS CA, FREY R, SARAGUSTY J, GÖRITZ F

Leibniz Institute for Zoo and Wildlife Research (IZW), Alfred-Kowalke-Str. 17, 10315 Berlin, GERMANY; galateanu@izw-berlin.de

Among mammals, the family *Ursidae* comprises three basic locomotor behaviours: excellent swimming, slow to medium fast terrestrial locomotion and habitual tree-climbing. The detailed morphological basis of these complex behaviours still remains to be studied in many taxa. As a study object, we chose the scapula in bears, the general anatomical structure of which is known to differ from the scapulae of other carnivores. However, data on detailed scapular anatomy in different bear species is scarce. Therefore, we investigated potential correlations of the scapular structure with respective locomotor behaviour in *Ursidae*.

In order to improve the knowledge on the morphology of bear scapulae, the authors conducted a comparative and high resolution computed tomographic study including the following species and subspecies: Eurasian brown bear (*Ursus arctos arctos*), Syrian brown bear (*Ursus arctos syriacus*), American black bear (*Ursus americanus*), polar bear (*Ursus maritimus*), spectacled bear (*Tremarctos ornatus*), and giant panda (*Ailuropoda melanoleuca*). For comparative purposes and in order to evaluate scapular adaptations related to arboreal activity, we also studied scapulae of red panda (*Ailurus fulgens*), and koala (*Phascolarctos cinereus*), a bear-like marsupial.

This study revealed that all bear species conform in the following scapular features: (1) the scapula is rectangular in outline rather than fan shaped which is typical in other carnivores; (2) pronounced width of the scapular neck that exceeds the cranio-caudal diameter of the glenoid cavity by about one third; (3) extremely wide and very well represented supraspinatus and infraspinatus fossae; (4) a scapular spine that ends with a large, plate-like acromial process that projects ventrally towards the glenoid cavity further than in any other carnivore; (5) the caudal scapular border curves medially and caudally to delineate an additional fossa, the postscapular fossa (*Fossa postscapularis*). This fossa is well developed in all bears, regardless of body size. It distinguishes the bear scapula from that of all other carnivores.

The present study also identified scapular features that were exclusively found in spectacled bear and giant panda, but not in the other bear species studied: (1) supraspinatus fossa is smaller than the infraspinatus fossa; (2) supraspinatus and infraspinatus fossae consist of very thin bone tissue (less than 1 mm); (3) scapular spine is slightly concave cranially while in the other bears it has a linear contour; (4) very small coracoid process. Perhaps not surprisingly, the same features were also found in the arboreal species studied for comparison, the red panda and koala, only to a greater extent.

Considering these findings, we conclude that the identified skeletal specialised structures among *Ursidae* probably arose in the course of evolution of the species-specific locomotor behaviour despite of close phylogenetic affinity. Similar scapular features in *Ursidae*, in *Ailuridae* and in one marsupial (*Phascolarctidae*) might indicate functional convergence.

# DENTOGEN INFECTION AND SEPTICAEMIA IN THREE GREY SLENDER LORISES (*LORIS LYDEKKERIANUS*) CAUSED BY *TRUEPERELLA PYOGENES*

GEIGER C[1], SCHAUERTE N[1], EISENBERG T[2]

[1]Frankfurt Zoo, Bernhard-Grzimek-Allee 1, 60316 Frankfurt, GERMANY;
christina.geiger@stadt-frankfurt.de
[2]The Hessen State Laboratory (LHL), Schubertstraße 60, 35392 Gießen, GERMANY

## Introduction

Grey Slender Lorises (*Loris lydekkerianus*) belong to a primate species from the Lorisidae family whose taxonomy is currently under revision. Their distribution is Eastern and Southern India as well as Sri Lanka (PERERA, 2008). Grey Slender Lorises are primarily insectivorous nocturnal animals with loose social relationships. Their natural habitat is dry zone forest where they also sleep on trees in aggregations of several animals. At Frankfurt Zoo they are kept in pairs at the nocturnal animal house.

## Cases

In 2011, one male Grey Slender Loris (named Ratna) that lived together with a female (named Jara) was presented with a facial swelling on his left cheek (figure 1). Examination under anaesthesia revealed an infected first molar (M 1), which had been removed and both antibiotic and analgesic treatment was initiated. Despite proven in vitro effectiveness of the chosen antibiotic, symptoms deteriorated and the animal revealed exophthalmus accompanied by unilateral purulent nasal discharge before it died. The female animal did not show any symptoms and had been separated in the meantime for giving birth to a healthy female (named Jenny). Eight months later a second male (named Ulf) died due to almost the same tooth problems, treatment and deterioration after living with 'Jara' for several weeks. Again, 'Jara' and her daughter remained in good condition and developed well. The whole enclosure had been emptied, disinfected, and refurbished after each death. Six months later 'Jara' was presented with weight loss and a close examination showed loose molar teeth with reddened gingival mucosa (figure 2). Despite teeth extraction and multimodal treatment the disease progressed and resulted in the death of the animal, as well.

*Fig. 1: 'Ratna' during first examination under anaesthesia. (©Geiger)*

*Fig. 2: Affected gingiva of 'Jara'. (©Geiger)*

## Results and discussion

Gross pathology of all three animals revealed a moderate to severe periodontitis, catarrhal purulent pneumonia, and, in the case of 'Ratna', a widespread necro-suppurative periorbital and maxillary inflammation of the left face. Bacteriology of multiple organ samples of all three animals including liver, spleen, kidney, lung, intestines, and brain revealed *Trueperella (T.) pyogenes* as the leading pathogen partly accompanied by a diverse flora. Swab samples of oral cavity, ears, nose, and rectum from the two females (Jara and Jenny) had been tested negative twice for this bacterium before 'Jara' fell ill. *T. pyogenes* was identified employing phenotypic methods, MALDI-TOF MS and genotypic examinations (EISENBERG et al., 2012). Molecular studies employing BOX, ERIC, GTG, and RAPD pcr revealed a clonal relationship among *T. pyogenes* isolates from two animals.

In cattle, *T. pyogenes* (formerly *Arcanobacterium pyogenes*) is a common inhabitant of the skin and mucosal surfaces of many domestic animals and is an important opportunistic pathogen causing pyogenic infections mainly in ruminants. In cattle, it is known to persist in uterine tissues (JOST and BILLINGTON, 2005) and causes significant problems in economically relevant livestock. Despite broad effectiveness of various antimicrobial substances *T. pyogenes* infections tend to persist despite therapy (SILVA et al., 2008). Although *T. pyogenes* is equipped with several known and putative virulence factors the complete mechanism of pathogenicity is not fully explained yet (JOST and BILLINGTON, 2005).

In the cases presented here, both the source of infection and route of transmission could not be found. The environment had been disinfected and swab samples from mucous membranes of all contact animals gave only negative results until symptoms occurred. But we have shown that the here described *T. pyogenes* strain persisted in the Grey Slender Loris breeding population of Frankfurt Zoo for at least 12 months, as the molecular typing of *T. pyogenes* strains unequivocally confirmed only one clone in the Grey Slender Loris breeding population. Pathology also revealed that the genital tract of the female, which was not accessible to swab sampling due to its small size was free from pathogens. After unknown introduction of this strain, establishment in the oropharynx with opportunistic pathogenic potential is hypothesised. In all three cases, the purulent periodontitis and osteomyelitis resulted in septicemia, whereas the two males also developed catarrhal purulent pneumonia, where an aspiration/inhalation pathway is suspected.

Tooth and gingiva problems, like dental calculi and periodontitis, have been a common problem in captive Grey Slender Lorises (FITCH-SNYDER and SCHULZE, 2002) but have not occurred in the Loris population of Frankfurt Zoo since 1988. However, to our knowledge, no significant changes in food supplies for the population have been noticed in recent years. Therefore, the sudden onset of dental problems in otherwise healthy animals remains speculative. In addition, all post mortem examinations did not reveal any underlying causes for the oral disease in these three animals. A second group of Grey Slender Lorises at Frankfurt Zoo has never been in contact with the above mentioned individuals but is receiving the same food and is housed in the same building. They are not affected by any health problems and are now regularly checked for oral alterations, including microbiological sampling. *T. pyogenes* has not been isolated from this group, so far.

This is the first reported case of *T. pyogenes* causing oral disease and facial abscesses in Grey Slender Lorises. It has never been described in non-human primates before and is rarely found in humans with rural background and with close contact to cattle and swine (LEVY et al., 2009), as it is not assumed to belong to the normal human flora (JOST and BILLINGTON, 2005).

## Acknowledgements

We would like to thank Prof. Dr. C. Lämmler and and Prof. Dr. P. Kämpfer and their colleagues from

Justus-Liebig-University Giessen for their work on further *Trueperella* characterisation, Dr. U. Kaim from LHL for pathology, and Dr. S. Stadler for comments on the manuscript.

## References

*EISENBERG T, NAGIB S, HIJAZIN M, ALBER J, LÄMMLER C, HASSAN AA, TIMKE M, KOSTRZEWA M, PRENGER-BERNINGHOFF E, SCHAUERTE N, GEIGER C, KAIM U, ZSCHÖCK M (2012): Trueperella pyogenes as a cause of a facial abscess in a grey slender loris (Loris lydekkerianus nordicus): a case report. Berl. Münch. Tierärztl. Wochenschr.* ***125****, 407 - 410.*

*JOST BH, BILLINGTON SJ (2005): Arcanobacterium pyogenes: molecular pathogenesis of an animal opportunist. Antonie van Leeuwenhoek* ***88****, 87 - 102.*

*LEVY CE, PEDRO RJ, NOWAKONSKI AV, HOLANDA LM, BROCCHI M, RAMOS MC (2009): Arcanobacterium pyogenes sepsis in farmer, Brazil. Emerg. Infect. Dis.* ***15****, 1131 - 1132.*

*PERERA MSJ (2008): A review of the distribution of grey slender loris (Loris lydekkerianus) in Sri Lanka. Primate Conservation* ***23****, 89 - 96.*

*SILVA E, GAIVAO M, LEITAO S, JOST BH, CARNEIRO C, VILELA CL, DA COSTA LL, MATEUS L (2008): Genomic characterization of Arcanobacterium pyogenes isolates recovered from the uterus of dairy cows with normal puerperium or clinical metritis. Vet. Microbiol.* ***132****, 111 - 118.*

*FITCH-SNYDER H, SCHULZE H (2002): Management of Lorises in Captivity. A Husbandry Manual for Asian Lorisines (Nycticebus & Loris* ssp.*). www.loris-conservation.org*

# RENAL LESIONS IN BRAZILIAN CETACEANS

GONZALES-VIERA O[1], RUOPPOLO V[1, 2, 3], MARIGO J[1,2], BERTOZZI CP[2], CARVALHO VL[4], TAKAKURA C[5], NAMIYAMA G[6], VANSTREELS RET[1], CATÃO-DIAS JL[1]

[1]Universidade de São Paulo, Faculdade de Medicina Veterinária e Zootecnia, Departamento de Patologia, Laboratório de Patologia Comparada de Animais Selvagens (LAPCOM), Av. Prof. Dr. Orlando Marques de Paiva 87, 05508 - 270, Cidade Universitária, São Paulo, BRASIL; zecatao@usp.br

[2]Projeto Biopesca, Bahia 362, Canto do Forte, 11700 - 280, Praia Grande, São Paulo, BRASIL

[3]International Fund for Animal Welfare, 290 Summer Street, Yarmouth Port, Massachusetts, 02675, USA

[4]Associação de Pesquisa e Preservação de Ecossistemas Aquáticos, Praia de Iparana s/n, 61627 - 010, SESC Iparana, Caucaia, Ceará, BRASIL

[5]Universidade de São Paulo, Faculdade de Medicina, Laboratório da Disciplina de Patologia de Doenças Transmissíveis Av. Dr. Arnaldo 455, 01246 - 903, São Paulo, BRASIL

[6]Divisão de Patologia, Instituto Adolfo Lutz, Laboratório de Imuno-histoquímica, Av. Dr. Arnaldo 355, 01246 - 000, São Paulo, BRASIL

This study describes the occurrence of renal lesions in Brazilian cetaceans necropsied between the years 1996 and 2011. The sampled individuals died due to by-catch, after attempts at rehabilitation or stranded dead along the Brazilian coast. Kidney samples collected from 192 animals were evaluated histologically and, according to the findings, immunohistochemical and ultra structural techniques were performed. Due to field and logistical conditions, no bacteriological study was performed. Lesions were seen in 82 of 192 (42 %) cetaceans. Renal cystic disease was the most common lesion, observed in 34 of 192 (17 %) cases, and were classified in four categories: primary glomerulocystic diseases (PGCD - 26 %, 9/34); secondary glomerulocystic diseases (SGCD – 47 %, 16/34), simple cysts (23 %, 8/34), and polycystic kidney disease, reported in one (2.9 %) rough toothed dolphin. Distinction between PGCD and SGCD was made based on the absence (PGCD) or presence (SGCD) of predisposing factors, as nephritis, interstitial fibrosis and/or glomerulonephritis. The species influenced in the presence of SGCD, being least frequent in Franciscanas (*Pontoporia blainvillei*) (0.8 %, 1/124) than in other cetaceans (22.4 %, 15/67) (OR, 0.0357; 95 %; confidence interval, 0.0046 – 0.2762). Tubular adenoma was identified in a by-caught Franciscana. Other lesions included membranous and membranoproliferative glomerulonephritis in 28 of 192 (14 %) and 20 of 192 (10 %) cases respectively; interstitial nephritis in 21 of 192 (10 %); glomerulosclerosis in 8 of 192 (4 %); lipidosis in 19 of 192 (9 %) and pyogranulomatous nephritis in 5 of 192 cases (2 %), where two were associated with metazoan parasites. The possible causes of these lesions are discussed. To the authors' knowledge it is the first systematic study of renal lesions in cetaceans.

## Acknowledgements

FAPESP, grants # 2010/51801-5 and 2011/08357-0; and CNPq.

# TREATMENT WITH ENALAPRIL IN A BEIRA ANTELOPE (*DORCATRAGUS MEGALOTIS*) WITH CHRONIC RENAL FAILURE

HEBEL C, ARIF A, SCHILP C, BOUTS T

Al Wabra Wildlife Preservation, P.O. Box 44069, Doha, STATE OF QATAR;
christiana_hebel@yahoo.com

Al Wabra Wildlife Preservation (AWWP) in Qatar currently keeps the only captive population of Beira Antelopes (*Dorcatragus megalotis*) worldwide. Since 2006 the animals have been affected with the Fibrinous Pleuropneumonia Syndrome (FPPS), which reduced the captive population of 72 animals to currently 8 animals. Intensive investigations over more than five years disclosed evidence of *Mycoplasma ovipneumoniae* as cause of FPPS. Initially the clinical symptoms consisted of severe acute respiratory distress followed by sudden death. *Post mortem* examinations showed fibrinous pleuro-pneumonia with hepatisation. Over the years these symptoms shifted to a more chronic appearance of the disease with the main finding of chronic respiratory and kidney problems. Main findings in animals with renal failure are: anorexia, lethargy, azotaemia and anaemia. Histo-pathological examinations of the kidneys revealed interstitial fibrosis, severe deposits of amyloid in the blood vessel walls, interstitium and renal glomeruli as well as hyaline casts of protein.

This case report describes the treatment of chronic renal failure with Enalapril 0.5 mg/kg body weight in a Beira antelope over a period of 11 months, as well as the gross and histopathology findings after the death of the animal. The blood haematology and biochemistry during that time will be discussed and compared with similar cases not using Enalapril.

# THE TECHNIQUE OF ENDOSCOPY GUIDED STERILISATION OF MALE FERAL PIGEONS (*COLUMBA LIVIA* FORMA *URBANA*) FOR POPULATION CONTROL

HEIDERICH E[1,2], TOBLER C[1], LIERZ M[2], SCHILDGER B[1]

[1]Berne Animal Park, Tierparkweg 1, 3005 Berne, SWITZERLAND; lisa_heiderich@web.de
[2]Justus-Liebig-University, Clinic for Birds, Reptiles, Amphibians and Fish, Frankfurter Str. 91 - 93, 35392 Giessen, GERMANY

Feral pigeons cause structural and aesthetic damages to buildings and figures and can act as epizootic risk. Aim of this study was to evaluate whether endoscopy guided sterilisation of male feral pigeons is an applicable tool for field control of pigeon populations in cities. Endoscopic sterilisation has already been reported in various species of birds. A total of 252 male feral pigeons were caught in the city centre of Berne. Anaesthesia was maintained by isoflurane inhalation. Endosurgery was performed with a 2.7 mm x 18 cm 30° arthroscope used within a 4.8 mm x 14 cm protection sheath and 1.7 mm x 34 cm flexible biopsy forceps. Surgical complications were generally minor, 94.1 % of the pigeons displayed excellent recoveries, 5.9 % died. The complete procedure took 22.7 ± 5.8 minutes per bird, but getting faster with increase of training. The sterilised males were accustomed to two maintained pigeon houses together with fertile females. A third pigeon house with ten unsterilised pairs acted as control. During the observation period of seven months, in the two houses with sterilised males all clutches except two were unfertilised. The males from those pairs were endoscopicly re-examinated proofing the success of the technique. Therefore, it is assumed that the females must have copulated with foreign males. In the control pigeon house all eggs laid were fertilised.
The results indicate that endoscopic sterilisation of male feral pigeons seems to be a safe, minimally invasive procedure. Although it might be more expensive and time-consuming, compared to non-invasive methods like removing eggs, reduction of food or chemical sterilisation, surgical sterilisation lasts lifelong and gives the opportunity to also control pigeons who cannot be accustomed to pigeon houses.
As the health and reproductive status of the pigeons was unknown prior to surgery, complications can be considered as minimal. Therefore this technique should be conform to the animal welfare law and be allowed as routine procedure.

## Acknowledgements

The authors thank Dr Reglind Hühn of Karl Storz GmbH, Tuttlingen, Germany for providing the endoscopy equipment used in this study and the staff of Berne Animal Park for their support.

# ONE HEALTH IN PRACTICE: INVESTIGATING THE ROLE OF WILD AQUATIC TURTLES IN HUMAN SALMONELLOSIS

HERNANDEZ SM[1,2], HUANG J[1], YABSLEY M[1,2], SANCHEZ S[3], MERCURIO A[1]

[1]University of Georgia, 180 Green St, Warnell School of Forestry and Natural Resources, Athens, GA 30602, USA; shernz@uga.edu
[2]University of Georgia, 590 DW Brooks Dr, College of Veterinary Medicine, Southeastern Cooperative Wildlife Disease Study, Athens, GA 30602, USA
[3]University of Georgia, 590 DW Brooks Dr, College of Veterinary Medicine, Dept. Infectious Diseases, Athens, GA 30602, USA

*Salmonella* is a leading cause of bacterial diarrheal disease. The majority of cases are associated with food hygiene, however, serotypes associated with “non-foodborne” cases are on the rise, particularly in Southern USA (CDC, 2013). Most have traditionally been associated with turtle ownership. However, the cause of additional cases is never determined. In 2012, a multi-state outbreak occurred, with more than 347 people from 37 states infected with various *Salmonella* serotypes, yet only 70 % had contact with a turtle. This prompted an investigation to determine: 1) the prevalence of wild aquatic turtles and 2) if stress induced shedding in Painted turtles. The prevalence of *Salmonella* infection varied by species and habitat, but ranged from 10 to 17 %. Contrary to previous suggestions that “stress” induces shedding, turtles under stressful conditions stopped shedding *Salmonella* soon after placement in captivity. We propose that overcrowding/poor hygiene during transport/shipping may contribute to higher rates of *Salmonella* in captive-reared turtles. In contrast, only a minority of wild turtles is infected and stress did not induce shedding. However, wild turtles in the Southeast are harvested for private ownership and for food, both locally and abroad. In addition, the diversity of serotypes found in such a long-lived species implies that other aquatic wild animals may be at risk for exposure, highlighting the significance of *Salmonella* transmission for both people and other wildlife.

## Reference

Centers for Disease Control. http://www.cdc.gov/salmonella/. Accessed February, 2013.

# REFERENCE CHANGE VALUES IN A SMALL HERD OF CAPTIVE FEMALE AFRICAN ELEPHANTS (*LOXODONTA AFRICANA*)

HOOIJBERG E[1], BALFANZ F[2], LEIDINGER E[1]

[1]In Vitro Laboratory, Rennweg 95, 1020 Vienna, AUSTRIA; emma.hooijberg@invitro.at
[2]Tierärztliche Ordination Tiergarten Schönbrunn, Seckendorff-Gutent-Weg 6, 1130 Vienna, AUSTRIA; office@zoodoc.at

## Summary

The generation of population-based reference intervals is often difficult in exotic and wildlife species due to the low number of healthy individuals available as study subjects. An alternative to traditional population-based reference intervals exists in the form of subject-based reference intervals, more specifically the reference change value. The reference change value, once calculated, can be used to detect statistically significant changes in serial blood measurements from an individual animal. Reference change values were calculated from a small group of captive healthy female African elephants (*Loxodonta africana*) belonging to the Schönbrunn Zoo in Vienna, Austria. The resulting reference change values compared favourably with those previously published for dogs but were higher than those in humans. These reference change values can be used in future to detect clinically relevant changes in serial haematology and clinical chemistry analytes in this group of elephants.

## Introduction

Population-based reference intervals are commonly used in veterinary medicine as indicators of health and disease and are important tools in the clinical decision-making process. Guidelines for the determination of reference intervals in human as well as in veterinary medicine have recently been revised and published (HOROWITZ et al., 2008; GEFFRE et al., 2009). These guidelines state that population-based reference intervals should ideally be generated from 120 or more healthy individuals using non-parametric statistical methods, or less ideally, if fewer than 120 individuals are available the robust method can be used. Population-based reference intervals should not be determined from subject groups of less than 20 individuals. The determination and use of these reference intervals is therefore particularly difficult in wildlife and exotic species, where often only a low number of healthy individuals is available. In addition, existing reference intervals provided in the literature have often not been calculated in compliance with these guidelines. An alternative exists in the form of subject-based reference intervals, which can be determined from a single animal or a small group and are based on the measurement of biological variation of an analyte (WALTON, 2012). Biological variation consists of intra-individual ($CV_I$) and inter-individual ($CV_G$) variation. The $CV_I$ represents the mean coefficient of variation for separate values of an analyte from one animal while the $CV_G$ represents the mean coefficient of variation between individuals. Once determined, $CV_I$ can be used to calculate the reference change value (RCV), which is defined as the difference between two consecutive test results in an individual which is statistically significant in a given proportion of similar individuals. Once generated, RCVs are applied clinically by comparing the value of a particular analyte from a diseased animal's sample with the value of the same analyte in a blood sample from the same animal taken when it was healthy. If this difference (in %) is more than the RCV a significant change in the analyte has occurred. This change may be significant even though both values lie within population-based reference intervals.

African elephants (*Loxodonta africana*) are usually kept in small groups in captivity and properly generated population-based reference intervals for this species are scarce. The aim of this study was to calculate RCVs for haematology and clinical chemistry analytes for a small herd of African elephants living in captivity at the Schönbrunn Zoo in Vienna, Austria.

## Materials and methods

The subject group consisted of four healthy female individuals, ranging in age from 9 to 38 years. Samples were collected over the period from June 2011 to March 2012. One elephant was lactating during the study time period and one became pregnant. Blood samples were collected without sedation for haematology and clinical chemistry under standardised conditions, i.e. at the same time of day, on the same weekday and before feeding, from each elephant seven times over a period of nine months. Heparin blood samples were used for haematology and serum for clinical chemistry. The $CV_I$ and RCV for each analyte were calculated using a previously described method (FRASER and HARRIS, 1989; WALTON, 2012).

## Results

The $CV_I$ was generated for the total white blood cell count (WBC) (10.3 %), total red blood cell count (RBC) (9.4 %), haemoglobin concentration (Hb) (7.3 %), haematocrit (Hct) (7.4 %), mean cell volume (MCV) (3.3 %) and mean cell haemoglobin concentration (MCHC) (2.1 %) as well as for urea (19.4 %), creatinine (10.9 %), total protein (6.1 %), bilirubin (22.8 %), aspartate aminotransferase (AST) (17.3 %), calcium (7.0 %), phosphorus (15.8 %), sodium (2.3 %) and potassium (23.6 %). The analytical variation for each analyte ($CV_A$) was calculated from internal laboratory quality control data from the period in question and was used together with the $CV_I$ to calculate the RCVs. RCVs were: WBC 29.2 %, RBC 26.4 %, Hb 20.5 %, Hct 20.8 %, MCV 9.5 %, MCHC 6.6 %, urea 56.2 %, creatinine 36.6 %, total protein 17.8 %, bilirubin 68.8 %, AST 52.6 %, calcium 23.8 %, phosphorus 44.4 %, sodium 8.5 % and potassium 65.7 %.

## Discussion

The data on biological variation were compared to those published for dogs (JENSEN and AAES, 1993; JENSEN et al., 1998) and humans (RICOS et al., 2004). $CV_I$ for haematological analytes determined for these elephants was similar to those published for dogs, but higher than those for humans. $CV_I$'s for clinical chemistry analytes in the elephants here were comparable with those in dogs but again higher than those found in humans.

Limitations of the study included its retrospective nature, the lower number of animals used compared with similar studies, the relatively long time period over which the samples were collected and the biological heterogeneity of the animals being studied. In addition, the estimates of $CV_I$ are confounded by long-term analytical variation. Nevertheless, the RCVs generated for these elephants, although often higher than those reported for other species, can potentially be used to detect clinically relevant changes in haematology and clinical chemistry analytes in these individuals from this species.

## References


*FRASER CG, HARRIS EK (1989): Generation and application of data on biological variation in clinical chemistry. Crit. Rev. Cl. Lab. Sci.* ***27****, 409 - 437.*

*GEFFRÉ A, FRIEDRICHS K, HARR K, CONCORDET D, TRUMEL C, BRAUN J-P (2009): Reference values: a review. Vet. Clin. Pathol.* ***38****, 288 - 298.*

*HOROWITZ GL, ALTAIE S, BOYD J, CERIOTTI F, GARD U, HORN P, PESCE A, SINE H, ZAKOWSKI J (2008): Clinical and Laboratory Standards Institute (CLSI). Defining, establishing, and verifying reference intervals in the clinical laboratory; approved guidelines. 3rd ed, CLSI document C28-A3, Vol.* ***28****, No. 3.*

*JENSEN AL, AAES H (1993): Critical differences of clinical chemistry parameters in blood from dogs. Res. Vet. Sci.* ***54****, 10 – 14.*

*JENSEN AL, IVERSEN L, PETERSEN TK (1998): Study on biological variability of haematological components in dogs. Comp. Haematol. Int.* ***8****, 202 - 204.*

*RICOS C, CAVA F, GARCIA-LARIO JV, HERNANDEZ A, IGLESIAS N, JIMENEZ CV, MINCHINELA J, PERICH C, SIMON M, DOMENECH MV, ALVAREZ V (2004): The reference change value: a proposal to interpret laboratory reports in serial testing based on biological variation. Scand. J. Clin. Lab. Invest.* ***64****, 175 - 184.*

*WALTON RM (2012): Subject-based reference values: biological variation, individuality, and reference change values. Vet. Clin. Pathol.* ***41****, 175 - 181.*

# BASAL BACTERIAL POPULATION IN THE ORAL CAVITY OF CAPTIVE MEDITERRANEAN TESTUDO (*T. MARGINATA, T. GRAECA, T. HERMANNI*)

IANNACCONE M, MANGRAVITI D

Il mondo degli animali esotici, Via San Martino 67r, 16131 Genova, ITALY;
veterinariaesotici@gmail.com

The composition of the basal bacterial population present in the oral cavity of captive Mediterranean tortoises is poorly described in literature. Usually bacterial characterisation is performed in animals showing symptomatic diseases and only occasionally in healthy animals. The aim of this study is to clarify veterinary guidelines to better define pathological or autochtonous bacterial microflora in the oral cavity of the captive *Testudo marginata, T. graeca* and *T. hermanni*.
We analysed 100 tortoises (≤ 5 years old) without clinical symptoms maintained in different terraria under controlled temperature and humidity. All the animals tested were not able to hibernate for different reasons but all of them were in good health from at least four months before the sampling.
The animals were divided in groups considering the species, the size and the compatibility of some tortoises with the other. The collection of biological material was obtained through direct swabs of oropharynx. Different microbial populations were isolated and identified with manual and automatic techniques and the most representatives were *Staphylococcus sciuri* and different *Acinetobacter* species. The obtained results underline that these two bacterial groups are common in healthy captive Testudos.
This study shows preliminary results and it could be an useful support to laboratory microbiologist to better interpret the results obtained from the microbiological investigations of both healthy and sick animals.

This study is supported by Tarta Club Italia (Italian no profit association for tortoises and turtles protection).

# PROBLEMATIC OF WILD CATS IN THE URBAN DEVELOPMENT AREAS OF COSTA RICA

JIMÉNEZ M, HAGNAUER I, PEREIRA M

Universidad Nacional, Campus Benjamín Núñez, Escuela de Medicina Veterinaria, P.O. Box 86-3000, Heredia, COSTA RICA; mauricio.jimenez.soto@una.cr

In Costa Rica, due to the disproportionate urban development in recent years along with poorly planned different species, the wildlife - human contact becomes more frequent. Between 2011 and 2012, the attention of wildlife in the Hospital de Especies Menores y Silvestres (HEMS), Escuela de Medicina Veterinaria de la Universidad Nacional de Costa Rica, as well as other governmental and NGO´s, has increased. A total of 25 incidents in wildcats from central valley (two cases) and pacific coast (specially north pacific) of Costa Rica were attended. Twelve of those animals required veterinary medical care and 13 were translocated. Those wildcats were found by citizens of the areas mentioned before after traffic accidents, and a few of them from illegal captivity and taken to rescue centres from where they were taken to the HEMS for care. There was not information about the population size of wild cats in Costa Rica, however some researchers report that *Leopardus wiedii, Panthera onca* and *Puma yagouaroundi* are the most common species. Among the animals admitted to HEMS were: five ocelots (*Leopardus pardalis*), one jaguar (*Panthera onca*), two pumas (*Puma concolor*), an oncilla (*Leopardus tigrinus*), a jaguarundi (*Puma yagouaroundi*) and two margays (*Leopardus wiedii*). All patients underwent a complete physical examination, complete blood count, blood chemistry and serology for immunodeficiency virus and feline leukaemia. If necessary, ultrasound or radiography was performed. In total, 41.7 % of the animals showed regenerative anaemia, the count of leukocytes was in the lower range at 58.4 %. Regarding blood chemistry, five animals (41.7 %) presented alterations in the results. The 33.4 % were surgically treated for orthopaedic or soft tissue injuries. Two of the animals died, further two were euthanised for presenting injuries incompatible with life, in the wild or in captivity, five animals were reintegrated into the wild, and the other were kept in captivity in rescue centres and zoos. Once the wildcats were capable to be released, they were located in protected areas where there was food access and possibilities to survive. At the moment there are many efforts to develop researches in order to document if the reinsertion to the forest was satisfactory.

Most of the cases were located near major highways thus evidences the lack of organisation in the urban development, besides the failure to create a biological corridor that connects the semi-forest patches and forest.

# DETERMINATION OF HAEMATOLOGICAL AND BLOOD CHEMISTRY VALUES FOR PSITTACINES IN RELEASING PROGRAMMES IN COSTA RICA

JIMÉNEZ M[1,4], MORA E[1], HAGNAUER I[1], RETAMOSA M[2], ALFARO A[1], BLANCO K[3]

[1]Universidad Nacional, Campus Benjamín Núñez, Escuela de Medicina Veterinaria, P.O. Box 86-3000, Heredia, COSTA RICA; mauricio.jimenez.soto@una.cr

[2]Universidad Nacional, Campus Omar Dengo, Instituto Internacional en Conservación y Manejo de Vida Silvestre (ICOMVIS), P.O. Box 86-3000, Heredia, COSTA RICA

[3]Universidad Nacional, Campus Benjamín Núñez, Maestría de Medicina de la Conservación, Programa Regional de Posgrado en Ciencias Veterinarias Tropicales, P.O. Box 86-3000, Heredia, COSTA RICA

In Latin America, few releasing programmes of psittacines have a well-established health protocol since they are based almost exclusively on ethological aspects, and only in few cases their health status is appropriately monitored. Additionally, no information about blood count and chemistry profile is available for birds of the country, and clinicians are obliged to use data reported elsewhere as a basis for the analysis of animals that are going to be released, that lack of data is worrying because these considering that these parameters are a good, sensitive indicator of the avian's general health (GALVEZ et al., 2009) and that normally the climate and management of birds in captivity in other regions are very different from those present in the country.

The need of more research in threatened and endangered animals has been emphasised recently because of its significance in global species extinctions (SMITH et al., 2006).

The aim of the present study was to determine the health status of 108 psittacines from 5 native species kept in 8 rescue centres in order to be released in Costa Rica, and to define the haematological and blood chemistry values for this species in the country.

Except for differential cell counts, the mean haematological values between positive animals to circovirus and polyomavirus showed no significant difference with respect to the average values of the negative birds. The differential cell counts in the circovirus positive birds had a significant difference, in comparison with negative birds.

In total, 84 birds were analysed to blood chemistry analysis, which included the following parameters: total protein, albumin, globulin, albumin ratio - globulins, glucose, uric acid, urea nitrogen, AST, phosphorus and calcium. These results showed no significant differences between positive and negative birds to circovirus.

## References

*GALVEZ CF, RAMIREZ GF, OSORIO JH (2009): El laboratorio clínico en hematología de aves exóticas. Biosalud **8**, 178 - 188.*

*SMITH KF, SAX DF, LAFFERTY KD (2006): Evidence for the role of infectious disease in species extinction and endangerment. Conserv. Biol. **20**, 1349 - 1357.*

# MULTIDRUG-RESISTANT STAPHYLOCOCCUS IN ZOO ANIMALS WITH A FOCUS ON PRIMATES – IS THERE A ZOONOTIC POTENTIAL FOR HUMANS?

JÖRGENS D[1,2,3], GREENWOOD AD[2], RIETSCHEL W[5], HECKEL J-O[1], SALCHOW A[2,3], KNAUF-WITZENS T[4], HOELZLE LE[3]

[1]Zoo Landau in der Pfalz, Hindenburgstr. 12, 76829 Landau in der Pfalz, GERMANY; dirk.joergens@landau.de

[2]Leibniz Institute for Zoo and Wildlife Research (IZW), Dept. of Wildlife Diseases, Alfred-Kowalke-Str. 17, 10315 Berlin, GERMANY

[3]University of Hohenheim, Institute of Environmental and Animal Hygiene, Garbenstr. 30, 70599 Stuttgart, GERMANY

[4]Wilhelma Zoologisch-Botanischer Garten, Wilhelma 13, 70376 Stuttgart, GERMANY

[5]Pferdeklinik in Kirchheim, Nürtinger Str. 200, 73230 Kirchheim/Teck, GERMANY

Methicillin-resistant *Staphylococcus aureus* (MRSA) associated with wound infections has been a steadily growing problem for decades. Animal reservoirs exist primarily in livestock, but MRSA are also increasingly found in pets and sometimes in wildlife. Zoonotic transmission of MRSA occurs frequently to people with direct animal contact e.g. veterinarians and zookeepers where cases have been documented. Zoonotic MRSA is recognised as an occupational hazard. Scientific research on MRSA in zoos is limited to few publications documenting cases either in a zoo facility or in individual animals. No systematic scientific evaluation of MRSA in zoological institutions has been carried out to date. Therefore, a research project has been initiated as part of a doctoral thesis work supported by a German foundation (Grimminger Stiftung für Zoonosenforschung, Stuttgart) to better define the epidemiology within the captive animal populations in zoos. With the support of many zoos, we are collecting nasal and perianal swabs from zoo animals representing many taxa but, focusing on monkeys and apes. The following questions will be addressed: Which multi-resistant bacteria are present in zoo animals? How and by which taxa are they transmitted? Which strains are they? Do they originate from humans or animals? Are there unique features related to their virulence, and hence are they more or less dangerous to humans (zoo keeper, veterinarian) or their animal hosts? Interested zoological gardens are invited to take part in this project.

# GASTRIC CANDIDIASIS IN A TWO-TOED SLOTH (*CHOLOEPUS DIDACTYLUS*) IN THE UNITED ARAB EMIRATES (UAE)

KAISER C, BERNERS-SCHULTHEIS C, SCHUSTER RK, KINNE J

Central Veterinary Research Laboratory (CVRL), P.O. Box 597, Dubai, UNITED ARAB EMIRATES (UAE); claudiakaiser-vet@gmx.de

Sloths belong to the order Pilosa, suborder Folivora divided into two families: Megalonychidae (two-toed sloths) and Bradypodidae (three-toed sloths) with two and four species respectively. All species are arboreal commonly found in tropical rain forests of Central and South America. Sloths have a large ruminant-like, slow- acting stomach with three regions, subdivided in six compartments. In the wild, these animals eat a variety of plant material including leaves, buds, flowers and young stems. Insects, small rodents and reptiles may also be consumed when available, hence meat based products are added to captive diets.

Medical records of a total of 101 captive two-toed sloths (*Choloepus didactylus* and *Choloepus hoffmanni*) from North America were analysed in a retrospective study of morbidity and mortality (MOORE and LAMBERSKI, 2001). Alimentary tract diseases like dental problems, intestinal parasites and oral candidiasis were diagnosed in 30 % of 57 events in adult animals. *Candida* yeasts were present in several cases of glossitis/stomatitis, with the diagnosis based on cytologic examination of oral lesions. However, no gastric candidiasis was described in animals in this study.

Gastric candidiasis was found in one adult Linnaeus' two-toed sloth (*Choloepus didactylus*), also called Unau, which was sent to CVRL for taxidermy. Since the carcass was not sent for necropsy, the disease was found by coincidence during exenteration. The mucosa of the glandular part of the pre-pyloric area of the stomach (REZENDE et al., 2011) was completely covered with yellow-white diphtheroid membranes. Histopathology revealed marked proliferative-necrotising inflammation with lots of pseudohyphae in the keratin layers, typical for *Candida* spp., most likely *Candida albicans*.

*Candida* yeasts are normal inhabitants of the mucosa in the mouth and stomach. An overgrowth can occur if the immune system is weak (e.g. antibiotic treatment). Unfortunately, the history of the deceased sloth was unknown and therefore it was not possible to find out what the animal was fed and whether or not it was under medication.

## References

*MOORE TA, LAMBERSKI N (2001): Retrospective study of morbidity and mortality in the two-toed sloth (Choloepus hoffmanni and choloepus didactylus) in North America. In: Proceedings AAZV, AAWV, ARAV, NAZWV joint conference, 314 - 320.*

*REZENDE LC, MONTEIRO JM, CARVALHO P, FERREIRA JR, MIGLINO MA (2011): Morphology and Vascularization of the Gastric Compartments in Three-Toed Sloth (Bradypus torquatus Illiger, 1811). Int. J. Morphol.* ***29****, 1282 - 1290.*

# NEWCASTLE DISEASE INFECTIONS IN WILD PEAFOWL IN THAR DESERT REGION OF SINDH PROVINCE OF PAKISTAN

KALHORO NH[1], DHANANI J[2]

[1]Sindh Poultry Vaccine Centre Korangi Karachi, Livestock and Fisheries Dept., Government of Sindh, Korangi, Karachi 74900, PAKISTAN

[2]Shaheed Benazir Bhutto University of Veterinary and Animal Sciences Sakrand, Nawabshah Road, 67210 Sakrand, Sindh, PAKISTAN; jaythar@gmail.com

The Thar Desert region of Sindh province in Pakistan is estimated to habitat 65,000 to 70,000 blue and green wild Indian peafowls (*Pavo cristatus*).They are essential part of animal biodiversity of the desert region. In spring 2003, individuals of the wild peafowl population showed symptoms as swollen eyes and loss of appetite and finally, dozens of peafowl died. Serological studies and postmortem diagnosis indicated the presence of Newcastle disease infections in diseased and dead birds. Newcastle disease (ND) is one of the highly contagious viral diseases of poultry causing huge economic losses to the industry in Pakistan. It is caused by Avian paramyxovirus type-1 (APMV-1), a negative sense single-stranded RNA virus of the genus *Avulavirus,* family *Paramyxoviridae.* The disease is complicated due to different patho types and strains that may induce enormous variation in the severity of disease. In March 2010, sporadic infections were repeatedly recorded in peacocks in captivity in close proximity with domesticated chickens. However, it rapidly changed its pattern of infection from domestic poultry to wild birds particularly peacocks, doves and pigeons in 2011 and caused the death of about 37 wild and reared peacocks. The Newcastle disease virus turned virulent and viscerotropic in 2012, affecting hundreds of wild birds and killed 167 wild and 41 reared peafowls from February to July 2012. The diseased birds were showing the signs of nervous incoordination, twisted neck, greenish watery diarrhea, ruffled feathers, loss of appetite, fever, nausea, sneezing and coughing. The postmortem diagnosis revealed the thick mucoid fluid around the eye balls, haemorrhages in brain, proventriculus and swollen kidneys. The severity of infection increased during drought conditions due to delayed monsoon rains. This may be due to decreased availability of food, malnutrition and lowered immunity. The infection subsided after vaccination coupled with heavy monsoon rains and availability of plenty of water and food sources. The infection has been reported earlier in this year in reared wild peacocks in the Nara area of the Thar Desert in Pakistan and death toll has reached 12 by 25$^{th}$ of January 2013. This is thought to be mainly due to mutation in virus and adaptation to new environment and species. All birds died due to Newcastle disease with predominant nervous signs and involvement of Gastro-intestinal tract.

# TESTING BLOOD-SUCKING BUGS (TRIATOMINAE, HETEROPTERA) AS A BLOOD-SAMPLING TECHNIQUE TO EVALUATE WHITE BLOOD CELL SUBSETS

KLÖCKNER P[1], STEFANSKI V[1], VOIGT CC[1,2]

[1]Leibniz Institute for Zoo and Wildlife Research (IZW), Alfred-Kowalke-Str. 17, 10315 Berlin, GERMANY; voigt@izw-berlin.de
[2]Freie Universität, Takustr. 6, 14195 Berlin, GERMANY

## Summary

Recently, blood-sucking bugs (Triatominae; Reduviidae; Heteroptera) have been introduced to animal science as a novel and less-invasive substitute for potentially stressful conventional bleeding techniques. In the present study, triatomine bugs were validated for immunological studies in Long Evans rats as a model organism. From each of the 40 rats, blood samples were collected in a conventional manner (tail vein puncture) and via feeding of *Dipetalogaster maximus*; in group A (20 rats) with triatomine bugs used first and tail vein puncturing second, and in group B (20 rats) in reversed order. Differences in absolute numbers and relative proportions of blood immune cell subsets (leukocytes and leukocyte subsets: lymphocytes, monocytes, granulocytes, and lymphocyte subsets: T helper cells, B cells, T cytotoxic cells, Natural killer (NK) cells) were measured using an electronic blood cell counter and a flow cytometer. The median duration equaled 1 min for conventional bleeding and 25.5 min for bleeding with triatomine bugs. Therefore, only pair-wise comparisons for samples of group A were calculated to reduce a possible effect of time delay between the two bleeding events and associated stress responses on the outcome of pair-wise comparisons. In blood samples of group A, nine out of 15 cell parameters were identical, yet paired values of white blood cell subtypes correlated poorly between the two methods. In four out of 15 parameters, an increasing deviation of measured from expected values was observed with rising concentrations. Overall, the results demonstrate that caution must be exercised when interpreting white blood cell subsets that originate from blood collected via bugs, because some cell populations may get biased when blood is exposed to the saliva or intestinal - 146 - liquids of bugs. Therefore, white blood cell subset concentrations obtained from bug blood may offer poor or unqualified measures to base diagnostic decisions upon.

## Introduction

Differential blood counts are routinely used for diagnostics, both in veterinary examinations in general and in zoo and wildlife research in particular. The conventional way to obtain this information is by collecting a blood sample via puncture of a vein or venal plexus using a sterile needle. Animals from which blood samples are collected (hereafter called target animals) are then often mechanically or chemically immobilised which may put the health of the animals at risk (DYSON et al., 1998). In addition, venipuncture may damage blood vessels, ultimately leading to haematomas and other complications. Puncturing of the orbital venous sinus, a routine method in laboratory mice, may cause eye damage, infections and loss of eyesight (Monash University Animal Welfare Committee, 2008). Immobilisation and pain are stressful and thus may have a significant impact on the outcome of differential and absolute blood counts by altering blood parameters of interest (von HOLST, 1998; MARCO and LAVIN, 1999; RILEY, 1981; WELLS et al., 1984). Although conventional bleeding techniques are cost-effective and simple, they are not optimal for studies in which baseline values of hormones

and blood cells are wanted (MILLSPAUGH and WASHBURN, 2004; EOMERO and REED, 2005). Therefore, alternative and less invasive methods are much needed.

A new and promising bleeding method has been suggested in the 1990's, namely triatomine bugs (VON HELVERSEN et al., 1986). This method of bleeding has been recently adopted by veterinarians for diagnostic purposes in captive wildlife populations (STADLER et al., 2009), yet thorough validations for haematological parameters are largely missing (but see MARKVARDSEN et al., 2012). Previous studies have confirmed that this technique bears advantages over the conventional approach. For example, target animals do not necessarily have to be captured, restrained or anaesthetised for bleeding. In past studies, starved bugs were placed in small containers with windows that were covered by wire mesh so that bugs could feed on target animals. Such enclosures were placed at resting places of the target animal so that triatomines could consume blood in a secret way (BRAUN et al., 2009; THOMSEN and VOIGT, 2006). Thus, triatomine bugs may enable researchers or veterinarians to obtain blood samples from unstressed animals. By choosing triatomine bugs of adequate size, it is possible to set an upper limit to the amount of ingested blood which is usually in the range of 0.1 to 4 ml. Most target animals do not even recognise the insect sting and therefore exhibit a low glucocorticoid response compared with conventional bleeding techniques (ARNOLD et al., 2008; VOIGT et al., 2004). Another advantage of the bug bleeding technique is that triatomines do not inflict injuries, haematomas or scars. Therefore, it is possible to bleed target animals sequentially from the same spot.

Although the bug method bears several advantages over conventional bleeding techniques, it is essential to validate the precision and accuracy of this technique before it is widely applied. In particular, it is important to assess whether blood parameters are biased in response to dilution or digestive processes resulting from blood consumption by triatomine bugs. In past validation studies, two blood samples (one collected with triatomines, one with conventional techniques) were drawn from target animals to compare results in a paired test design. A variety of methods have already been validated, for example serological measurements (VOIGT et al., 2006; VOS et al., 2010), isotopic dilution techniques such as in doubly-labelled water experiments (VOIGT et al., 2003, 2005), clinical and haematological parameters (MARKVARDSEN et al., 2012) and endocrinological measurements (BRAUN et al., 2009; THOMSEN and VOIGT, 2006). In all cases, this less obtrusive blood sampling method provided reliable and accurate measurements of an array of blood parameters, yet recent studies also recorded some biased measurements when bugs are used, e.g. for haematological parameters (MARKVARDSEN et al., 2012).

This study tested if differential blood counts are similar in samples obtained via triatomine bugs and in those obtained via a conventional blood sampling method. For this, absolute numbers and the relative proportions of white blood cell subtypes were measured in 40 Long Evans laboratory rats by taking paired blood samples in random order, one blood sample using a triatomine bug and a second via tail vein puncture. Based on the high accuracy and precision of the bug method in previous validation experiments, we expected similar values for a given white blood cell subtype with both techniques.

## Materials and methods

Forty randomly selected outbred male Long Evans rats were selected from a breeding stock of 56 animals maintained at the animal facilities of the Department of Animal Physiology, University of Bayreuth (Bavaria, 95440 Bayreuth, Germany). Rats were housed in pairs in standard polycarbonate cages (420 mm x 260 mm x 150 mm, cage type III, Ehret, BadenWürttemberg, 79312 Emmendingen, Germany). Food (altromin 1324, Altromin, Niedersachen, 32791 Lage, Germany) and water were provided *ad libitum* throughout the experiment. Blood sampling was conducted in a room separate from the captive colony. We assigned randomly half of the rats to group A (first bug, second

conventional bleeding) and the other half to group B (first conventional bleeding, second bug). Permits for conducting animal experiments were obtained from corresponding authorities in Bayreuth.
Blood-sucking bugs (larval instar 4 of *Dipetalogaster maximus*, Reduviidae, Heteroptera) were reared in a captive colony at the IZW. All triatomine bugs were free of any parasites such as trypanosomes that could be potentially harmful to the target animals. All used triatomine bugs were sufficiently small to ensure that triatomines would not collect overly amounts of blood from target animals. Bugs were not fed for a period of three to five weeks before use in the experiments.
Blood was collected from the tail of unanaesthetised rats by using either a bug or by a sterile needle (0.70 x 38 mm, Braun Melsungen, Berlin, 12357 Berlin, Germany). During both bleeding events, rats were restrained in a dark, size-adjustable restrainer that prevented the animals from turning around. The tail was exposed through an open gap so that it was accessible to the experimenter. For the alternative method, a starved blood-sucking bug was placed on the rat tail. Usually, the triatomine bugs would quickly approach the tail and insert their proboscis into the skin. On average, rats were mechanically restrained for 28.0 ± 11.0 min (mean (plus minus) standard deviation) while blood samples were taken. The triatomine bugs required on average 23.0 ± 6.0 min to withdraw about 1 ml from rats. After the successful blood meal, the bug was removed manually. Blood was obtained from the crop of the insect by inserting a 23-gauge syringe into its abdomen (figure 1). Then, blood was transferred from the syringe into a plastic vial that was partly filled with EDTA. Immediately after the removal of the bug, rats were bled in the conventional manner or put back into their cages depending on the order of the two methods. For the conventional method, 22-gauge needles were used to draw blood samples from the tail vein. Blood was transferred directly from the needle into plastic vials that were partly filled with EDTA. During conventional bleeding, rats were restrained for an average of 2.0 ± 1.2 min. Bleeding rats conventionally required 1.3 ± 0.4 min. Twenty rats were first treated via bug and then via needle (group A) and another 20 rats were first treated via needle and then via bug (group B). The time lag between both methods was kept minimal and constant within each group. After collecting, both blood samples were mixed with EDTA to treat the blood identically and to prevent samples collected via the conventional way from coagulating. After bleeding, rats were transferred back into their cages.

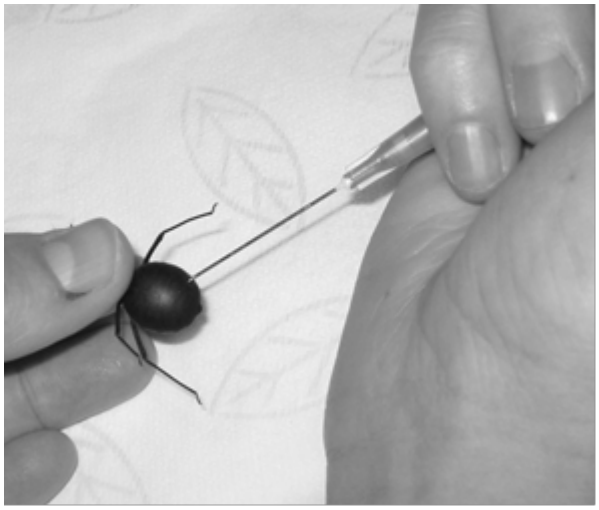

*Fig. 1: Extraction of blood ingested recently ingested by triatomine bugs by using a conventional needle and syringe. The ventral side of the abdomen is pierced to reach with the needle into the insect's crop.*

Blood samples were collected into plastic vials and stored on ice until the following day, when analyses were performed. Blood samples were analysed for their absolute number (N/µL) and percentages (%) of immune cells. The absolute number of leukocytes was determined using an electronic blood cell counter (COULTER® Z2, Beckman Coulter GmbH, Nordrhein-Westfalen, 47807 Krefeld, Germany) and the percentages of lymphocytes (LYM), monocytes (MON) and granulocytes

(GRA) were determined by flow cytometry (FACSCalibur, Becton Dickinson GmbH, Baden-Württemberg, 69126 Heidelberg, Germany). PE-conjugated OX-19 (anti-CD5), FITC-conjugated OX-38 (anti-CD4), FITC-conjugated OX-8 (anti-CD8a), FITC-conjugated clone 10/78 (anti-NKR-P1A), and FITC-conjugated OX-33 (anti-CD45RA or A/B) were obtained from PharMingen (Hamburg, 22335 Hamburg, Germany). The absolute number for each leukocyte subpopulation (i.e. granulocytes, monocytes and lymphocyte functional subsets) expressed per µL was derived from the percentage of each subpopulation identified, and the absolute number of leukocytes counted after the method of STEFANSKI and ENGLER (1998). The percentages of lymphocytes subpopulations (T helper cells, B cells, cytotoxic T cells, NK cells) within the absolute number of lymphocytes were determined by flow cytometric and the absolute numbers per µL were examined with the percentages of the lymphocytes subpopulations and the absolute number of lymphocytes according to STEFANSKI and ENGLER (1998).
Two values for each white blood cell parameter were obtained from each rat: one from blood samples obtained via bleeding with triatomine bugs and one from blood samples obtained via tail vein puncturing. The order of bleeding was reversed in half of the 40 animals. For descriptive reasons, white blood cell subsets were compared between samples collected first with either the triatomine bug method or the conventional method. Then, white blood cell subsets were compared between bleeding techniques in the second blood samples. Unpaired tests were performed using either parametric or non-paremetric tests according to whether or not assumptions for parametric testing were fulfilled or not.
Overall, triatomine bugs required more than 10 times longer for taking up blood from rats than when applying the conventional bleeding technique. Because bleeding events were only separated by about 1 min, the focus of this validation was on pair-wise comparisons in blood parameters obtained from group A (bug first, needle second). Before using parametric statistics, it was first tested whether the data of group A fulfilled the criteria for parametric testing by using a Kolmogorov-Smirnov test. Data was log transformed in case it was not normally distributed. Paired t-tests were used for pair-wise comparisons of blood leukocyte and lymphocyte subsets in samples obtained by bug and samples obtained by needle. To test whether paired leukocyte and lymphocyte subsets from the same target animal deviated systematically with increasing relative or absolute concentration, a linear regression was calculated after the reduced major axis method with the immune cell concentrations of the bug as dependent and the corresponding measures from the blood sample collected conventionally as the independent variable. RMA regressions were preferred over ordinary least squares regressions, because parameters derived from the bug and the conventional method involved errors. For calculating RMA regression models, the software RMA (Version I.17) was accessed at www.bui.sdsu.edu/pub/andy/rma.html on the 3rd of May 2012. A student t-test was used to test whether the slope of this regression deviated from 1. Systat (Version 11; Systat Software Inc., California 94804, Richmond, USA) or Graphpad (Systat Software Inc., California 92130, San Diego, USA) was used for statistical analysis and an alpha value of 5 % was assumed for all tests. We refrained from correcting the alpha value for repeated testing, because a lowered alpha value would reduce the likelihood of finding a significant difference between corresponding white blood cell subsets of the two methods. Therefore, applying Bonferroni-correction may lead to the false conclusion of matching data even though values may prove significantly different when using a 5 % alpha value. Thus, the approach of not correcting for repeated testing according to Bonferroni was conservative. Values are presented as means ± one standard deviation if not mentioned otherwise.

## Results and discussion

In group A, rats were bled first with triatomine bugs followed by the tail vein puncturing with a needle, and in group B, rats were bled first via tail vein puncture followed by bleeding with the triatomine bug.

Percentage (%) and absolute (N/µl) concentrations of white blood cell subpopulations were compared between first blood samples of groups A and B. Percentage concentrations of cell parameters were not different between the two bleeding techniques (table 1). However, absolute concentrations of WBC, lymphocytes, T helper cells and, B cells were significantly lower in blood collected with triatomine bugs than in blood collected conventionally (table 1). Then, percentage (%) and absolute (N/µl) concentrations of white blood cell subsets were compared between second blood samples of each group. No differences were observed in second samples of rats from group A and B (table 1).

*Tab. 1: Comparison of immune cell concentrations within 1st and 2nd samples. Significant differences are highlighted in bold.*

| Blood parameters | 1st Samples | | 2nd Samples | | Group A (bug first, needle second) | | Group B (needle first, bug second) | |
|---|---|---|---|---|---|---|---|---|
| | B↔C* | P-Value | B↔C* | P-Value | B↔C* | P-Value | B↔C* | P-Value |
| Percentage cell count | | | | | | | | |
| Lymphocytes (% in WBC) | ≈ | 0.189 | ≈ | 0.957 | **<** | **0.005** | ≈ | 0.987 |
| Granulocytes (% in WBC) | ≈ | 0.324 | ≈ | 0.617 | ≈ | 0.674 | **>** | **0.007** |
| Monocytes (% in WBC) | ≈ | 0.203 | ≈ | 0.204 | **>** | **< 0.001** | **<** | **< 0.001** |
| T helper cells (% in LYM) | ≈ | 0.926 | ≈ | 0.403 | **>** | **< 0.001** | ≈ | 0.097 |
| | ≈ | 0.575 | ≈ | 0.889 | ≈ | 0.924 | ≈ | 0.101 |
| Cytotoxic T cells (% in LYM) | | | | | | | | |
| NK cells (% in LYM) | ≈ | 0.800 | ≈ | 0.766 | **>** | **0.029** | **<** | **0.029** |
| B cells (% in LYM) | ≈ | 0.934 | ≈ | 0.394 | **<** | **0.011** | ≈ | 0.900 |
| Absolute cell count (N/µL) | | | | | | | | |
| Lymphocytes | **<** | **0.044** | ≈ | 0.231 | ≈ | 0.420 | **<** | **< 0.001** |
| Granulocytes | ≈ | 0.561 | ≈ | 0.267 | ≈ | 0.757 | **<** | **< 0.001** |
| Monocytes | ≈ | 0.920 | ≈ | 0.204 | **<** | **0.002** | **<** | **< 0.001** |
| T helper cells | **<** | **0.034** | ≈ | 0.882 | ≈ | 0.996 | **<** | **< 0.001** |
| | ≈ | 0.080 | ≈ | 0.925 | ≈ | 0.439 | **<** | **< 0.001** |
| Cytotoxic T cells | | | | | | | | |
| NK cells | ≈ | 0.266 | ≈ | 0.490 | ≈ | 0.438 | **<** | **< 0.001** |
| B cells | **<** | **0.028** | ≈ | 0.095 | ≈ | 0.140 | **<** | **< 0.001** |
| White blood cells | **<** | **0.042** | ≈ | 0.457 | ≈ | 0.972 | **<** | **< 0.001** |

* *(B vs. C = bug method versus conventional method)*

Finally, cell parameters were compared in a pair-wise approach between blood collected from the same individuals with both methods. Pair-wise comparisons of white blood cell subsets for group B (needle first, bug second) suggested that 11 out of 15 parameters differed between bleeding techniques (table 1). Absolute values of WBC (N/µl) indicated that parameters were mostly lower in

blood obtained by triatomine bugs than in blood obtained conventionally. Since bleeding events were separated by more than 20 minutes in rats of group B, blood samples of group A (bug first, needle second) were used to answer the question if bugs alter white blood cell subpopulations. In group A, conventional bleeding followed almost immediately after triatomine bugs finished their blood meal.

Pair-wise comparisons within group A showed that 6 out of 15 white blood cell subsets of the absolute and the percentage share of concentrations of immune cells differed between bleeding techniques (figure 2, table 1). Three parameters (percentage share of monocytes and T helper cells and NK cells) were higher in blood obtained via triatomine bugs, and three parameters (percentage share of lymphocytes and B cells, and absolute concentration of monocytes) were lower in blood samples obtained via triatomine bugs than in those obtained conventionally (table 1). The levels of determination for the bi-variate relationships showed strong (B cells [% in LYM]: $r^2 = 0.91$) as well as weak (WBC [N/µL]: $r^2 = 0.25$) correlations between white blood cell subpopulations collected via the two techniques (figure 2). The slope of linear regressions calculated after the reduced major axis method differed from unity in 4 out of 15 cases (differing parameters: monocytes in %, monocytes in N/µl, NK cells in %, cytotoxic cells in %).

Our comparison reveals that 4 out of 15 white blood cell subsets (absolute concentrations of lymphocytes, T helper cells, B cells, total white blood cells) were lower in blood samples obtained by bugs. However, since the two bleeding events differed largely in duration, and thus in the imposed stress due to mechanical restraint, the detected differences could not be attributed to either the duration of mechanical restraint or the specific bleeding technique. Presumably, baseline immunological values were obtained from samples taken within two minutes following the onset of mechanical restraint, but blood parameters may got altered when bleeding took longer than three minutes, because of the stress associated with the mechanical restraint of target animals. This notion is supported by previous endocrinological and immunological studies which highlight that stress causes changes in many physiological parameters (GÄRTNER et al., 1980; MARCO and LAVIN, 1999; RILEY, 1981; STEFANSKI and ENGLER, 1998; VOIGT et al., 2004). For example, one important consequence of acute stress is an alteration of blood immune cell numbers mediated by stress-induced release of endocrine mediators. DHABHAR et al. (1995) showed that a variety of white blood cell subpopulations such as T and B cells decreased in concentration in the bloodstream during a 2 h stress period (rats were placed in a Plexiglass restrainer). However, restraint stress was associated with slightly increased numbers of granulocytes. Similar effects on blood immune cells were also described in Long Evans rats exposed to a 2 h social stressor (STEFANSKI, 1998). Thus, the pattern observed in rats restrained for blood sampling in the present study resembles in many aspects the picture of stressed-induced immune changes. Consequently, there is good reason to assume that the leukocyte and lymphocyte subsets of the two study groups differed because blood immune cells were exposed to stress hormone action when bleeding took longer.

When comparing the relative and absolute concentration of white blood cell subsets in the second samples between bleeding techniques, we could not find any differences at all; yet the combined effect of stress imposed by mechanical restraint and the effect of the specific bleeding technique could have obscured any difference, for example by causing a larger variation in the data sets. Therefore, the focus of this study was on the 20 animals of group A that were first bled with triatomine bugs followed by an interval of about 1 min after which blood was obtained from the tail vein using conventional needles. This time lag between the two bleeding events was short enough to attribute possible differences to the bleeding technique alone. Indeed, the relative concentration of white blood cell subsets differed in 6 out of 15 parameters.

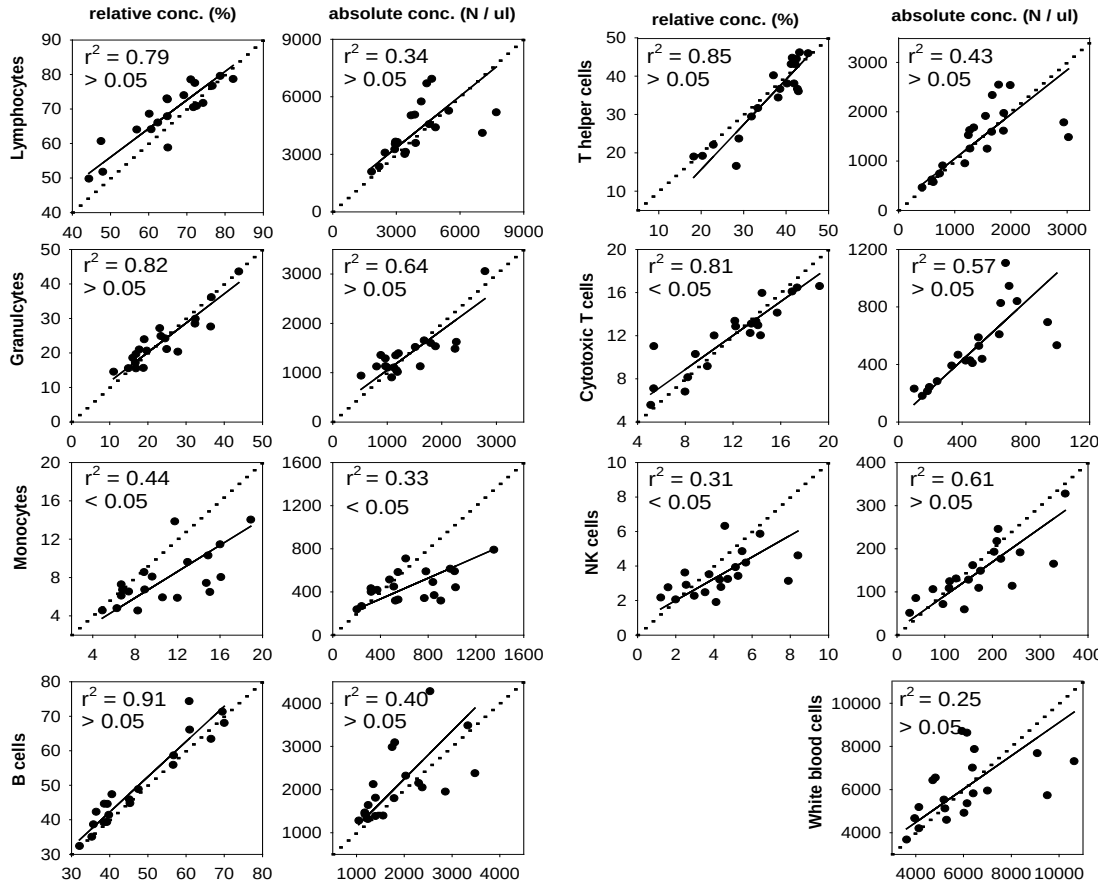


*Fig. 2: Scatterplots of white blood cell subset concentrations in the 20 animals of group A (bug first, needle second): X-axis = concentration of leukocyte subsets in blood obtained by a needle, y-axis = concentration of the corresponding parameter in blood obtained by a bug. The two sets of paired graphs show pair-wise data for relative (%; left graph) and absolute concentrations (N/µl; right graphs) of the corresponding subpopulations. The $r^2$-value indicates the precision and the p-value whether or not the slope of the regression line calculated after the reduced major axis method deviated significantly from the line of equivalence (dotted line).*

In order to test for a systematic deviation of paired values with increasing relative or absolute concentration, a linear regression model was calculated for each measured parameter. The slopes of these regression lines deviated from unity in 4 out of 15 parameters, suggesting that the deviation between the two methods varies with increasing relative or absolute concentration of some leukocyte or lymphocyte subsets. Correlation coefficients revealed on average a poor match between the data obtained via the two bleeding techniques. Most levels of determination were lower than 75 %, only one white blood cell subset (relative proportion of B cells) had a level of determination larger than 90 %. Also, all pair-wise comparisons of absolute concentrations showed a low level of correlation, questioning whether relative concentrations calculated on the basis of potentially biased absolute values may prove to be scientifically sound. In conclusion, bleeding animals by using triatomine bugs may yield blood with biased relative and absolute concentrations of white blood cell subpopulations. Thus, data obtained from bug blood may offer poor or unqualified measures to base diagnostic decisions upon; a finding that corroborates a recent study showing that almost all haematological

parameters, such as platelets, neutrophil, eosinophil and basophil granulocytes, lymphocytes and monocytes numbers, were biased when blood was sampled with blood-sucking bugs (MARKVARDSEN et al., 2012).

One reason for deviating concentrations of subpopulations of white blood cells could be that triatomine bugs may bias cell concentrations in ingested blood, e.g. by mixing or digestion in the bug's digestive tract. However, the mixing of ingested blood with hemolymph or intestinal liquids should not lead to elevated concentrations of some of the white blood cell subsets as observed in three cases (see table 1). This argues against any bias caused by dilution; a notion that is consistent with previous measurements (VOIGT et al., 2003). Another reason for deviating concentrations of subpopulations of white blood cells could be that the bug's saliva contains immunomodulatory substances. Generally, saliva of blood-sucking arthropods contains a rich array of biologically active molecules whose primary function is to counteract the hemostatic mechanism of the target animal (KAMHAWI, 2000; RIBEIRO, 1987). Proteins with immunomodulatory properties have been identified in the saliva of various arthropods like sandflies and ticks (KAMHAWI, 2000; WIKEL and WHELEN, 1986) and also blood-sucking bugs (DEAZAMBUJA et al., 1983). Lastly, it can not be ruled out that differences in leukocyte subsets could arise when triatomines consume blood from distinct peripheral sites, e.g. peripheral versus central blood vessels or arterial versus venous blood vessels. Leukocyte counts are known to differ for example between arterial and venous blood (LUDVIG and DAAE, 1989; YHANG et al., 2001). Conventional sampling yields blood samples that are of predictable origin, whereas bleeding animals with blood-sucking bugs involves blood samples from unpredictable and thus variable origins.

Overall, data obtained from bug blood must be carefully validated before being used for diagnostic health screening of animals. When choosing the most appropriate bleeding technique for a specific animal experiment, it is particularly important to trade the stress-induced bias on leukocyte and lymphocyte subsets using stressful conventional bleeding against a selected bias of white blood cell subsets when using the more gentle bleeding technique with blood-sucking bugs. For a wider application of this bleeding technique it is important to monitor the triatomine bugs for the presence of parasitic protozoans (such as trypanosomes) or bacterial and viral agents to ensure that no accidental and unwanted transmissions occur from target animal to target animal. Also, it seems advisable to ensure that triatomine bugs do not consume an overly amount of blood from relatively small target animals. In summary, white blood cell subsets may get biased after having being exposed to the saliva and the digestive system of triatomine bugs. This fact has to be considered when blood obtained via blood-sucking bugs from wildlife and zoo animals is to be used for diagnostic purposes.

## Acknowledgements

Many thanks go to Kerstin Schunke for the help in planning and carrying out the experiment at the University of Bayreuth, to Doris Fichte (IZW) for assistance and support during this study and to Jürgen W. Streich (IZW) for help in statistical questions.

## References

*ARNOLD JM, OSWALD SA, VOIGT CC, PALME R, BRAASCH A, BAUCH C, BECKER PH (2008): Taking the stress out of blood collection: comparison of field blood-sampling techniques for analysis of baseline corticosterone. J. Avian Biol.* ***39****, 588 - 592.*

*BRAUN BC, FRANK A, DEHNHARD M, VOIGT CC, VARGAS A, GÖRITZ F, JEWGENOW K (2009): Pregnancy diagnosis in urine of Iberian lynx (Lynx pardinus) Theriogenology* ***71****, 754 - 761.*

*DEAZAMBUJA P, GUIMARAES KA, GARCIA ES (1983): Hemolytic factor from the crop of Rhodnius prolixus – evidence and partial characterization. J. Insect Physiol.* ***29****, 833 - 837.*

*DHABHAR FS, MILLER AH, MCEWEN BS, SPENCER RL (1995): Effects of stress on immune cell distribution. Dynamics and hormonal mechanisms. J. Immunol.* ***154****, 5511 - 5527.*

*DYSON DH, MAXIE MG, SCHNURR D (1998): Morbidity and mortality associated with anesthetic management in small animal veterinary practice in Ontario. J. Amer. Anim. Hosp. Association* ***34****, 325 - 335.*

*GÄRTNER K, BÜTTNER D, DÖHLER K, FRIEDEL R, LINDENA J, TRAUTSCHOLD I (1980): Stress response of rats to handling and experimental procedures. Lab. Anim.* ***14****, 267 - 274.*

*KAMHAWI S (2000): The biological and immunomodulatory properties of sand fly saliva and its role in the establishment of Leishmania infections. Microb. Infect.* ***2****, 1765 - 1773.*

*LUDVIG NW, DAAE MD (1989): Different blood particle parameters for samples collected by skin puncture and venously. J. Haematol.* ***43****, 190.*

*MARCO I, LAVIN S (1999): Effects of the method of capture on the haematology and blood chemistry of red deer (Cervus elaphus). Res. Vet. Sci.* ***66****, 81 - 84.*

*MARKVARDSEN SN, KJELGAARD-HANSEN M, RITZ C, SØRENSEN DB (2012): Less invasive blood sampling in the animal laboratory: clinical chemistry and haematology of blood obtained by the triatominae bug Dipetalogaster maximus. Lab. Anim.* ***46****, 136 - 141.*

*MILLSPAUGH JJ, WASHBURN BE (2004): Use fecal glucocorticoid metabolite measures in conservation biology research: considerations for application and interpretation. Gen. Comp. Endocr.* ***138****, 189 - 199.*

*MONASH UNIVERSITY ANIMAL WELFARE COMMITTEE (MUAWC) (2008): Blood collection guidelines.*

*RIBEIRO JM (1987): Vector salivation and parasite transmission. Memorias do Instituto Oswaldo Cruz* ***82****, 1 - 3.*

*RILEY V (1981): Psychoneuroendocrine influences on immunocompetence and neoplasia. Science* ***212****, 1100 - 1109.*

*ROMERO LM, REED JM (2005): Collecting baseline corticosteron samples in the field: is under 3 min good enough? Comp. Biochem. Physiol.* ***140****, 73 - 79.*

*STADLER A, LAWRENZ A, SCHAUB G (2009): The blood-sucking bug Dipetalogaster maxima as mean to obtain blood samples of zoo animal species. Tierärztliche Umschau* ***64****, 147 - 153.*

*STEFANSKI V (1998): Social stress in loser rats: opposite immunological effects in submissive and subdominant males. Physiol. Behav.* ***63****, 605 - 613.*

*STEFANSKI V, ENGLER H (1998): Effects of acute and chronic social stress on blood cellular immunity in rats. Physiol. Behav.* ***64****, 733 - 741.*

*THOMSEN R, VOIGT CC (2006): Non-invasive blood sampling from primates using laboratory-bred blood-sucking bugs (Dipetalogester maximus; Reduviidae, Heteroptera). Primates* ***47****, 397 - 400.*

*VOIGT CC, VON HELVERSEN O, MICHENER RH, KUNZ TH (2003): Validation of a non-invasive blood-sampling technique for doubly-labelled water experiments. J. Exp. Zool.* ***296A****, 87 - 97.*

*VOIGT CC, FASSBENDER M, DEHNHARD M, WIBBELT G, HOFER, H, SCHAUB GA (2004): Validation of a minimally invasive blood-sampling technique for the analysis of hormones in domestic rabbits, Oryctolagus cuniculus (Lagomorpha). Gen. Comp. Endocr.* ***135****, 100 - 107.*

*VOIGT CC, MICHENER R, WIBBELT G, KUNZ TH, VON HELVERSEN O (2005): Blood-sucking bugs as a gentle method for blood-collection in water budget studies using doubly labelled water. Comp. Biochem. Physiol.* ***142****, 318 - 324.*

*VOIGT CC, PESCHEL U, WIBBELT G, FRÖLICH K (2006): An alternative, less invasive blood sample collection technique for serologic studies utilizing Triatomine bugs (Heteroptera; Insecta). J. Wildl. Dis.* ***42****, 466 - 469.*

*VON HELVERSEN O, VOLLETH M, NÚÑEZ J (1986): A new method for obtaining blood from a small mammal without injuring the animal: use of Triatomid bugs. Experientia* ***42****, 809 - 810.*

*VON HOLST D (1998): The concept of stress and its relevance for animal behaviour. Adv. Stud. Behav.* ***27****, 1 - 131.*

*VOS A, MÜLLER T, NEUBERT L, VOIGT CC (2010): Validation of a less invasive blood sampling technique in rabies serology using reduviid bugs (Triatominae, Hemiptera). J. Zoo Wildl. Med.* ***41****, 63 - 68.*

*WELLS RMG, TETENS V, DEVRIES AL (1984): Recovery from stress following capture and anaesthesia of antarctic fish: haematology and blood chemistry. J. Fish Biol.* ***25****, 567 - 576.*

*WIKEL SK, WHELEN CA (1986): Ixodid-host immune interaction. Identification and characterization of relevant antigens and tick-induced host immunosuppression. Veter. Parasit.* ***20****: 149 - 174.*

*YANG ZW, YANG SH, CHEN L, QU J, ZHU J, TANG Z (2001): Comparison of blood counts in venous, fingertip and arterial blood and their measurement variation. Clin. Lab Haematol.* ***23****, 155 - 159.*

# SUSPECTED HAEMOLYTIC DISEASE OF THE NEWBORN IN A WHITE-NAPED MANGABEY (*CERCOCEBUS ATYS* SSP. *LUNULATUS*)

KOHL M, BOURGEOIS A, HANO C, CHAI N

Ménagerie du Jardin des Plantes, National Museum of Natural History, 57 rue Cuvier, 75005 Paris, FRANCE; kohl@mnhn.fr

A 4-days-old male hand-reared White-naped Mangabey (*Cercocebus atys* ssp. *lunulatus*) presented with dyspnoea and severe lethargy. Physical examination revealed hypothermia, tachycardia, tachypnoea, white to yellowish mucous membranes (icterus), undetectable capillary refill time, prolonged skin tenting and sunken eyes, suggesting moderate dehydration. A blood smear showed severe acanthocytosis and spherocytosis with a relative leucocytosis. Due to the small blood sample size, haematology and serum biochemistry were not performed, but the blood smear findings suggested on-going haemolysis. Thoracic radiographs revealed an air-dense tubular structure in the mid thorax. Heart size and shape were considered in the normal range and the lung fields were of normal radio density. On the basis of the history and the clinical findings, a diagnostic hypothesis of haemolytic disease of the newborn was suggested. Supportive treatment consisting of heat supplementation, oxygen therapy, administration of fluids (Ringer-Lactate, (Ringer-Lactate Aguettant®, COOPHAVET, France) 60 ml/kg SC SID and 45 ml/kg oral rehydration solution PO SID (Milupa GES45, SD France, France)), intensive phototherapy, antibiotics (22.5 mg/kg Cephalexin IM BID (Rilexine®, Virbac, France)) and steroids (0.2 mg/kg Dexamethasone IM SID, (Azium®, Intervet, France)) was initiated. Transfusion with the blood of the father was scheduled. The direct haemagglutination test between donor and recipient blood was negative. Ten millilitres whole blood from the adult male was mixed with 0.7 ml citrate and immediately administered intraosseously in the left femur of the newborn under general anaesthesia with Isoflurane (Vetflurane®, Virbac France, France).

The intraosseous route of administration was chosen due to the small size and young age of the individual, as intravenous access was too difficult to obtain and the umbilical vein was no longer patent. Following the transfusion, the animal was treated with 0.2 mg/kg Meloxicam intramuscularly SID (Métacam®, Boehringer Ingelheim, France), 22.5 mg/kg Cephalexin intramuscularly BID and 1 ml/kg of a hepatoprotective amino-acid mixture SC (Ornipural®, Laboratoire Vétoquinol S.A., France). Twelve hours after the transfusion, the mangabey was much more alert, mucous membranes were pink and tachycardia had resolved. One year later, the animal is clinically normal. However, the thoracic air-dense tubular structure is still present and will be the subject of further diagnostic procedures.

# BLOOD REFERENCE VALUES IN CLINICALLY HEALTHY CAPTIVE FOSSAS (*CRYPTOPROCTA FEROX*)

LANGER S, JURCZYNSKI K, WIDMER D

Zoo Duisburg AG, Mülheimerstr. 273, 47058 Duisburg, GERMANY; langers@zoo-duisburg.de

The endemic fossa (*Cryptoprocta ferox*) is the largest extant terrestrial mammal of Madagascar. Zoo Duisburg in Germany has recorded the highest breeding successes in the captive environment since 1994 and is still keeping the largest breeding population. At the end of the year 2011 the world population of *C. ferox* under human care consisted of 130 animals, half of them in Europe and the other half in North America.

Fossas are still not well represented in zoos and because of that there is not much information about this species available. Therefore selected haematologic and serum biochemical values of clinically healthy captive fossas were recorded to provide reference intervals. Moreover blood values were compared between different age classes of fossas and between the two sexes. For this reason blood of 26 (16, 10) clinically healthy fossas living at Zoo Duisburg, Germany, had been collected in two occasions in 2004 and 2011. The animals were net-restrained and anaesthetised with ketamine and medetomidine for a general examination, weight measurement and venipuncture.

The examined data of this study were compared to available data of their closest relatives, especially felids. In comparison to domestic cats the values of the muscle enzymes AST, CK and LDH were extraordinarily high among the fossas, as well as the glucose concentration, cholesterol and the WBC likely attributed to the stressful event of restraint and handling.

Several age-related differences could be observed. The levels of inorganic phosphorus, alkaline phosphatase, glutamate dehydrogenase, creatine kinase, lactate dehydrogenase and calcium were significantly higher in subadult fossas. Regarding the haematological values WBC and RBC were significantly lower in adults than among juveniles. However, there were no statistically significant differences for any parameter between the two sexes.

# ESTIMATION OF A LINEAR MODEL CAPABLE TO PREDICT AGE OF ASIAN ELEPHANTS (*ELEPHAS MAXIMUS INDICUS*) USING DUNG BOLUS CIRCUMFERENCE

LEOPARDI S[1], KERATIMANOCHAYA T[2], SOLMI F[3], ROBERTS J[2]

[1]Veterinarian, 35100 Padova, ITALY; stefania.leopardi@gmail.com
[2]Golden Triangle Asian Elephant Foundation (GTAEF), 229 Moo 1, Chiang Saen, Chiang Rai, 57150, THAILAND
[3]Universiteit Hasselt, Interuniversity Institute for Biostatistics and statistical Bioinformatics, Agoralaan 1, 3590 Diepenbeek, BELGIUM

The measurement of dung size is reported to be a promising technique for estimation of size and age structure in populations of African elephants (*Loxodonta africana*). To the authors' knowledge, only one similar study has been performed in Asia, in a population of *Elephas maximus sumatranus*.
In our work we investigated 25 *Elephas maximus indicus* housed in the GTAEF Elephant camp, Thailand. Age, foot circumference, and multiple measurement of dung's circumference have been recorded for each animal, only using fresh piles to avoid problems due to the decay of dung. A very high correlation emerged between the dung size and both age and foot diameter in adults. A quadratic relation between age and dung size and a more linear one between foot and dung diameter was deduced via graphical means. Given these positive findings, we used our data to estimate the following model capable to predict animal age starting from the dung's size: 〖〖log(y〗_i)=β_1 〖diam〗_i^3+ε〗_i
Statistical tools have been used to test the goodness of fit of such model.
Our model could be used to evaluate age in unknown populations of Asian elephants. Nevertheless, no information are currently available about intraspecies variability of growth rates among Asian elephants, so that application of these findings to other subspecies would be inappropriate.

# COMPARISON OF HAEMATOLOGY AND PLASMA BIOCHEMISTRY PROFILES BETWEEN SURVIVING AND NON-SURVIVING SEA TURTLES IN TAIWAN

LI TH[1,2], CHANG CC [1], CHENG IJ [3]

[1]National Chung Hsing University, Graduate Institute of Microbiology and Public Health, Taichung 250, TAIWAN, REPUBLIC OF CHINA (ROC); lith@nmmba.gov.tw
[2]National Museum of Marine Biology and Aquarium, Checheng, Pingtung 94450, TAIWAN, ROC
[3]National Taiwan Ocean University, Institute of Marine Biology, Keelung 202, TAIWAN, ROC

Sea turtles are included in the International Union for Conservation of Nature (IUCN) red list. In Taiwan, the species of stranded sea turtle include green turtle (*Chelonia mydas*), loggerhead turtle (*Caretta Caretta*), hawksbill turtle (*Eretmochelys imbricata*), leatherback turtle (*Dermochelys coriacea*), and olive Ridley turtle (*Lepidochelys olivacea*). Appropriate rehabilitation care is important for these endangered vertebrates. Health indices are useful for clinical management in sea turtles during convalescence. Blood examinations are commonly used for evaluation of physiological statuses. The objective of this study was to compare haematology and plasma biochemistry profiles between surviving and non-surviving sea turtles. In this study, survivors were turtles that could survive in a non-native environment or can be released after clinical treatment. Stranded turtles that were dead after clinical care were defined as non-survivors. A total of 76 blood samples collected from 70 surviving and 6 non-surviving turtles at the time of capture were analysed. No haemoparasites were detected in blood smears. There were no significant differences of haematologic profiles between surviving and non-surviving sea turtles. However, non-surviving sea turtles had significantly higher aspartate aminotranspherase (AST), gamma glutamyl transferase (GGT), creatinine kinase (CK), uric acid, sodium and chloride values than surviving sea turtles ($P < 0.05$). Levels of total protein, albumin, globulin, total bilirubin, alanine aminotransferase, alkaline phosphatase, lactate dehydrogenase, cholesterol, triglyceride, glucose, creatinine, blood urea nitrogen, phosphorus, calcium, potassium, lactate, iron, and fibrinogen were not significantly different between surviving and non-surviving individuals. These data may be useful to evaluate health conditions of stranded sea turtles and to offer more appropriate veterinary clinical care during the period of rehabilitation.

# BE COOL – ANAESTHESIA INDUCED HYPOTHERMIA IN THE NORTHERN WHITE-BREASTED HEDGEHOG (*ERINACEUS ROUMANICUS*) UNDER FIELD CONDITIONS

LIPTOVSZKY M[1], MOLNÁR V[2], PAPP GV[1], FÖLDVÁRI G[3], TÓTH-RONKAY M[4]

[1]ZooMedica, Brassói u. 10/A., 1223 Budapest, HUNGARY; liptovszky@zoomedica.hu
[2]Budapest Zoo and Botanical Garden, Állatkerti krt. 6-12., 1146 Budapest HUNGARY
[3]Szent István University, Faculty of Veterinary Science, Dept. of Parasitology and Zoology, István u. 2, 1074 Budapest, HUNGARY
[4]Hungarian Natural History Museum, Mammal Collection, Ludovika tér 6, 1083 Budapest, HUNGARY

Hedgehogs (especially the European hedgehog, *Erinaceus europaeus*) are told to be the most commonly rescued wild mammal of the world. Despite of the number of rescued animals and decades of practical experience with this species, we have limited data regarding the anaesthesia and the effects of field studies on the health of these animals.

Northern White-breasted hedgehogs (*Erinaceus roumanicus*) were captured and anaesthetised for a capture-mark-recapture field study in a city park of Budapest, Hungary, between July and September 2011. Anaesthesia was induced with a combination of 5 mg/kg ketamine and 0.05 mg/kg dexmedetomidine given intramuscularly and were antagonised using 0.25 mg/kg atipamezole. Anaesthetised animals were marked (ear-tagged) individually and basic biomedical measurements, as well as blood and faecal samples were taken, and a thorough check-up for ectoparasites and oral health assessment were carried out. Average time from induction to administration of atipamezole was 34 minutes (range: 21 - 55 minutes). A total of 38 animals (18 males and 20 females) were included in the temperature checking experiment to study the effect of anaesthesia on core body temperature of a hibernating species under field conditions. Rectal temperature was taken first when animals uncurled as an effect of induction drugs and second time immediately before the finish of anaesthesia. At the same time ambient temperature was also recorded.

Average weight of animals was 624 g, ranging from 230 g to 1082 g. Average starting rectal temperature was 35.7°C, while average end rectal temperature was 33.9°C. Average rectal temperature drop was 1.8°C (per 34 minutes), while ambient temperature (average = 22.7°C, range = 19 - 29.8°C) only dropped by 0.5°C in the same time. There was no significant difference between males and females. End rectal temperature was significantly correlated with starting and end ambient temperature, starting rectal temperature and time from induction. No correlation was found between core temperature drop and ambient temperature drop, while body weight correlated significantly with core temperature drop only in males. All of the animals woke up within 30 minutes after atipamezole administration and no anaesthesia related mortality was recorded. Anaesthesia induced hypothermia could have serious effects, including but not limited to delayed metabolism of anaesthetic drugs, coagulopathies, immunosuppression and delayed wound healing. Hibernating species, as hedgehogs, use repeated controlled hypothermic periods to survive in nature, though this does not necessarily mean, that they are not affected by this phenomenon. Hibernating hamsters and bats have a decline in immune function, when their core body temperature is considered hypothermic. This study was able to collect only baseline data in a hibernator species, and further, more detailed studies are needed to fully understand the effect of hypothermia in field anaesthesia of wild animals.

# SEMEN COLLECTION VIA URETHRAL CATHETER IN EXOTIC FELINE AND CANINE SPECIES: A SIMPLE ALTERNATIVE TO ELECTROEJACULATION

LUEDERS I[1,2,3], LUTHER I[2,3], MÜLLER K[4], SCHEEPERS G[5], TORDIFFE A[3], VAN DER HORST G[2,3]

[1]GEOlifes - Animal Fertility and Reproductive Research, Frohmestr. 7, 22457 Hamburg, GERMANY; imke.lueders@geolifes.com
[2]University of the Western Cape, Dept. of Medical Biosciences, Private Bag X17, Bellville 7535, SOUTH AFRICA
[3]National Zoological Gardens of South Africa, 323 Boomstreet, Pretoria 0110, SOUTH AFRICA
[4]Leibniz Institute of Zoo and Wildlife Research (IZW), Alfred-Kowalke-Str. 17, 10315 Berlin, GERMANY
[5]Zodiac Diereklinie k, P.O. Box 460, Brits 0250, SOUTH AFRICA

## Summary

Semen collection was achieved in different feline and canine species by employing an urethral catheter under general anaesthesia with a medetomidine combination. Via capillary forces, semen that is released into the urethra could be collected within the catheter lumen. Although the retrieved samples were of low volume, the sperm concentration was usually very high and therefore ideally for research, insemination or freezing trials.

## Introduction

Semen collection is required in zoo and wild animals for reasons such as reproductive assessment, sperm sample generation for artificial insemination or cryopreservation. For wild canids and felids, electroejaculation (EE) is the most common method to retrieve an ejaculate. Although this method is quite established, it has some disadvantages: (I) EE requires relatively expensive equipment; (II) the strong contractions induced by electric stimulation of the prostate and surrounding nerves may result in hyperthermia as well as uncontrolled movements and squeals of the patient despite general anaesthesia and (III) the contraction of the bladder, resulting in urine contamination of the ejaculate; (IV) larger volumes of seminal plasma, which are usually detrimental for freezing.
Therefore, we explored a different approach which has been previously described to retrieve semen in domestic cats (ZAMBELLI et al., 2008) and uses simple urethral catheterisation (UC).

## Material and methods

We tested the UC method in lion (*Panthera leo*), cheetah (*Ancinonyx jubatus*), leopard (*Panthera pardus*), snow leopard (*Panthera uncia*), tiger (*Panthera tigris*) and Asian golden cat (*Catofelis temmincki*) as well as in an African wild dog (*Lycaon pictus*) and a maned wolf (*Chrysocyon brachyurus*). For applying this method, the animals were anaesthetised with a variety of anaesthetic drugs always in combination with medetomidine (see table 1). With a regular commercial dog urethral catheter (Buster, sterile dog catheter, WDT, Garbsen, Germany; outer diameter from 1.3 to 3.3 mm, depending on species, see table 1) the sperm may simply be collected via capillary forces. Via transrectal ultrasound with a linear probe (10 MHz), the prostate was located and the progress of the

catheter monitored. Sperm parameters were assessed by CASA (Computer Assisted Semen Analysis) or microscopy at 20 times magnification (table 1).

*Tab. 1: Parameters of semen collected via urethral catheterisation from captive canine and feline species. Ejaculates were evaluated via CASA or * microscopy.*

| Species | *n* | Cathe-ter dia-meter (mm) | Depth of catheter insertion (cm) | Volume (µl) | Concentr. ( x10$^6$/ml) | Motile sperm (%) | Progr. Motile sperm (%) | Total drug dosage | Remark |
|---|---|---|---|---|---|---|---|---|---|
| *Felid* | | | | | | | | | |
| **Lion** | 7 | 2.6-3.3 | 30-40 | 100-1000 | 130-4860 | 62.5-97.2 | 35-96 | 12 mg Medetomidine 150 mg Ketamin | |
| **Tiger** | 2 | 3.3 | 30-40 | 50-300 | 0-2500 | 0-84.6 | 0-67 | 4 mg Medetomidine 120 mg Zoletil | one male infertile, no sperm re-trieved |
| **African leopard** | 1 | 2.6 | 30 | 250 | 635 | 92 | 59 | 2 mg Medetomidine 10 mg Midazolam 15 mg Butorphanol | |
| **Snow leopard*** | 1 | 2.6 | 30 | 500 | 3.1 | 40 | 10 | 1.5 mg Medetomidine 100 mg Ketamin | mated prior collec-tion |
| **Cheetah*** | 2 | 2.2 | 25 | 50-100 | 0-455 | 0-60 | 0-45 | 2 mg Medetomidine 80 mg Ketamin | one male pre-puber-tal, just fluids |
| **Golden cat*** | 1 | 1.3 | 12 | 250 | 70.6 | 65 | 35 | 0.8 mg Medetomidine 75 mg Ketamin | |
| *Canid* | | | | | | | | | |
| **African wild dog** | 1 | 2.6 | 30 | 400 | 540 | 93 | 82 | 1mg Medetomidine 30 mg Zoletil® | |
| **Maned wolf** | 1 | 2.6 | 35 | 100 | 10.0 | 40 | 30 | 0.5 mg Medetomidine 50 mg Ketamin 5 mg Butorphanol | |

## Results and discussion

Medetomidine (like any α2-agonist) is believed to have an effect on the smooth muscle of the ductus deferens. This results in a release of sperm into the urethra, where it was collected with the urethral catheter. Sperm volumes collected via UC ranged from 50 to 1000 µl. The samples in all species were generally characterised by high concentration and low volume, which is due to a reduced amount of seminal plasma (table 1) compared to EE ejaculates. Thus, these semen samples may be used directly for intrauterine artificial insemination or cryopreservation.

We found that the following pre-conditions for this semen collection method need to be respected: 1. The mature male needs to be separated from females at least three days prior to collection to avoid mating and therefore an emptied ductus deferens; 2. Prior to anaesthesia, all distress should be avoided; 3. After anaesthetic induction, there should be a delay of at least 40 minutes before sample collection is attempted. This will allow the semen to be released into the urethra.
Our preliminary results indicate that UC under medetomidine-combined anaesthesia appears as a field friendly and effective method to attain highly concentrated semen samples with excellent motility in lions (LUEDERS et al., 2012) and several other wild felids and canids and may be an alternative when electroejaculation is not possible. However, fertilisation and cryopreservation abilities of the sperm collected via UC need to be determined.

## References

*LUEDERS I, LUTHER I, SCHEEPERS G, VAN DER HORST G (2012): Improved semen collection method for wild felids: Urethral catheterization yields high sperm quality in African lions (Panthera leo). Theriogenology **78**, 696 - 701.*

*ZAMBELLI D, PRATI F, CUNTO M, IACONO E, MERLO B (2008): Quality and in vitro fertilizing ability of cryopreserved cat spermatozoa obtained by urethral catheterization after medetomidine administration. Theriogenology **69**, 485 - 490.*

# SERO-EPIDEMIOLOGICAL SURVEY FOR BRUCELLOSIS, LEPTOSPIROSIS AND TOXOPLASMOSIS IN FREE-RANGING BLACK HOWLER MONKEYS (*ALOUATTA CARAYA*) AND BLACK-TUFTED-EAR MARMOSETS (*CALLITHRIX PENICILLATA*) FROM SAO JOAQUIM DA BARRA CITY, STATE OF SÃO PAULO, BRAZIL

MOLINA CV[1], BUENO MG[1,2], FERREIRA NETO JS[3], VASCONCELLOS SA[3], GENNARI SM[3], VALLE RR[4], SOUZA GO[3], MORAIS ZM[3], VITALIANO SN[3], CATÃO-DIAS JL[1]

[1]Universidade de São Paulo, Faculdade de Medicina Veterinária e Zootecnia, Laboratório de Patologia Comparada de Animais Selvagens – LAPCOM - Av. Prof. Dr. Orlando Marques de Paiva 87, 05508-270 Cidade Universitária, São Paulo, BRAZIL; camolina.vet@gmail.com

[2]Instituto Pri-Matas para Conservação da Biodiversidade, Belo Horizonte, Minas Gerais, BRAZIL

[3]Universidade de São Paulo, Faculdade de Medicina Veterinária e Zootecnia, Departamento de Medicina Veterinária Preventiva e Saúde Animal, Av. Prof. Dr. Orlando Marques de Paiva 87, 05508-270 Cidade Universitária, São Paulo, BRAZIL

[4]Universidade Paulista, Wildlife Management, Rua Domingos Mazzeu 105, apto 102A, 05343-070 Vila Lageado, São Paulo, Brazil, Rua Tenente Julio Prado Neves 965, 02370-000 Cantareira, São Paulo, BRAZIL

Disease prevalence in wild populations is apparently increasing. Risk factors such as habitat fragmentation, increased contact with domestic animals and humans, and release or translocation processes have all been linked to growing pathogen spread, including emerging zoonotic diseases. Thus health assessment of free-ranging animals has a great value due to threats experienced by these species and their risk of extinction. This study evaluated the presence of antibodies (IgG) for, brucellosis, leptospirosis and toxoplasmosis in sera samples of 20 black howler monkeys (*Alouatta caraya*) and 48 black-tufted-ear marmosets (*Callithrix penicillata*) from a fauna rescue programme of a small hydroelectric in a fragmented area of Atlantic forest in São Paulo state, Brazil. Clinical evaluation showed that all animals were apparently health at the moment of blood sampling. Sera were tested for antibodies of *Brucella* spp., *Leptospira* spp. and *Toxoplasma gondii* by the Rose Bengal Plate Test using whole *B. abortus* cells, Microscopic Seroaglutination Test using 24 *Leptospira* spp. serovars, and by the Modified Agglutination test, respectively. All animals were negative for the presence of anti-*Brucella* and anti-*Leptospira* antibodies. However, 75 % (15/20; 95 % IC: 51 % - 91.3 %) of *A. caraya* showed antibodies to *T. gondii* with titres ranging from 25 to 1600. For *C. penicillata*, 16.6 % (8/48; 95 % IC: 7.5 % - 30.2 %) were positive, showing titres of 25. Toxoplasmosis is a frequently reported disease affecting New World primates (NWP) in captivity, being responsible for multiple outbreaks with variable mortality rates. However, the information regarding this disease in free-ranging platyrrhines is scarce. The presence of positive *T. gondii* antibody titres indicates the circulation of this zoonotic pathogen in the area, but the effect of this on the studied NWP populations requires more epidemiological investigation. The present study provides pathogen exposure data for future comparisons with other populations in fragmented habitats and those that have been modified due to anthropogenic actions (FAPESP 2010/51801-5; 2009/51466-4; 2011/08149-8).

# CHRONIC LYMPHOCYTIC LEUKAEMIA IN AN AFRICAN LION (*PANTHERA LEO*)

MEOLI R[1], ELENI C[1], COCUMELLI C[1], CAVICCHIO P[2], TONNICCHIA MC[2], ROSSI G[3]

[1]Istituto Zooprofilattico Sperimentale delle Regioni Lazio e Toscana, Via Appia Nuova, 1411 – 00178 Rome, ITALY; roberta.meoli@izslt.it
[2]Società Zoologica di Pistoia, via Pieve a Celle 160/a, 51100 Pistoia, ITALY
[3]University of Camerino, School of Veterinary Medical Science, Via Circonvallazione 93/95, 62024 Matelica (MC), ITALY

Chronic leukaemia in man is a common and relatively benign neoplasm that typically affects older people. The disease progresses slowly, with a typical accumulation of mature, well-differentiated lymphocytes in various tissues. Until now, only three cases of T cell chronic lymphocytic leukaemia has been described in African lions (*Panthera leo*). We describe a case of B cell chronic lymphocytic leukaemia occurred in a 15–years-old female African lion, maintained at Zoological Garden of Pistoia (Italy). The lioness showed systemic malaise, dyspnea, tremors, anaemic mucosae, and ataxia for two days before death. Ultrasonographic examination of the abdomen found diffuse, uniform and severe splenomegaly.

Complete blood count showed anaemia (4,500,000 red cells per $mm^3$) and severe lymphocytosis (82,940 lymphocytes/150,800 white cells per $mm^3$). Biochemical parameters showed that BUN and ALT were high, while ALB and glucose were low; rapid tests for FIV-FELV and filaria were negative. At necropsy the spleen weighed 7.5 kg, showed rounded edges, dark colour and increased consistency.

Histologically, high amount of neoplastic lymphocytes diffusely infiltrated different organs as spleen, liver, heart, pancreas, kidney, and lung. The most relevant infiltrates were seen in spleen (60 % of involvement). The neoplastic lymphocytes were characterised by small size (6.5/7.5 microns), moderate pale cytoplasm and azurophilic granules, small nuclei (moderate N/C ratio), absence of nucleoli and coarsely aggregated chromatin. Mitotic index was low. Immunohistochemically, the lymphoid cells were constantly positive for CD79a and negative for CD3. To our knowledge this is the first case of B cell chronic lymphocytic leukaemia described in an African lion.

# 3D ADRENAL ULTRASOUND – A NEW APPROACH FOR THE EVALUATION OF STRESS IN THE CRITICALLY ENDANGERED IBERIAN LYNX EX-SITU POPULATION

PAINER J[1], JEWGENOW K[1], GONÇALVES N[2], SERRA R[2], CANALES R[3], PEREZ M[4], MENDOZA JL[5] HILDEBRANDT TB[1], GÖRITZ F[1]

[1]Leibniz Institute for Zoo and Wildlife Research (IZW), Alfred-Kowalke-Str. 17, 10315 Berlin, GERMANY; painer@izw-berlin.de
[2]Centro Nacional de Reprodução de Lince Ibérico, Caixa Postal 215-F, Vale Fuzeiros, 8375-082 São Bartolomeu de Messines, PORTUGAL
[3]El Acebuche Iberian lynx breeding centre, Doñana National Park, 21760 Matalascañas, SPAIN
[4]Centro de Cría La Olivilla, Santa Elena, Jaén, SPAIN
[5]Centro de Cría de "Granadilla", 10710 Zarza de Granadilla (Cácares), SPAIN

3D ultrasound is used routinely in human medicine for prenatal diagnostics and to assess the exact topography of organs and their function. We considered its potentials to evaluate the ratio between adrenal cortical and medullary region in a reliable and repetitive way. During health check-ups of Iberian lynxes (*Lynx pardinus*) at the Iberian lynx conservation breeding program (ILCBP), ultrasound data were collected once or twice a year since 2005. Apart from reproductive assessments, all other abdominal organs were checked for abnormalities. Interestingly, we found remarkable individual changes in size and shape of adrenal glands and a high amount of nodular hyperplasia appearances. First comparisons will show, if size of adrenal glands can potentially reflect their stress level. In this study we included data from the veterinary examinations, performed in November 2012 on 14 captive Iberian lynxes. Reproducible qualities of 2D and 3D ultrasonographic datasets were available from all 14 individuals. Our project was designed to compare evaluation reliabilities between 2D and 3D adrenal gland assessments. Furthermore we wanted to test if the ratio between cortex and medulla can be used in future as a link to the individual's characteristic behaviours towards stressful events and daily confrontations. For this preliminary study we did not make comparisons to serum or faecal stress values. To our knowledge there is no veterinary study performed on evaluating the level of stress by measuring 3D ultrasonographic viewpoints of adrenal glands. We would like to present this new approach for the evaluation of well-being in these captive breeding animals.

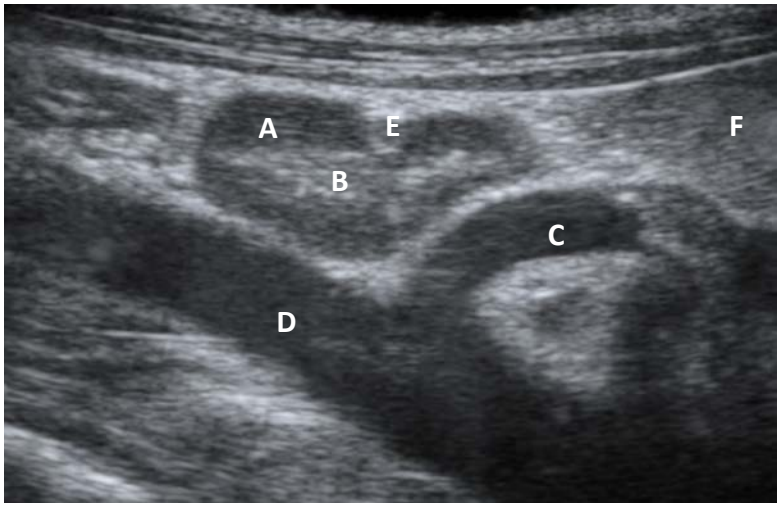


*Fig. 1: Adrenal gland of an Iberian lynx in 2D ultrasound.*
*A: adrenal gland cortex,*
*B: adrenal gland medulla,*
*C: Arteria renalis,*
*D: Aorta,*
*E: entrance of adrenal vessels,*
*F: spleen.*

# HELMINTH INFECTIONS OF WILD BOARS (*SUS SCROFA*) IN HUNTING GROUNDS IN CENTRAL SERBIA

PAVLOVIĆ I[1], DJORDJEVIĆ M [2], KULIŠIĆ Z[2]

[1]Scientific Veterinary Institute of Serbia, Vojvode Toze 14, 11000 Belgrade, SERBIJA;
dr_ivanp@yahoo.com
[2] Faculty of Veterinary Medicine, Bul.Oslobodjenja 18, 11000 Belgrade, SERBIJA

The present study aimed to investigate the status of helminth infections in wild boars in the hunting grounds in central Serbia. For this purpose, during 2009 - 2012, we examined 270 faecal samples and performed necropsies of 97 wild boars, hunted at 12 hunting grounds.

Twelve helminth species were detected, with the following prevalence rates: *Metastrongylus pudendotectus* (42 %), *Metastrongylus apri* (39 %), *Ascaris suum* (29 %), *Macracanthorhynchus hirudinaceus* (22 %), *Globocephalus urosubulatus* (15.1 %), *Hyostrongylus rubidus* (14.5 %), *Oesophagostomoum dentatum* (11 %), *Physocephalus sexalatus* (7 %), *Trichuris suis* (9 %), *Fasciola hepatica* (1.1 %), *Taenia hydatigena* larvae (4 %) and larvae of *Echinococcus granulosus* (3.6 %). Generally, lungworms were the predominant helminths. The highest mean abundance was observed for *M. pudendotectus,* and the lowest was determined for *Fasciola hepatica.*

Differences in the prevalence of infection, determined for animals up to one year old, one to two year(s) olds as well as adults, were minimal for *Metastrongylus* spp. and *Macracanthorhynchus hirudinaceus.* However, *P. sexalatus, T. suis* and *A. suum*, occurred more often in 1-year old animals, whereas *H. rubidus, O. dentatum* and *Fasciola hepatica* were isolated more often from adults. A correlation of the infection rate with the sex of the animals was not found.

Prevalence and species of trichinellosis are separately examined and not the goal of those works.

# FIRST OCCURRENCE OF TICKS *HAEMAPHYSALIS PUNCTATA* ON THE EUROPEAN GREEN LIZARD (*LACERTA VIRIDIS*) IN SERBIA

PAVLOVIĆ I[1], ŠEKLER M[2], VIDANOVIĆ D[2], OBRADOVIĆ S[3], KURČUBIĆ V[4]

[1]Scientific Veterinary Institute of Serbia, Vojvode Toze 14, 11000 Belgrade, SERBIJA; dr_ivanp@yahoo.com
[2]Veterinary Institute Kraljevo, Žička 34, 36000 Kraljevo, SERBIJA
[3]Faculty for Economics and Engineering Management Cvećarska 2, 21000 Novi Sad, SERBIJA
[4]Agronomony Faculty Čačak, Cara Dušana 34, 32000 Čačak, SERBIJA

## Summary

During 2012 a project was performed named "Diversity of amphibians and reptiles in national park Đerdap" financed by the Department of Environmental Protection of Republic Serbia. During this project we established the examination of lizard species, the most abundant were European green lizards *Lacerta viridis.* We investigated its infection with ticks *Haemaphysalis punctata* and present the first occurrence of tick infestation of green lizard in Serbia.

## Introduction

The study area of the "Diversity of amphibians and reptiles in national park Đerdap" project is the Nacionalni park Đerdap, which stretches along the eastern bank of the Danube River. The total area of the National Park is 63.600 ha and the protection zone consists of another 93.968 ha (ŠEHIĆ and ŠEHIĆ, 2007). Thanks to the sheltered position of the Iron Gates more than 60 forest and shrub communities have been preserved, many of which are relics of previous, tertiary forest communities. Rare animal and bird species can also be found in the National Park including bear, lynx, wolf, jackal, grey eagle, short-eared owl, black stork etc. (ŠEHIĆ and ŠEHIĆ, 2007).

Our examinations were performed in the following location: Vidikovac Kovilovo, Ploče, Budićeva vodenica and on chops of a Boljetinska river. We caught and measured various species of amphibians and reptiles and sampled material for their health control.

The European green lizard *Lacerta viridis* were the most abundant lizard species. This is a large lizard distributed across Europe from Slovenia and eastern Austria to as far east as the Black Sea coasts of Ukraine and Turkey. The lizard is often seen sunning on rocks or lawns, or sheltering amongst bushy vegetation at woodland and field edges, within open woodlands, forested areas and shrub land, hedgerows, and in overgrown areas and cultivated land including orchards. It takes refuge in bushes and burrows. The lizard reaches up to 13 cm from the tip of the muzzle to the cloaca. The tail can be up to twice the length of the body (CRNOBRNJA ISAILOVIC et al., 2012). The male has a larger head and a uniform green colouring punctuated with small spots that are more pronounced upon its back. In Serbia, they are a wide spread lizard species, occurring in all parts of the country.

Parasite infections of lizards are rarely described, especially tick infestation. In our paper we present the first occurrence of tick infestation of the green lizard in Serbia.

## Material and methods

Ticks were collected from four lizards by lightly sprung forceps. All specimens were placed into glass bottles which had a piece of hard paper inserted bearing the name of the capture location of the infested lizards, the name of the lizard and date and hour of collection. The tick species were identified using keys given by POMERANCEV (1950) and KAPUSTIN (1955).

## Results and discussion

Ticks were found on all examined lizards and the rate of infection was two to five ticks. All ticks were adult *Haemaphysalis punctata*. Female ticks predominated. Female ticks were 3.0 to 3.5 mm, male ticks were 2.8 to 3.2 mm long. *H. punctata* parasitises birds, occasionally small mammals, predators, and very rarely reptiles including lizards (CARPENTER and WILSON, 1996). Their distribution stretches between southern Scandinavia, British Isles, Spain to North Africa and Central Asia. There were spring and late summer peaks of activity. It seems probable that the complete life cycle of *H. punctata* takes two or three years in this habitat. The activity of *H. punctata* has spring and late summer peaks.
In Serbia, *H. punctata* occurs on cattle, small ruminants, horses, dogs and wild ungulates (PETROVIĆ et al., 1996; MILUTINOVIĆ et al., 1996/97; 1998). During examinations performed in 1998, *H. punctata* was found on foxes and badgers hunted in Belgrade area (PAVLOVIĆ et al., 1998). Confirmation that *H. punctata* may infect reptiles we found in Belgrade zoo where an accidental infection of python (*Python molurus*) and sand boa (*Boa constrictor*) (PAVLOVIĆ et al., 1999) occurred.
Our findings present the first detection of *H. punctata* on European green lizards, *Lacerta viridis*, in Serbia and the Balkan Peninsula.

## References


*CARPENTER JW, WILSON SC (1996): Parasitic and Infectious Diseases of Reptiles. Presented at the Wildlife, Exotic Zoo Animal Medicine Conference. Madison, WI, **13**.*

*CRNOBRNJA ISAILOVIC J, VOGRIN M, CORTI C, PÉREZ MELLADO V, SÁ-SOUSA P, CHEYLAN M, PLEGUEZUELOS J, KONRAD NETTMANN H, STERIJOVSKI B, LYMBERAKIS P, PODLOUCKY R, COGALNICEANU D, AVCI A (2009): Lacerta viridis. In: IUCN 2012. IUCN Red List of Threatened Species. Version 2012.2.*

*KAPUSTIN FU (1955): Atlas parazitov krovi životnih i klešćei iksodid. Moskva: Gasudarstvenoe izdetejlstvo seljskohazjajstvenoi literaturi, 118 - 127.*

*MILUTINOVIĆ M, PETROVIĆ Z, BOBIĆ B, PAVLOVIĆ I (1996 - 1997): Ecological notes on ticks (Acari: Ixodida) collected in West Serbia, Yugoslavia Parasitolog. Hungarica **29/30**, 67 - 74.*

*MILUTINOVIĆ M, ALEKSIĆ-BAKRAČ N, PAVLOVIĆ I (1998): Faunistic and ecological notes on ticks (Acari: Ixodidae, Argasidae) in the extended area of Belgrade. Magy. Állator. Lapja **120**, 434 - 436.*

*PAVLOVIĆ I, MILUTINOVIĆ M, KULIŠIĆ Z, DIMITRIĆ A (1998): Tick (Acari: Ixodidae) of fox and badgers hunting in Belgrade area. Abstr. VIIIth Symp. DDD in Public Health Belgrade, 162 - 168.*

*PAVLOVIĆ I, MILUTINOVIC M (1999): Infestation of python (Python molurus) and sand boa (Boa constrictor) with ticks Haemophysalis punctata (Canestrini & Fanzago, 1877) Abstr. Symp. Entolol.Serbia 99, Goč, 21.-23.10.1999, 48.*

*PETROVIC Z, MILUTINOVIC M, PAVLOVIĆ I (1996): Examination of ticks (Acari: Ixodidae, Argasidae) in Yugoslavia. In: Petrović Z (Eds.): Akademik Čedomir P.Simić, naučni skup posvećen 100. godišnjici rođenja SANU, Odeljenje mecidinskih nauka i Jugoslovensko društvo parazitologa, Beograd, 96 - 101.*

*POMERANCEV BL (1950): Fauna SSSR. Paukobraznie. Iksodovie kleščei (Ixodidae). Izd. Akademem Nauk SSSR, Moskva-Leningrad **4**, 2 - 15.*

*ŠEHIĆ D, ŠEHIĆ D (2007): Atlas Srbije. Beograd: Politika A.D., 27 - 31. Gasudarstvenoe izdetejlstvo seljskohazjajstvenoi literaturi, 118 - 127.*

# CARIOSPOROSIS AT *FALCO PEREGRINUS* IN SERBIA – CASE REPORT

PAVLOVIĆ M[1], PAVLOVIĆ I[2], KULIŠIĆ Z[1], JAKIĆ-DIMIĆ D[2]

[1]Faculty of Veterinary Medicine, Bul.Oslobodjenja 18, 11000 Belgrade, SERBIJA;
misapavlovic43@gmail.com
[2]Scientific Veterinary Institute of Serbia, VojvodeToze 14, 11000 Belgrade, SERBIJA

In south-west part of Serbia, in Subotica area, has a tradition of falcons breeding. A preliminary protozoology survey was carried out in captive falcons breed this area.
During 2011 and 2012, faecal samples of 17 Peregrine falcons (*Falco peregrinus*) were examined for parasites using faecal flotation in Sheather's sugar solution. All positive samples were allowed to sporulate in a thin layer of 2.5 % (w/v) aqueous potassium dichromate solution at laboratory temperature, 23°C and 30 sporulated oocysts were measured using bright-field microscopy (100 x objective) equipped with a calibrated ocular micrometer to obtain morphologic data. Isolated oocysts were examined and photographed. Morphologically, we determinated *Caryospora kutzeri*.
Among 17 examined birds 8 (47.05 %) were found to be passing coccidian oocysts. These birds were long term captives. However, affected falcons with high parasitic levels of *Caryospora* spp. may show typically symptoms of disease including regurgitation, haemorrhagic faeces, depression, and reduced appetite. Peracute or acute death with or without clinical signs might have also occurred in two birds at an age of 28 to 55 days. Most clinical disease and the incidence of high levels of oocyte shedding is said to be found in birds less than three months of age.

# BACTERIAL LEPTOMENINGITIS IN A LESSER MOUSE DEER (*TRAGULUS JAVANICUS*)

PERRIN K[1], BARROWS M[1], KILLICK R[1], STIDWORTHY M[2], WYATT K[1]

[1]Bristol Zoo Gardens, Clifton, Bristol, BS8 3HA, UK; kathrynperrin@hotmail.com
[2]International Zoo Veterinary Group, Station House, Parkwood Street, Keighley, BD21 4NQ, UK

Lesser Mouse Deer (*Tragulus javanicus*) originate from the island of Java, Indonesia. They are listed as data deficient by the International Union for Conservation of Nature. This is due to confusion over taxonomy classification of chevrotain species on this island. It is believed that the 'vulnerable' category is likely to be applicable. Bacterial meningitis is commonly reported in neonatal ruminants however is less common in adults. Early detection and aggressive therapy is important for a successful outcome. Even with this the prognosis is poor. This case study is the first report of the clinical presentation and diagnostics of a fatal case of bacterial meningitis in this species.

A 5-years-old male, captive bred, Lesser Mouse Deer was presented to the veterinary department of a UK zoo following a reported head trauma. The individual had been startled by a keeper entering the enclosure and as a result, run into a tree. Initially he was recumbent with a head tremor but was making attempts to stand. A dose of 1 mg/kg Dexamethasone (Dexadresson, MSD Animal Health, UK) was given intramuscularly, but there was no improvement over the next 60 minutes. Anaesthesia was induced for blood sampling, radiography and supportive therapy. The results were unremarkable with no signs of traumatic damage to the skull or spine. During recovery from anaesthesia the deer suffered a cardiac arrest and died. A necropsy examination was performed immediately. There were multiple large contusions to the lungs but otherwise gross findings were largely within normal limits. Histopathology diagnosed an acute, suppurative cerebral and spinal leptomeningitis. A mild suppurative interstitial pneumonia and neutrophilic glomerulitis was also present. The character of the inflammation was consistent with an acute bacterial infection. It therefore seems likely that this animal suffered a head trauma following neurological deterioration of its vision rather than trauma being the inciting cause.

Bacterial meningitis should be considered as a differential diagnosis in Lesser Mouse Deer who exhibit neurological symptoms including vision deficits.

# GASTROLITH IN A YELLOW SPOTTED AMAZON RIVER TURTLE (*PODOCNEMIS UNIFILIS*)

PERRIN K[1], SAUNDERS R[1], BARROWS M[1], HALL SR[2], WYATT K[1]

[1]Bristol Zoo Gardens, Clifton, Bristol, BS8 3HA, UK; kathrynperrin@hotmail.com
[2]University of Bristol, School of Chemistry, Complex Functional Materials Group, Cantock's Close, Bristol, BS8 1TS, UK

A routine health examination of a healthy, 1.75 kg, 9-years-old captive bred Yellow Spotted Amazon River turtle (*Podocnemis unifilis*) revealed a 4.5x3.5x3.2 cm, lamellar, mineral opacity mass in the mid-coelom. The mass was identified by radiography and located in the stomach before being surgically removed. Electron microscopy, energy dispersive X-ray analysis and powder X-ray crystallography showed the mass to be a necrotic organic core surrounded by mineralised material primarily consisting of calcium carbonate.

The turtle was housed in a mixed exhibit at a UK zoo. Feeding took place three times per week and consisted of de-shelled snails (*Helix aspersa*), mice, fish, worms, fruits, vegetables, tortoise pellets (Komodo Tortoise diet, Underworld Products) and fish pellets (Aquatic Number 3, Special Diet Services). Gut loaded insects were dusted with a calcium supplement (Nutrobal, Vetark Professional) and sprinkled onto the water a few times per week. The calcium supplementation was not deemed to be excessive as four other turtles from the same exhibit (two *P. unifilis* and two *Phrynops geoffroanus*) were examined at the same time (including radiography) with no abnormalities found. In addition to the fed diet the pool housed numerous free-ranging Malaysian Trumpet Snails (*Melanoides tuberculata*). The pre-surgery radiographs of the affected turtle show the calculus to be surrounded by diffuse mineral opacity structures which resemble snail shells. It is believed that the calculus developed inside the stomach due to excessive ingestion of these free-living snails and their shells. The calculus is likely to have been too big to have been ingested by a turtle with a plastron length of just 21.4 cm.

The turtle recovered well and a follow-up radiograph ten months later showed no signs of recurrence. To our knowledge this report describes the first case of a gastrolith in a reptile with this aetiology.

*Fig. 1: Dorsoventral radiograph showing lamellar, mineralised structure within the coelom. (Photo: Author - Bristol Zoo Gardens).*

# MYCOTIC SCROTAL GRANULOMA IN A DROMEDARY CAMEL (*CAMELUS DROMEDARIUS*)

PIGA S[1], SCAGLIONE FE[2], MEDA S[1], SERENO A[2], CHIAPPINO L[2], BOLLO E[2]

[1]Zoom Torino, Strada Piscina 36, 10040 Cumiana, ITALIA; info@zoomtorino.it
[2]Universita' Degli Studi Di Torino, Dipartimento Di Scienze Veterinarie, 10095 Grugliasco (TO), ITALIA

A 7-years-old neutered male Dromedary Camel (Camelus dromedarius) living in a zoological garden in northern Italy (Zoom, Torino) and sharing the habitat with two conspecifics (a male and a female), showed a subcutaneous nodular mass in the right scrotum since September 2011 and was examined in February 2012. The rounded hard mass measured 4 cm in diameter and was firmly adherent to the inner surface of the scrotum and painful at palpation. The animal was castrated two years before. A blood sample was taken from the left jugular vein and a full blood screening was performed. Haematology indicated leukocytosis suggestive of a chronic process, and no biochemistry abnormality was detected. A histological investigation of the mass was not performed because of the difficult behaviour of the animal, not allowing a biopsy without sedation. Differential diagnosis included an abscess and a neoplastic process. The animal was treated with antibiotics and anti-inflammatory drugs for seven days. After two months the mass started increasing in volume and measured 10 cm in diameter. The animal was prepared for surgery and anaesthetised with a xylazine-ketamine combination for surgical removal of the mass. The surgical area was prepared and scrubbed with chlorhexidine. A vertical incision of the scrotum was performed and the mass appeared to be encapsulated. A full resection was performed of both the mass and capsule. As the mass was removed, a flushing of the scrotum with saline solution was performed and a drainage was placed to prevent a fluid accumulation. The drainage was removed after four days, and after seven days the antibiotic therapy was suspended. The mass, showing a solid appearance at the cut surface, was fixed in 10 % neutral buffered formalin and referred to the Department of Veterinary Sciences of the University of Turin (Italy) for histological and histochemical examinations. The mass was paraffine-embedded, sectioned at 4 µm using a microtome (Leica Microsystems, Wetzlar, Germany), and stained with Haematoxylin and Eosin (HE), periodic acid-Schiff (PAS) and Grocott stainings (GMS). Microscopic evaluation of the mass revealed a granuloma with a necrotic centre, surrounded by plasma cells, macrophages, neutrophils, and diffused fungal hyphae characterised by parallel cell walls, distinct septa, and branching in the outermost layer, surrounded by a thick fibrous layer with multifocal lymphocytic infiltrate and haemorrhages. Fungal hyphae stained PAS positive and black with GMS.
Histological and histochemical findings were consistent with the diagnosis of a fungal granuloma.

# RENAL HYPOPLASIA AND RENAL DYSPLASIA AS INCIDENTAL FINDINGS IN PARMA WALLABIES (*MACROPUS PARMA*)

POSAUTZ A[1], BALFANZ F[2], KÜBBER-HEISS A[1]

[1]University of Veterinary Medicine Vienna, Research Institute of Wildlife Ecology, Savoyenstr.1, 1160 Vienna, AUSTRIA; Annika.Posautz@fiwi.at
[2]Tierärztliche Ordination Tiergarten Schönbrunn, Seckendorff–Gudent Weg 6, 1130 Vienna, AUSTRIA

Renal hypoplasia is the result of an incomplete development of the kidney, mostly leading to fewer normal nephrons, in an otherwise well-formed kidney. It has been reported in several domestic species, and is congenital in Large-White-Pigs. In comparison, the renal dysplasia is a result of an abnormal structural development and usually embryonic features, as well as an overall disorganised structure of the kidney can be seen in pathohistology. Like the hypoplasia this can be congenital (e.g. sheep, certain dog-breeds). As long as it is unilateral these diseases usually do not cause clinical signs. Both these entities have to be differentiated from each other, as well as from fibrosis occurring early in life. As this is rather hard, five primary features of dysplasia should be kept in mind, when evaluating the kidneys: primitive mesenchyme giving a myxomatous appearance to the interstitium; metanephric ducts; adenomatoid tubular epithelium; presence of cartilage/bone; asynchronous differentiation of nephrons. In marsupials renal malformation (i.e. hypoplasia/dysplasia) is seldom reported. Six (four female adults, one female subadult and one male subadult) Parma wallabies (*Macropus parma*) were submitted for necropsy after a predation incident. All animals were clinically normal prior to their death. All six animals were in close familial relation to each other. Besides severe haemorrhages in the tissue and musculature in the neck area, in two of the animals (two female adults) a severe hypoplasia of the right kidney (organ weight: 1 g), and in two others (two females; one adult and one subadult) a severe dysplasia of one kidney each was noted at necropsy. Macroscopically the kidneys of the first two females, apart from their size, were normal. The kidneys of the adult and subadult female macroscopically had a scarred and shrunken appearance. In histology the first two ones showed a highly sclerotic medulla, with only few tubular structures and these containing hyaline casts. The tubular epithelium was eosinophilic and vacuolated. Multifocally the tubules in the renal cortex were degenerated (hypereosinophilic, loss of nuclear detail), and surrounded by a mild lympho-plasmacytic infiltrate and multifocally sclerotic glomeruli. These macro- and microscopical changes were interpreted as hypoplasia. Histology of the kidneys of the adult and subadult females showed markedly dilated and elongated tubules in the medulla, with pigment-laden tubular epithelium. The renal parenchyma was multifocally distorted by severely sclerotic areas with loss of renal structures, and the massively dilated tubules and sclerotic glomeruli, as well as areas with myxomatous appearance. Multifocally there was a mild chronic interstitial nephritis. Summarizing the changes of the latter described kidneys (macroscopical shrunken and scarred look and the myxomatous and somewhat asynchronous differentiation visible in histology) led to the diagnosis of dysplasia, although not all of the five primary changes were seen. As there is no history of renal disease in any of the animals, and all animals were in close familial relation to each other, an underlying congenital component is highly suggestive in these cases.

# TWO GROUPED CASES OF ALVEOLAR ECHINOCOCCOSIS IN PRIMATES IN EASTERN FRANCE

QUINTARD B[1], LAHOREAU J[2], GRENOUILLET F[3], UMHANG G[4], NICOLIER A[5], LEFAUX B[1]

[1]Parc zoologique et botanique de Mulhouse, 51 rue du jardin zoologique, 68100 Mulhouse, FRANCE; benoit.quintard@mulhouse-alsace.fr
[2]Parc animalier de Sainte-Croix, route de Sainte-Croix, 57810 Rhodes, FRANCE
[3]CNR Echinococcose alvéolaire, CHU Jean Minjoz, 25030 Besançon, FRANCE
[4]NRL *Echinococcus* sp., Anses Nancy Laboratory for Rabies and Wildlife, 54220 Malzéville, FRANCE
[5]Vet Diagnostics, 14 avenue Rockefeller, 69008 Lyon, FRANCE

Alveolar echinococcosis (AE) is a parasitic disease of various mammalian species caused by the development of the larval stage of *Echinococcus multilocularis* within the liver and other organs, such as lymph nodes, lung or brain. Small mammals, mainly rodents, are the natural intermediate host, but primates, including humans, can accidentally be aberrant hosts. Cases have already been described in macaques orang-utans, gorillas and lemurs from western Europe and Japan, all leading to death without treatment.

In 2012, two primate groups from two different zoos in Eastern France were diagnosed with AE. One group from the Sainte-Croix animal park in Rhodes was composed of 12 ring-tailed lemurs (*Lemur catta*). The first case was discovered at necropsy on a drowned animal that had previously shown slight apathy, ALT increase and neutrophilia for three weeks. Necropsy revealed typical multivesicular hepatic lesions, confirmed on PCR and histology. An ultrasound survey on the 11 remaining animals showed severe hepatic lesions in four animals without disturbed general condition.

The second group was composed of five Tonkean macaques (*Macaca tonkeana*) in the Mulhouse zoo. The first two cases involved the breeding male and an old female that both showed apathy. A complete check-up was performed under anaesthesia and revealed extended hepatic masses ranging from 1 cm to 5 cm in diameter in both animals. Upon laparoscopic exploration, the severity of the lesions led to euthanasia of both animals. One of the three remaining group members had peritonitis, diagnosed by coelioscopy and had positive AE serology.

The diagnostic techniques involved serology (haemagglutination, ELISA, confirmed by Western Blot), PCR on lesions, histology, ultrasounds and/or coelioscopies. The combination of all these techniques had led to the final diagnosis and a general follow-up protocol including regular testing and treatment for zoo primates. In both primate groups, a daily life-long oral treatment regime was set up for the infected animals with albendazole (10 mg/kg, Valbazen [ND)] as recommended for humans. Surgical resection was not possible due to the extension of the lesions.

In regions with high AE prevalence, this disease is not only a major public health concern but also significantly impacts the safety and health of zoos staff. In our cases, animal keepers and veterinarians, who might have been in contact with the potential source of infection (most probably environmental contamination by fox faeces) were tested for echinococcosis with serology and ultrasound and new work procedures were set up for the staff.

Our cases illustrate a possible approach on how to deal with outbreaks of AE in zoos. Considering the potential spread of AE across Europe, the prevention and clinical management of AE will play an increasing role in zoo collections in the future.

# EXPERIMENTAL MATING PREFERENCES ENHANCE OFFSPRING DISEASE RESISTANCE

RAVEH S[1,2], SUTALO S[1], THONHAUSER KE[1], THOß M[1], HETTYEY A[1,3], PENN DJ[1]

[1]University of Veterinary Medicine Vienna, Konrad Lorenz Institute of Ethology, Dept. of Integrative Biology and Evolution, Savoyenstraße 1a, 1160 Vienna, AUSTRIA; Dustin.Penn@vetmeduni.ac.at

[2]University of Basel, Dept. of Environmental Sciences Zoology and Evolution, Vesalgasse 1, 4051 Basel, SWITZERLAND

[3]MTA Centre for Agricultural Research, Plant Protection Institute, “Lendület" Evolutionary Ecology Group, Herman Ottó út 15, 1022 Budapest, HUNGARY

Mate choice may allow females to obtain genetic benefits that enhance offspring fitness, including resistance to infectious diseases. We tested this hypothesis experimentally using F1 from wild-caught house mice (*Mus musculus musculus*) in the following assays: First, we tested females’ attraction towards two males simultaneously presented in a partner preference assay (n = 30), and we then experimentally mated each female with either their preferred (P) or non-preferred (NP) male. Second, offspring from experimental matings were weaned at 21 days, and at 15 weeks, 72 mice were experimentally infected with *Salmonella enterica (serovar* Typhimurium, LT2). Third, we monitored infection dynamics (bacterial clearance) over three weeks, and we analysed individual heterozygosity at the major histocompatibility complex (MHC class II Eb, Aβ, and class I K loci) with microsatellite markers to determine whether these immune loci affected females’ preferences or offspring disease resistance. We found no overall differences in pathogen clearance, though offspring from P males tended to show better pathogen clearance compared to those from NP males among the MHC homozygotes. Three weeks after infection, offspring from P sires were significantly more likely to survive than those from NP males. Our results provide the first direct experimental evidence that female mating preferences can enhance the resistance of offspring to infectious diseases.

# SET-UP AND RESULTS OF THE EPIDEMOLOGICAL SURVEILLANCE PROGRAMME FOR WILD RABBIT IN ANDALUSIA (SPAIN)

REDONDO I[1], RODRIGUEZ E[3], ZORRILLA I[3], RAYAS E[3], CAMACHO LN[3], SAN JOSÉ C[3], TALAVERA V[3], FERNÁNDEZ ML[3], MOLINA I[3], GÓMEZ-GUILLAMÓN F[2]

[1]Instituto Andaluz de Caza y Pesca Continental. Consejería de Agricultura, Pesca y Medio Ambiente (Junta de Andalucía), Av. Manuel Siurot, 50 CP, 41071 Sevilla, SPAIN

[2]DP Consejería de Agricultura, Pesca y Medio Ambiente en Málaga (Junta de Andalucía), C/ Mauricio Moro nº2 planta 3 CP, 29018 Málaga, SPAIN; felixj.gomezguillamon@juntadeandalucia.es

[3]Agencia de Medio Ambiente y Agua de Andalucía (Consejería de Medio Ambiente-Junta de Andalucía), C/Johan G. Gutenberg nº1, Isla de la Cartuja, CP, 41092 Sevilla, SPAIN

Based on what was established in the Regulation for Hunting Organization, the Regional Environmental Ministry of the Regional Andalusian Government set up in 2009 the Epidemiological Surveillance Programme for the Wildlife in Andalusia (PVE), whose objective is to carry out the monitoring of the health status of wild animal species, to detect the occurrence of diseases, determine disease prevalence, and establish together with the Regional Ministries of Agriculture, Fishing and Health, the pertinent intervention measures, either for disease prevention, fighting or control.

The programme has 15 specific protocols for animal species or groups of species, including the following game species: red deer, fallow deer, roe deer, wild boar, wild rabbit, red-legged partridge, Spanish ibex, mouflon and Barbary sheep. The official laboratories for the analysis and diagnosis of the diseases which are the objective of the study are: the Cordoba Laboratory for Animal Production and Health (Regional Agricultural and Fishing Ministry), the Campanillas, Malaga Laboratory for Animal Production and Health (Regional Agricultural and Fishing Ministry), the Central Laboratory for Animal Health of the Environmental, Rural Life and Marine Ministry in Algete (Madrid), and the Analysis and Diagnostic Center of Andalucía (CAD, Andalusian Regional Government – AMA, Agencia de Medio Ambiente y Agua). Since it was set up in September 2009, samples of blood, serum, lungs, liver and faeces have been taken from 719 dead wild rabbits (more than 59 animals sampled from 12 different areas of Andalusia). These samples were analysed for myxomatosis, viral haemorrhagic disease (VHD), *Salmonella enteritidis/typhimurium*, *Mycobacterium* spp. and *Taenia pisiformis*.

According to our results, myxomatosis virus has a high circulation (60.8 % positives out of all sampled animals) and is distributed throughout Andalusia. Risk factors related with this virus are the area tested, age and lesions of sampled animals, term of sampling (from May to May) or if there has been an outbreak the year before.

VHD has also a high circulation (36.4 % positives out of all sampled animals) and is distributed throughout Andalusia. Risk factors related with this virus are the area tested, term of hunting (from May to May), density of animals and if there has been positivity also with myxomatosis virus.

High seropositive prevalence for both viruses in sampled animals shows the high contact rate of the wild rabbit population of Andalusia with these viruses.

# SEQUENCING RESULTS INDICATE DIVERSE POPULATION OF FLAGELLATES IN FAECAL SAMPLES OF CAPTIVE REPTILES

RICHTER B[1], PANTCHEV N[2], GLOBOKAR VRHOVEC M[2],
ALTHERR B[2], ALEXANDROW N[1], NEDOROST N[1]

[1]University of Veterinary Medicine, Institute of Pathology and Forensic Veterinary Medicine, Veterinärplatz 1, 1210 Vienna, AUSTRIA; Barbara.Richter@vetmeduni.ac.at
[2]IDEXX Vet Med Lab, Mörikestr. 28/3, 71636 Ludwigsburg, GERMANY

Flagellated protozoa are commonly found in routine coproscopical examination of reptilian faecal samples. Often, these are broadly grouped as “trichomonads”, “proteromonads” or “diplomonads” based on their morphology and pattern of movement. However, a detailed assessment of flagellates and other organelles is not possible without cultivation of the organisms and/or special staining techniques. Molecular data on parasitic and commensal organisms in captive reptiles is still scarce.
In an ongoing project 76 faecal samples from tortoise species and bearded dragons were examined microscopically by means of a direct saline faecal smear and molecularly with polymerase chain reaction (PCR) and genomic sequencing. The samples were submitted to the laboratory for routine diagnostics and were chosen for the project if there was a commonly encountered and apparently monomorphous population of flagellated protozoa visible coproscopically.
Forty-six of 54 examined tortoise samples were microscopically positive for “trichomonads”. In 42 of these a definite genomic sequence could be achieved from the organisms. These revealed the presence of at least six different species from three different classes of Parabasalia (Trichomonadea, Tritrichomonadea and Hypotrichomonadea). Fifteen tortoise samples contained flagellates with diplomonad morphology, of which 12 samples yielded sequences of flagellated organisms with a large phylogenetic diversity. Only one sample revealed a genomic similarity with an uncultured *Hexamita*-like organism and five samples had some similarity with Enteromonadidae. Other sequences showed a relationship with flagellates from insects as well as with free-living flagellates from water samples and uncultured eukaryotes.
Nineteen of 22 samples from bearded dragons showed a trichomonad population microscopically. Of these, 11 were identified as hypotrichomonad (*Hypotrichomonas* spp. and *Trichomitus* spp.) and one as tritrichomonad species. Nine animals had “proteromonads” in the faeces, of which eight yielded a 93 to 100 % similarity with *Proteromonas lacertae*.
The intestinal flagellated population in faecal samples seems to be quite diverse, especially in tortoise species. Interestingly, many of the yielded sequences show up to 12 % nucleotide dissimilarities to published GenBank sequences from properly described eukaryote species. Possibly many cryptic and so far undescribed species or subspecies of flagellated organisms exist in the captive reptilian population. The relationship between flagellate and reptile (commensal vs. parasite) is still unknown in most cases. As most of the samples, especially from tortoises are collected from the ground, a secondary contamination with free-living flagellates from the environment should be taken into consideration.

## Acknowledgements

This project is being supported by the Ingo-und-Waltraud-Pauler-Fonds, granted by the veterinary working group of the German Society for Herpetology and Herpetoculture (AG ARK-DGHT).

# OVERVIEW OF THE RISK ANALYSIS OF THE NORTHERN BALD IBIS (*GERONTICUS EREMITA*) RELEASE PROJECT IN SOUTHERN SPAIN

RODRÍGUEZ P[1], BAKKER J[2], MUÑOZ MA[3]

[1]Wildvets SLP, C/Abades 18 2ºb, 41004, Seville, SPAIN; pablowildvets@gmail.com
[2]Animal Science Dept., BRPC, Lange Kleiweg 161, 2288GJ, Rijswijk, THE NETHERLANDS
[3]Zoobotánico, C/ Madreselva s/n 11.408, Jerez de la Frontera (Cádiz), SPAIN

The Northern Bald Ibis (NBI, *Geronticus eremita*) is considered critically endangered by the IUCN Red List. The Zoobotánico of Jerez and the Environmental Andalusian Agency designed in 2004 an initiative called "Proyecto Eremita" to investigate different methodologies to establish a colony in La Janda area, Cádiz according to the priorities of the International Advisory Group for the Northern Bald Ibis (I.A.G.N.B.I.). Here we present the risk analysis conducted for the project.
The assumptions we worked with were that the source of the birds was the European Endangered species Programme (EEP) breeding colony of Zoobotánico of Jerez. No relevant infectious diseases were identified in this colony during the previous twenty years. Moreover, we accepted with the hypothesis that after 20 generations in captivity there would be a loss of important natural behaviour such as predator avoidance, migration and foraging skills.
Threat identification was performed: The mean threats were considered to be electrocution and trauma; caused by wind turbines and car accidents. Another problem of lesser importance would be foreign body ingestion, such as metal wire, causing gastric perforation. In addition, predation by owls (*Bubo bubo*), eagles (*Hieraetus fasciatus*) as well as foxes (*Vulpes vulpes*) would represent a threat. Feather picking and self-mutilation has been observed in captive birds. Disorientation and starvation were also identified as threats. The exposure of released ibis to new pathogens, endemics in the area, were also included. Spontaneous migration and return to the colony in northern Morocco is doubtful would be less likely.
The risk of introducing new pathogens into the region with the released birds was considered to be low. The risks associated with the release of the birds into the La Jarda area were considered to be moderate but acceptable. The recommendation was to proceed with the release.
Post-released health monitoring was aided by screening of all the birds prior to release, based on the protocol produced by the I.A.G.N.B.I., where necessary veterinary care for sick or injured birds was provided. Post –mortem analyses of deceased birds were conducted in the veterinary clinic of the zoo.
The risks associated with the NBI release project were mitigated by a Foster Parents Project: surveillance of the birds was maintained for 24 hours a day from hatching until the end of the release season. All the birds were kept in large aviaries located on the release area. Food and water supplementation were provided where necessary. Terrestrial radio-transmitters were attached to every bird. Juvenile birds were locked in the aviary during the juvenile dispersion period (August to November).

We consider the first four years of the project a moderate success as we have managed to maintain a stable number of animals at the release site. The risk analysis effectively helped both identifying the threats and minimising them, and closely monitoring the introduction and adaptation of the birds into the wild.

# ASSESSMENT OF DNA FRAGMENTATION AFTER FLAME-DRYING OF BOAR SPERMATOZOA

RUNGROEKRIT U, PODHAJSKY E, MEINECKE-TILLMANN S

University of Veterinary Medicine Hannover, Dept. of Reproductive Biology, Bünteweg 2, 30559 Hannover, GERMANY; sabine.meinecke-tillmann@tiho-hannover.de

Semen preservation is now one of the notable features of zoo, wildlife and particularly endangered species conservation. It is done not only to maintain those animals but also to guarantee genetic diversity within a species. However, the sophisticated process of conventional semen preservation is dependent on a well-equipped laboratory, frequently out of range under extreme conditions. This complicates the rescue of fertile spermatozoa of e.g. valuable animals found dead in the wilderness or killed during car accidents far from any habitation. A simple sperm conservation method, independent of major technical aids, might be useful in this situation. Using the pig as a model, it has been shown that flame-dried boar spermatozoa are capable to fertilise pig oocytes via ICSI (intracytoplasmic sperm injection: RUNGROEKRIT et al., 2012). Fertilisation was diagnosed on the basis of the following parameters: extrusion of the second polar body, formation of two pronuclei, presence of an isolated y-shaped sperm tail close to the male pronucleus, and absence of a condensed or only partially decondensed sperm head. In the present study porcine sperm were used in order to investigate the sperm DNA fragmentation index (DFI) after flame-drying, using the commercial diagnostic kit Halomax Sui® (Halotech DNA SL, Madrid, Spain). Following semen collection (sperm rich fraction of the ejaculate), sperm were divided into two groups. In Group 1 spermatozoa were selected by a swim-up procedure (Androhep®+ 25 µg/mL PVA for 1 h) and adjusted to a concentration of $0.5 – 1 \times 10^5$ cells/mL, whereas Group 2 spermatozoa remained untreated before flame-drying. For the flame-drying procedure 5 µL of semen suspension at a time were spread on glass slides. Flaming occurred with a campingaz® Bunsen burner with butane/propane cartridge for up to two seconds. Dried semen samples were vacuum sealed in ESCAL film and aluminium film bags to protect samples from air and moisture, and stored for 1 to 5 days (short-term storage) or 90 to 100 days (long-term storage) at 4°C in a refrigerator. After storage, spermatozoa were rehydrated with 10 µL ultrapure water for analysing the DFI with Halomax Sui®, and were stained with a combination of propidium iodide and anti-fading agent (≥ 300 cells/well; 80x magnification, fluorescence microscope). Best results after flame-drying were obtained after a short-term storage of the flame-dried swim-up sperm suspension, since the percentage of spermatozoa with fragmented DNA was significantly lower than in the other treatment groups ($P < 0.05$). In Group 1 (swim-up sperm suspension) a DFI of 30.3 % vs. 34.2 % (short-term storage vs. long-term storage) was observed. The DFI of the flame-dried sperm rich fraction samples (Group 2) reached 38.9 % and 50.6 % after short-term and long-term storage, respectively. In contrast, fresh control spermatozoa showed a DFI of 1.5 %. In conclusion, the present study suggests that porcine sperm DNA of at least 50 % of the treated spermatozoa can persist after flame-drying and storage for up to 90 to 100 days. Therefore, combined with assisted reproductive technologies as ICSI, flame-drying of spermatozoa might become a practical alternative method for sperm conservation purposes.

# COMPARISON OF THREE DIFFERENT EXTENDERS FOR CRYOPRESERVATION OF EPIDIDYMAL SPERM CELLS FROM EUROPEAN BISON (*BISON BONASUS*)

SABÉS-ALSINA M[1], TABERNER E[1], TALLÓ-PARRA O[1], ALMAGRO V[2], FERNÁNDEZ-BELLON H[2], LÓPEZ-BÉJAR M[1]

[1]Universitat Autònoma de Barcelona, Dept. Animal Health and Anatomy, 08193 Bellaterra, Barcelona, SPAIN; manel.lopez.bejar@uab.cat
[2]Parc Zoològic de Barcelona, Parc de la Ciutadella s/n., 08003 Barcelona, SPAIN

This study aimed to evaluate the sensitivity of bison (*Bison bonasus*) epididymal sperm cells to cryopreservation using three different commercial extenders (Minitub Ibérica, Tarragona, Spain): Gent B, Triladyl, and Andromed. Gent B and Triladyl are egg yolk-based extenders whereas Andromed is an egg yolk-free extender.

Testes from a 10-years-old European bison housed at Barcelona Zoo were collected and transported under refrigeration to the laboratory within two hours *post mortem* after euthanasia in autumn 2012. Sperm cells were obtained by retrograde flushing of the caudae epididymes and deferent ducts with a skimmed milk-based medium.

After an initial evaluation of the sperm cells, the sample was split into three parts and diluted using one of the three evaluated extenders to reach a final concentration of 200 x $10^6$ spermatozoa/ml. Samples were packed into 0.5 ml straws (Minitub Ibérica) and kept at 5ºC for 2 h. The straws were then placed horizontally 5 cm above the surface of liquid nitrogen for 15 min, and then plunged into liquid nitrogen. After two weeks of storage, two straws from each extender were thawed in a water bath at 37ºC for 30 seconds. Eosin-nigrosin staining was used to evaluate viability and morphological parameters. To assess the sperm motility features, a computer-assisted sperm analysis system (CASA; Proiser, Valencia, Spain) was used. In addition, functional integrity of the sperm acrosome membrane was estimated by fluorescence PSA-lectin staining and metabolic sperm activity by the resazurin reduction test. Data were analysed by ANOVA and Chi square test. Differences among groups with P values < 0.05 were considered statistically significant.

At recovery, the percentages of viability, progressive and total motility, and sperm acrosome integrity were: 91.5 %, 66.7 %, 89.8 % and 80.8 %, respectively. No significant differences were detected among extenders in viability after cryopreservation (60.5 – 68.0 %). A significant reduction in total and progressive motility was observed after cryopreservation, but no differences were detected among the three extenders (total motility: 25.3 – 35.1 %; progressive motility: 15.9 – 19.8 %). However, specific motility parameters, such as VCL (curvilinear velocity), VSL (linear velocity), VAP (mean velocity), LIN (linearity coefficient), WOB (wobble coefficient) and ALH (mean amplitude of lateral head displacement) showed better values for the samples cryopreserved with the Gent B extender. Cryopreservation in Gent B extender allowed better percentages of acrosome integrity and metabolic rate when compared to Andromed (acrosome integrity: 68.9 % vs. 48.7 %, respectively; metabolic rate: 452639 vs. 178310, respectively).

In conclusion, this study demonstrates that epididymal sperm cells from European bison can be cryopreserved by conventional procedures using various semen extenders. It also suggests that Gent B extender appears to be the most appropriate one when compared to Triladyl and Andromed.

# DOES SOCIAL HOUSING OF CAPTIVE FLAMINGOS AFFECT BREEDING SUCCESS?

SANDRI C[1], SPIEZIO C[1], MAGNONE W[1], PICCIRILLO A[2], SALVELLI A[3]

[1]Parco Natura Viva – Garda Zoological Park, Loc. Figara, 40, 37012 Bussolengo (VR), ITALY; camillo.sandri@parconaturaviva.it

[2]Università di Padova, Dipartimento di Biomedicina Comparata e Alimentazione, Agripolis, Viale dell'Università 16, 35020 Legnaro (PD), ITALY

[3]Azienda Sanitaria Locale 22, Via C.A. Dalla Chiesa, 37012 Bussolengo (VR), ITALY

The flamingo breeding cycle is well known. The typical breeding cycle consists of group display, nest building, egg laying, and hatching. Flamingos are colonial and are best kept in large flocks of at least 20 birds in zoos. Reliable breeding occurs with flocks of more than 40 birds. Two different species of flamingos, the Greater flamingo (*Phoenicopterus roseus*) and Chilean flamingo (*Phoenicopterus chilensis*) were kept in one mixed colony from 2005 to 2011 at Parco Natura Viva, Italy; whereas in 2012 the two species were split into two different flocks: 93 Greater Flamingos in one and 39 Chilean flamingos in the other. At the start of the mixed colony in 2005, 39 Greater Flamingos and 28 Chilean flamingos lived together. This study investigated whether and how the reproductive success of flamingos was influenced by the management applied at Parco Natura Viva. Over a period of four years (2007 – 2010) reproductive success and parental care behaviour were analysed. Moreover, the same data were collected in 2012. Results show that the reproductive success of the Greater flamingos increased over the years. On the contrary the reproductive success of the Chilean flamingos decreased over time and in 2012 breeding did not occur. Findings from behavioural data show that both species of flamingos seem to be monogamous and parental care occurs in both males and females as in the wild. In conclusion, our study provides evidence suggesting that social housing may be an important factor affecting breeding success of captive flamingos.

# EPIDEMIOLOGICAL FEATURES OF PARASITE POPULATIONS IN WILD UNGULATES FROM TAPADA NACIONAL OF MAFRA, A WILDLIFE RESERVE IN PORTUGAL

SANTOS DJ[1], GOMES LM[1], SOARES JF[2], MADEIRA DE, CARVALHO LM[1]

[1]CIISA, Fac. Med. Vet., Univ Tecn Lisboa, Av. da Universidade Técnica de Lisboa, 1300 - 477 Lisboa, PORTUGAL; madeiradecarvalho@fmv.utl.pt

[2]Universidade de Évora, Departamento de Medicina Veterinária, Pólo da Mitra, 7002 - 554 Évora, PORTUGAL

## Summary

Three wild ungulates species were studied between October 2011 and October 2012 to assess gastrointestinal, liver and lung parasites and understand its dynamics during the different seasons. Faeces were processed according to the following techniques: Willis flotation, natural Sedimentation, McMaster method for eggs per gram (EPG) counting and faecal cultures. In the cervids populations, the level of EPG was almost constant without apparent peaks. The three populations of wild boar showed very fluctuating levels of EPG. Sedimentation was positive in 100 % of the population. For *Cryptosporidium* spp. V1 (red deer) and G3 (fallow deer) populations had a prevalence of 10 %, but the total analysis in all populations corresponds to only 2.74 % positives. At the level of L3 from faecal cultures, were observed mainly the genera *Ostertagia* and *Oesophagotomum* for fallow deer and L3 of *Hyostrongylus* spp. and *Oesophagostomum* spp. for wild boars. In cervids genus *Ostertagia* was predominant, while in the wild boar the predominant one was genus *Oesophagostomum*. In terms of Baermann technique, L1 of *Dictyocaulus viviparus, Muellerius* and *Protostongylus* in cervids and *Metastrongylus* in wild boars, were identified. A modified McMaster technique adapted to *Fasciola hepatica* egg count, allowing a perspective of the egg output seasonal dynamics in these ungulates. The dynamics of L3 and strongyle EPG does not correspond to a normal annual cycle, since there are no marked peaks in spring and autumn like for domestic ungulates.

## Introduction and objectives

The Tapada Nacional of Mafra is a wildlife reserve located in the Municipality of Mafra with 827 ha. This reserve is home for three wild ungulates: red deer (*Cervus elaphus hispanus*), the fallow deer (*Cervus dama*) and wild boar (*Sus scrofa*). The aim of this study was to assess the gastrointestinal, liver and lung parasites in these three ungulates, as well as understand its dynamics within one year. Furthermore, we identified the existing parasites by collecting helminths after necropsy of hunted animals in the hunting season of 2011/2012.

## Material and methods

The study was divided, being one part the monthly collection of faeces in all the populations throughout Tapada Nacional of Mafra (one of red deer, seven of fallow deer and three of wild boar) and the other involved the necropsy of hunted animals. Within populations, the study was conducted between October 2011 and October 2012 for cervids and between December 2011 and June 2012 for the wild boars. Faeces were processed according to the following techniques: Willis flotation, natural

Sedimentation, EPG counting by McMaster method and faecal cultures (MADEIRA DE CARVALHO, 2001), Faecal smear for *Cryptosporidium* spp., Baermann +for L1 larval stages (SOUSA, 2000). Further we used a modified McMaster for *Fasciola hepatica* (CONCEIÇÃO et al., 2002) using the following formula: EPG = (total number of observed eggs/number of chambers) x ((50 ml/10 g) / 0.15 ml). The evaluation of this modified method was made not only for faecal samples from one month but for a different number of months (depending on the availability of faeces from the population) resulting in an average of all EPG of all months for the population. Therefore, in contrast to the usual McMaster method with a detection limit of 50 EPG, the modified McMaster method results in EPG number below 50. Necropsy was performed for searching *F. hepatica*, lung nematodes and gastrointestinal helminthes, opening and decanting the gastrointestinal contents for collecting parasites and collecting faeces from large intestine for coprology.

## Results

In the cervids populations, the level of egg per gram (EPG) was almost constant (0 - 50 EPG) without apparent peaks (some shifted to 100 EPG), except G8 (fallow deer) in October 2011, where 900 EPG was registered. The three populations of wild boar showed very fluctuating levels of EPG (min. 100 - max. 20200 EPG). Sedimentation was positive for *Fasciola hepatica* eggs in 100 % of the population, with a few months that were negative in all the populations, except J3. In terms of the modified McMaster, the average red deer population was 2,125 EPG (min. 0 - max. 17). In populations of fallow deer EPG means were: G2 - 7.3 (min. 0 - max. 42), G3 - 23.4 (min. 0 - max. 75); G4 - 16.6 (min. 0 - max. 58); G5 - 7.3 (min. 0 - max. 42); G6 - 2.7 (min. 0 - max. 8); G8 - 1.1 (min. 0 - max. 8) ; G9 - 8.3 (min. 0 - max. 17). In wild boar populations, EPG means were: J1 - 98 (min. 8 - max. 158); J2 - 4 (min. 0 - max. 8); J3 - 65 (min. 33 - max. 100). For *Cryptosporidium* spp. V1 and G3 populations had a prevalence of 10 %, but the total of analysis in all populations corresponds to only 2.74 % positives. At the level of L3 from faecal cultures, were observed mainly genera *Ostertagia* and *Oesophagotomum* for fallow deer and *Hyostrongylus* and *Oesophagostomum* for wild boars. In cervids exists the predominance of the genus *Ostertagia* while in the wild boar the predominance was of genus *Oesophagostomum*. In terms of Baermann were identified L1 of *Dictyocaulus* spp., *Muellerius* and *Protostongylus* in cervids and *Metastrongylus* in wild boars. There were also found *Trichuris* eggs (deer and wild boar), *Capillaria* (red deer) and *Physocephalus* egg type (wild boar). In terms of hunted animals, adult lung nematodes of *Metastrongylus* spp. were found only in wild boars (55.6 % of animals). The average abundance was 44 adults (min. 2 - max. 166). In fallow deer (17 animals) the average *Fasciola hepatica* abundance was 12 (0 min. - max. 37) while for the wild boars (9 animals) it was 1.7 (min. 0 - max. 6). In the abomasum of fallow deer were discovered parasites of the genus *Spiculopteragia* spp. While in the stomach of wild boars were found parasites of the genus *Ascarops* spp. On intestinal level, *Oesophagostomum* spp. was found in the three host species. In red deer was also found two female of *Trichuris* spp.

## Conclusions

The parasites found are in line with the ones described in a previous study (SOUSA, 2001). Only the case of *Cryptosporidium* shows a discrepancy of prevalence (100 % in 2001 and 0 % in slaughtered animals in this study, and 2.74 % of the population). Using the modified McMaster managed to get a perspective of the dynamics of *Fasciola hepatica* in these ungulates. The dynamics of L3 and EPG does not correspond to a normal annual cycle, since there are no marked peaks in spring and autumn like for domestic ungulates.

## References

*CONCEIÇÃO MA, DURÃO RM, COSTA IH, COSTA JM (2002): Evaluation of a simple sedimentation method (modified McMaster) for diagnosis of bovine fascioliosis. Vet. Parasitol.* ***105****, 337 - 343*

*SOUSA CA (2001): Contribuição para o Conhecimento do Risco Parasitário das Populações de Gamo (Dama dama L.) e Javali (Sus scrofa L.) da Tapada Nacional de Mafra, Relatório Curso Engenharia Agronómica, ISA - UTL.*

*MADEIRA DE CARVALHO LM (2001): Epidemiologyand control of strongylidosis in different horse production system in Portugal. (In Portuguese). PhD Thesis, Faculdade de Medicina Veterinária, Universidade Técnica de Lisboa, xxii + 445.*

# ALTERATIONS IN ADRENAL GLANDS OF NON-HUMAN PRIMATES

SCHMITT A, GRUBER-DUJARDIN E, MAETZ-RENSING K, KAUP F-J

German Primate Centre, Pathology Unit, Kellnerweg 4, 37077 Göttingen, GERMANY;
ASchmitt@dpz.eu

Pathological changes of the adrenal glands are rare in non-human primates. We conducted a retrospective survey of post-mortem findings from non-human primates to gain supplementary information about adrenal gland alterations.

On the basis of necropsy reports from 2000 to 2012 tissue material of adrenal glands was investigated using routine histological methods. In total, 2366 animals in total were evaluated: 56 % Old World monkeys, 42 % New World monkeys and 2 % prosimians. Alterations in adrenal glands were found with a low incidence in New (0.3 %) and Old (0.2 %) World monkeys whereas no prosimian species was affected.

New World monkeys, in particular cotton-top tamarins (*Saguinus oedipus*) and marmosets (*Callithrix jacchus*), presented few cases of adrenal myelolipoma (0.1 %) and rarely lipidosis (0.04 %). Myelolipomas are benign extramedullary bone marrow proliferations accompanied by variable proportions of lipocytes, which do not cause any clinical symptoms. Lipidosis can be caused by any disorder of lipid metabolism leading to intracellular lipid accumulation. Multifocal mineralisations were found in Old World monkeys, especially in rhesus macaques (*Macaca mulatta*). Tumors were found in four of all primates investigated. One chimpanzee (*Pan troglotydes*) and one cotton-top tamarin (*Saguinus oedipus*) revealed adenomas of the adrenal cortex. Another cotton-top tamarin showed a pheochromocytoma and a putty-nosed monkey (*Cercopithecus nictitans*) had an oncocytic adrenocortical carcinoma, with both tumors being hormonally active.

In conclusion our survey showed that adrenal glands alterations can be considered as incidental pathological findings which usually do not cause clinical symptoms. Adrenal gland neoplasms are uncommon entities in non-human primates.

# FAECAL SHEDDING OF *TREPONEMA PALLIDUM* IN WILD BABOONS

SCHMITT A[1], SCHWARZ C[2], KAUP FJ[1], MAETZ-RENSING K[1], BATAMUZI EK[3], ROOS C[2], KNAUF S[1]

[1]German Primate Centre, Leibniz Institute for Primate Research, Pathology Unit, Kellnerweg 4, 37077 Göttingen, GERMANY; sknauf@dpz.eu
[2]German Primate Centre, Leibniz Institute for Primate Research, Primate Genetics Laboratory, Kellnerweg 4, 37077 Göttingen, GERMANY
[3]Sokoine University of Agriculture, Dept. of Veterinary Surgery and Theriogenology, Morogoro, TANZANIA

## Summary

*Treponema pallidum,* the bacterium that causes syphilis and yaws in humans, was diagnosed as aetiological agent for genital ulcerations in wild baboons in East Africa. Yet, diagnosis was made by minimal invasive sampling methods. In this study we investigated the usefulness of PFA (Paraformaldehyde) fixed faecal samples as a non-invasive screening method to detect *T. pallidum.* DNA was isolated from PFA fixed faecal samples. PCR results were compared with those obtained from skin biopsies and serology. Although a correlation of *T. pallidum* infection and faecal excretion of the pathogen was not found, it was demonstrated that the bacterium could be found in baboon faeces.

## Introduction

*Treponema pallidum*, the causative agent for human syphilis and yaws, is endemic in wild nonhuman primates (NHPs) of West and East Africa (HARPER et al., 2012). One known hot-spot for the disease is Lake Manyara National Park (LMNP) in Tanzania. Diagnosis was made by minimal invasive sampling of 39 clinically affected and 24 healthy looking baboons (KNAUF et al., 2011). The presence of the spirochetes in animals with and without genital ulcerations was confirmed by immunohistochemistry, serology, and advanced molecular biological tests using skin tissue samples. Although PCR of skin biopsies proved the most sensitive mean of detecting *T. pallidum* infection in baboons, the present study aimed to investigate screening methods that utilise non-invasive sample material.
It is hypothesised that, similar to secondary stage human infection, the bacterium disseminates in the host organism and that the spirochete in baboons may therefore be present in the gastro intestinal system.

## Materials and methods

Faecal samples from 50 olive baboons (*Papio anubis*) at LMNP were collected during a field survey in 2007. Samples were taken from the rectum of anaesthetised baboons and were immediately preserved in 4 % PFA. First-DNA-All-Tissue-Kit (Gen-ial) was used to extract DNA. Basically, extraction followed the manufacturer's protocol with an additional hexane treatment of PFA drained faecal material at the beginning. DNA was eluted in 50 µl HPLC water and frozen at - 80°C until PCR was performed. Extracted DNA was used to run a *T. pallidum* PCR targeting the polA gene as described elsewhere (LIU et al., 2001). Positive and negative controls were included in each assay. Sanger sequencing of amplicons was used to identify PCR results as of *T. pallidum* origin. Results from faecal

DNA were correlated with PCR from skin extracted DNA and serological diagnosis. DNA extraction values were checked for Gaussian distribution.

## Results

As expected, extracted DNA from PFA treated faecal samples was relatively impure (median 260/280 1.35, no Gaussian distribution, n = 50). DNA quantity, however, was satisfying with 14.88 ng DNA/µl (median, 75 % percentile = 42.41, max = 330.60, no Gaussian distribution, n = 50). In 7/50 faecal samples *T. pallidum* was detected by PCR. The generated sequence was identified as part of *T. pallidum* pol A. In detail, three females and four males tested positive via faecal sample analysis. Likewise the comparison of PCR results from corresponding skin material showed that only 3/38 baboons with positive skin PCR were identified as shedding *T. pallidum* via faeces. Furthermore, another 3/19 baboons with negative skin samples in PCR were *T. pallidum* positive in their faecal sample. From one animal corresponding skin material was not available. Compared with our previous results (KNAUF et al., 2011), 6/7 faecal positive individuals had antibodies against *T. pallidum*. One individual had no corresponding serum sample.

## Discussion

As hypothesised *T. pallidum* can be found in faecal samples of *T. pallidum* infected baboons. Detection rates however do not allow the use of faecal samples as a non-invasive screening tool to assess prevalence of wild baboon populations. The study made use of PFA conserved faecal samples that were purposely taken for endoparasite screening. Unfortunately no other faecal material was available. Future studies may therefore increase sensitivity by utilising fresh faecal samples or faeces that are conserved in RNA-Later Solution (Ambion). The presence of anti-*T. pallidum* antibodies in 6/7 faecal positive individuals suggests that *T. pallidum* may invade the gastro intestinal tract systemically. Although not shown here, *T. pallidum* sero-negative animals may become false positive by oral inoculation of contaminated material (e.g. scab, ectoparasites) from self-grooming or social grooming of infected partners. The low detection rate of *T. pallidum* infected baboons may not be useful as a screening tool, but faecal samples from wild baboon populations may be a consideration to get hold of new *T. pallidum* isolates that can potentially be used for strain specification utilising polymorphisms. The advantage of non-invasiveness and amenity in the regulation of biological sample export (faecal samples are not regulated by CITES) might balance the doubtful sensitivity of faecal DNA samples for the detection of *T. pallidum*.

## References

*HARPER KN, FYUMAGWA RD, HOARE R, WAMBURA PN, COPPENHAVER DH, SAPOLSKY RM, ALBERTS SC, TUNG J, ROGERS J, KILEWO M, BATAMUZI E, LEENDERTZ FH, ARMELAGOS GJ, KNAUF S (2012): Treponema pallidum Infection in the Wild Baboons of East Africa: Distribution and Genetic Characterization of the Strains Responsible. PLoS One **7**, e50882.*

*KNAUF S, BATAMUZI EK, MLENGEYA T, KILEWO M, LEJORA IA, NORDHOFF M, EHLERS B, HARPER KN, FYUMAGWA R, HOARE R, FAILING K, WEHREND A, KAUP FJ, LEENDERTZ FH, MATZ-RENSING K (2011): Treponema Infection Associated With Genital Ulceration in Wild Baboons. Vet. Pathol. **49**, 292 - 303.*

*LIU H, RODES B, CHEN CY, STEINER B (2001): New tests for syphilis: rational design of a PCR method for detection of Treponema pallidum in clinical specimens using unique regions of the DNA polymerase I gene. J. Clin. Microbiol.* ***39****, 1941 - 1946.*

# *PHYSOCEPHALUS DROMEDARII* – AN ABOMASAL NEMATODE OF DROMEDARIES

SCHUSTER RK[1], KINNE J[1], WIBBELT G[2]

[1]Central Veterinary Research Institute, P.O. Box 597, Dubai, UNITED ARAB EMIRATES (UAE)
[2]Leibniz Institute for Zoo and Wildlife Research (IZW), Alfred-Kowalke-Str. 17, 10315 Berlin, GERMANY; wibbelt@izw-berlin.de

The Central Veterinary Research Institute in Dubai regularly receives dromedaries for pathological investigations. Recently, two adult female dromedaries originating from a Camel Dairy farm in Dubai were submitted for necropsy. In both animals the abomasums had several areas of reddened mucosa and closer examination revealed an infection with small, reddish coloured nematodes. These nematodes were collected and investigated by light and by scanning electron microscopy. They measured between 14 and 29 mm and had a mouth opening with two trilobed lateral lips followed by a pair of flat papillae on each side. There are three fasciated lateral wings, a broader median wing with fine striation as well as slender dorsal and ventral wings with coarse striation. This nematode has previously been described as a subspecies of *P. sexalatus*, a nematode common in the stomach of pigs and named “thick stomach worm”. But as there are obvious morphological differences between *Physocephalus* sp. in dromadaries and pigs, the nematode found in dromadaries should be upgraded to species level: *P. dromedarii* is larger than *P. sexalatus* and has longer spicules. At the ventral surface the bodies of male *P. dromedarii* are covered with 20 or more distinct oblique crests, while the male *P. sexalatus* has only seven to eight oblique crests. The most significant differences are the presence of two pairs of papillae between the cloacal and postcloacal plate of the male and the existence of a bulging protrusion in the second half of the female body formed by loops of both uterine horns. Unless dromedaries are heavily infected, the parasites are mostly found in lower numbers and do not cause severe clinical disease.

# VITAMIN A CONCENTRATION AND DISTRIBUTION IN THE LIVER OF CAPTIVE LIONS AND EVALUATION OF TRU-CUT NEEDLE BIOPSY FOR MEASUREMENTS OF VITAMIN A IN THE LIVER OF LIVING LIONS

SHAMIR HM[1], BERKOVICH Z[2], HOROWITZ I[3], BDOLAH-ABRAM T[1], GALATEANU G[4], REIFEN R[2]

[1]The Hebrew University of Jerusalem, Koret School of Veterinary Medicine, Faculty of Agriculture, Nutrition and Environmental Studies, P.O. Box 12, Rehovot 76100, ISRAEL; shamir@agri.huji.ac.il

[2]Hebrew University of Jerusalem, School of Nutrition, Faculty of Agriculture, Nutrition and Environmental Studies, P.O. Box 12, Rehovot 76100, ISRAEL

[3]The Safari Zoological Center Ramat-Gan, Ben Tzvi Ave, 1, Ramat Gan, ISRAEL

[4]Leibniz Institute for Zoo and Wildlife Research (IZW), Dept. of Reproduction Management, Alfred - Kowalke-Str. 17, 10315 Berlin, GERMANY

Skull malformations resulting in neurologic abnormalities and death have been, and still are, reported in captive lions (*Panthera leo*) worldwide. The bone abnormality is suspected to be caused by vitamin deficiency in captive lions based on circumstantial evidences in several zoological gardens where high incidences of stillbirth and death of young cubs accompanied by reduction in reproduction of the group, was reduced following excessive vitamin A supplementation. Lions showing mild neurological abnormalities were reported to recover following vitamin supplementation as well. The actual vitamin status in healthy lions in the wild or in captivity is yet to be documented. It is also not known at which stage in the development of the young lion the vitamin is essential for normal skull and cranial cervical vertebral bone formation.

Liver vitamin A concentration is the most reliable indicator of animals' vitamin A status and its assessment is essential in prevention and treatment of vitamin A deficiency in lions. A percutaneous needle liver biopsy with subsequent high-performance liquid chromatography ultraviolet retinoid analysis for vitamin A concentration measurement was validated. It was first assessed in vitro using chicken liver. Later, the safety and feasibility of ultrasound-guided percutaneous needle liver biopsy was assessed in four living lions that were fed red meet only, two of which were neurologically healthy and showed no skull abnormality on CT images, while the other two suffered neurological abnormalities and demonstrated clavarial hyperosteosis on CT. In the third study we looked at the distribution of vitamin A concentration in different liver lobes and compared its content in deep versus superficial parenchyma of each lobe. An overall of 13 lion's livers were used, all of which obtained from lions that died or were euthanised for unrelated reasons. Ten of these lions were fed whole fresh carcass that contained all internal organs, and three were fed frozen red meet only. Four samples were obtained from each liver lobe; two (Tru-Cut needle and wedge biopsy) samples from deep part of the liver lobe and two (Tru-Cut needle and wedge biopsy) from the superficial part of the same lobe. An overall of 20 samples were obtained from each liver.

Our findings confirm the feasibility of needle biopsy technique in evaluating the vitamin A status of living lions. We also concluded that the percutaneous needle liver biopsy technique is a reliable, practical and safe tool for obtaining liver tissue samples for assessment of the vitamin A status in living lions and can be used in future studies. Low levels of vitamin A were measured in all four living lions that were tested although two of them were neurologically normal. Feeding whole carcass resulted in higher vitamin A concentration in the 10 livers examined when compared to the three livers obtained from lions fed frozen red meet only. Vitamin A concentration was found to vary between lions and between different lobes of the same liver, despite being fed similar diet. These differences should be further evaluated to fully understand their clinical significance.

# NON-SUPPURATIVE ENCEPHALITIS IN A POLAR BEAR (*URSUS MARITIMUS*)

SZENTIKS CA[1], TSANGARAS K[1], WOHLSEIN P[2], GROBBEL M[1], GRUBER AD[3], SCHÜLE A[4], AUE A[5], HOFER H[1], OSTERRIEDER N[6], GREENWOOD AD[1]

[1]Leibniz Institute for Zoo and Wildlife Research (IZW), Alfred-Kowalke-Str. 17, 10315 Berlin, GERMANY; szentiks@izw-berlin.de

[2]University of Veterinary Medicine Hannover, Dept. of Pathology, Bünteweg 17, 30559 Hannover, GERMANY

[3]Freie Universität Berlin, Institute of Veterinary Pathology, Robert-von-Ostertag-Str. 15, 14163 Berlin, GERMANY

[4]Berlin Zoological Garden, Hardenbergplatz 8, 10787 Berlin, GERMANY

[5]Berlin-Brandenburg State Laboratory, Invalidenstr. 60, 10557 Berlin, GERMANY

[6]Freie Universität Berlin, Institute for Virology, Philippstr. 13, 10115 Berlin, GERMANY

This case report documents the difficulties detecting the causative agent(s) of fatal non-suppurative encephalitis in polar bears (*Ursus maritimus*) using standard laboratory methods. A 4-year-old hand-raised bear of the Berlin Zoological Garden died in March 2011 after sudden seizures and drowning in the moat of the enclosure. The medical files did not record prior health problems. Necropsy revealed mild asymmetry of the cerebrum near the olfactory bulbs with a small convex prominent area close to the right bulb and congestion of the large meningeal blood vessels. Histological analysis of the central nervous system demonstrated severe multifocal lymphocytic to plasmacytic and eosinophilic panmeningo-encephalomyelitis. The inflammation in the cerebrum was perivascular and perineuronal while cerebellar changes comprised only perivascular inflammation. Nodular microglial proliferations, multifocal cerebral cortical necrosis and central chromatolysis of neurons with partly peripherally orientated nuclei were present. Additionally, in the cerebral cortex lymphocytic to plasmacytic and eosinophilic inflammation of the choroid plexus with focal perivascular haemorrhages were identified. Overall, the inflammation was more severe in the cerebrum and brain stem than in the cerebellum, spinal cord and meninges. However, lesions did not show a predilection for a specific anatomical cerebral region even though the mild asymmetry would have suggested so. Inclusion bodies and parasites were not detected histologically. Bacteriological and mycological investigations failed to identify candidate pathogenic bacteria or fungi. Nucleic acids or antigen of 37 different agents could not be detected by routine and extended investigations using immunohistochemistry and PCR. The lymphocytic to plasmacytic character, however suggested a virus infection, whereas the eosinophilic profile could have been caused by parasites. This report will show a way forward that pairs new methods (e.g., next generation sequencing and high throughput DNA microarrays) when routine diagnostics do not yield a conclusion and have been demonstrably successful in several polar bear encephalitis cases.

# *DELETROCEPHALUS* SPP. INFECTION IN RHEA (*RHEA AMERICANA*) IN A ZOO IN GREECE

TAHAS SA[1,2], DIAKOU A[3], POSANTZIS D[4], NATSIOS P[5]

[1]University of Liverpool, School of Veterinary Science, Leahurst Campus, Neston, Wirral, CH64 2TE, UK; S.A.Tahas@liv.ac.uk
[2]Alexander S. Onassis Public Benefit Foundation, 56 Amalias ave, 10558 Athens, GREECE
[3]Aristotle University of Thessaloniki, Faculty of Veterinary Medicine, Laboratory of Parasitology and Parasitic Diseases, 54124 Thessaloniki, GREECE
[4]Attica Zoological Park, At Yalou, Spata, 19004 Athens, GREECE
[5]Aristotle University of Thessaloniki, Faculty of Veterinary Medicine, Companion Animal Clinic, Dept. of Clinical Sciences, 54124 Thessaloniki, GREECE

Like other ratites, greater rheas (*Rhea americana*) are becoming popular worldwide in agricultural production and zoological gardens, with international bibliography mostly on ratite farms. In the Attica Zoological Park, the largest zoological collection in Greece, greater rheas were shipped from France and Italy in 2003 and 2009, respectively, and hatching of eggs was first noted in 2010. Of the first six rheas hatched at the Attica Zoological Park in 2010, only one of six hatchlings made it to more than three months of life. This unusually high juvenile mortality led to parasitological examination of the rhea population in an attempt to investigate their health status. In April 2010 and July 2011, fresh faecal samples were collected from the ground of the exhibit after observation of defecating patterns of adult and juvenile birds. Samples were refrigerated and sent to the Laboratory of Parasitology and Parasitic Diseases, Faculty of Veterinary Medicine, Aristotle University of Thessaloniki, Greece. Faecal samples were examined by the Teleman sedimentation method and a zinc sulphate flotation method. Based on morphological criteria, *Deletrocephalus* spp*.* unembryonated eggs were identified during both examinations from adult and juvenile birds. This is the first report of *Deletrocephalus* spp. in Greece and the second of the parasite outside America. Unlike mammals in the exhibit, the rheas are not routinely treated with antiparasitics. During samplings all birds were clinically healthy and there was no presence of diarrheic faeces in the exhibit. We are as yet unsure whether the presence of *Deletrocephalus* spp. played a significant role in the high mortality of rhea chicks; however its contribution to the cause of death cannot be excluded. This is supported by the literature where it is reported that high infestations can lead to rhea flocks with diarrheic and cachectic chicks, followed by high mortality rates. The presence of *Deletrocephalus* spp. in rheas in Greece suggests that birds were infected with the parasite upon arrival in Greece and that the parasite must have completed its life cycle under Greek weather conditions. Zoo veterinarians should be aware of this ratite parasite and the possible implications it might have in the survival of chicks in greater rhea zoo populations.

# CONSIDERATIONS FOR MAXIMISING THE EFFICIENCY OF TRAINING TIGERS AND OTHER ZOO ANIMALS

TWITCHETT M

Zoo Health Limited, Isle of Wight Zoo, Sandown, Isle of Wight, PO36 8QB, UK;
zoohealthltd@gmail.com

## Summary

This paper highlights some of the many considerations that should be taken into account by individual trainers and managers in zoos planning to introduce a training programme, and when reviewing the progress of training in order to optimise the efficiency of training. Based mainly on the authors experience training tigers many of the points raised apply equally to other species that are trained in zoos. Training should be carried out as efficiently as possible in order to progress well and prevent trainers, managers and in some cases the animals themselves becoming demotivated to continue further training.

Success will ultimately come from a top down approach with management maximising their support to the staff carrying out the training who in turn through careful observation of their animals and of each other will learn how best to motivate their animals to train. There will always be setbacks and some obstacles are unavoidable. It is important to recognise this and work through the problems that occur as positively as possible seeking help from colleagues and outside sources whenever necessary. Seeking advice from more experienced trainers is essential if an individual fails to respond to training even after all other factors have been considered.

## Introduction

Over the last two decades there has been increasing use positive reinforcement techniques in zoos to facilitate enrichment of the animals and to aid in their husbandry thus increasing their welfare (BLOOMSMITH et al., 1998; DESMOND and LAULE, 1994; KEUHN, 2002). Training has been used for a number of purposes from educational displays of natural behaviour in a Nile monitor *Varanus niloticus* (PROBST et al., 2001) to conscious collection of semen in a cheetah *Acinoynx jubatus* (DURRANT et al., 2001). Training has also been shown to enhance the visitor experience augmenting the role of zoos in education (Anderson et al., 2003). The positive effects on staff job satisfaction and therefore staff retention should also not be overlooked.

BALL and FRAZIER (2002) describe the use of operant conditioning to improve the veterinary care of zoo animals. For example the following of a target could potentially be used to help train the tigers to walk on to scales in order to maintain up to date records of the animals' weights or to encourage crate training from which injections, blood sampling and other procedures could follow (WACK, 2003). BUCHANAN-SMITH (2003) suggests that improved veterinary care, such as reducing the risks associated with general anaesthesia (DART, 1999; BRODBELT et al., 2005) is perhaps the most important use of positive reinforcement techniques which is why we as vets need to take an active role in promoting training in the zoos in which we work.

A high proportion of American Zoo and Aquarium institutions have an official operant conditioning program but many institutions do not employ extra staff or increase the time available for the staff to train (GOOD, 2000). We have a similar situation in Europe where most individual animals in zoos are not trained by a dedicated trainer and so training is often left to the zoo keepers themselves which too

often means training has to be fitted in around their other duties. As time available is often limited each training session needs to be as efficient as possible in order to be successful enough to motivate staff to continue and build on the training.
Successful training will only happen when both the trainer and animal being trained are motivated to participate.

## Factors to consider

What motivates animals and trainers to train and the strength of motivation will vary between individuals, there will also be variation in the degree to which certain factors can lead to demotivation but those factors always need to be taken into account when planning and implementing training.
Factors to be considered when maximising training efficiency can be divided into: trainer, animal, environmental and management.

**Trainer**

- Experience: There is no doubt that the more experience and training a trainer has the better and more efficient they should be as a trainer. This should not stop an inexperienced individual from starting to train animals under their care but the more guidance they can have the less likely they are to find themselves going down the wrong path and either wasting time or becoming totally demotivated. For example although trainers should be careful not to try to achieve too much too soon it is equally possibly to underestimate the animals' ability to learn and actually hold back their progression.

- Training plan: It is essential that the trainer already knows what they are going to train before the session starts and there should also be a plan B and even plan C so that sessions can be changed should circumstances demand it. Otherwise sessions can stall and end in frustration for both animal and trainer. The plan should also dictate who trains what behaviour as it is generally accepted that new behaviour should be taught by a single trainer to avoid confusing the animal, although some animals seem quite capable of learning from more than one individual.

- Focus: During training we are expecting the animal being trained to focus on us so we in turn should focus on them. Being distracted by answering questions of interested zoo visitors or other staff will at least slow down the training and at worst (depending the type of training and the animal being trained) lead to serious injury or death. However it is worth noting that by observing each other train staff can often advise each other on potential improvements they could make as when we are "in the zone" training animals we can become too focused on trying to elicit the desired behaviour to notice the bigger picture. In many situations training can be carried out in view of the public and this can greatly enhance visitor experience but ideally another member of staff is present to engage the public. It is worth noting that sometimes personal issues will impact on our focus. Where there is any risk to the trainer or animal it would be best to postpone any sessions until the trainer is less distracted. However, sometimes spending a few minutes away from the rest of the world focussing your mind on training an animal can be great medicine to someone who's having a bad day.

- Time allocation: Training sessions should be as much a part of the daily schedule as feeding cleaning and enrichment. It is best to be realistic about the amount of time available including planning, preparation of the reward and completing training logs. Trying to do too much in the available time will lead to demotivation. Well planned daily sessions lasting just two or three minutes

are often more rewarding and less frustrating than unfocused occasional ten minute sessions. Sometimes a special case will arise in which more intensive training can be part of the management e.g. a hospitalised animal. This will give the trainer less time to train other animals under their care. Although animals clearly will not progress when they are not being trained they rarely regress over short periods. Therefore the trainer should not feel or be made to feel frustrated that some of their animals are receiving fewer training sessions during these periods.

**Animal**

- The reward: Positive reinforcement training relies on the animal being motivated enough by the potential reward to perform (or try to perform) the desired behaviour. Food is often used as a primary re-enforcer. It might seem obvious but food is more re-enforcing when the animal is hungry and the type of food offered is more highly sought after. Knowing individual preferences is essential, as is coordinating training sessions with other feeding times (often as close to as possible or instead of the next scheduled feed). However, a very hungry animal might be too enthusiastic or even too aggressive to allow calm training and some animals would continue to train and eat until they are physically full. Individual knowledge of the animals allows trainers to vary the rewards according to the animal's behaviour. The food offered should ideally be part of the normal diet, not given in addition to it. Non-core diet rewards can be used with the agreement vets or nutritionists. They should only be used where they offer clear advantage over core diet items including speed of preparation and increased motivation. For example many of our cats enjoy goats milk delivered from a spray bottle. The speed of preparation of the milk compared to meat based rewards saves the staff a significant amount of time each day.

- Cage mates: Trying to train an animal single handed when more dominant cage mates are present will often lead to failure and possibly injury to an animal. Working in teams or training the animals to be separated is an essential first stage.

- Timing: Training should take place at a time that suits the animals as well as their trainers. Again there can be individual variation between animals of the same species and so careful observation and trial and error are required. For example one tiger I trained would not trained for the first hour after being let out of his night room in the morning, during this time he would remain close to his brother who was housed separately. Training later in the day was invariably more successful. This is one of the reasons why a simple training log can be beneficial when reviewing training progress

- Sex: The natural urge to mate is a very strong motivator and often outweighs the desire to train. The effect of oestrus in tigers can vary from them being slightly distracted from training to not participating for 10 days. The effect of females in oestrus on nearby males can also vary and no time should be wasted trying to train any animal that is clearly distracted.

- Ill health: One of the many advantages of training is the early detection of ill health both from the keepers spending more time in close proximity to the animals allowing visualisation of problems and the increased awareness of their normal behaviours. Unwillingness to participate in training in an animal that is usually willing to train could indicate there is a health issue which might need to be resolved before further training can be carried out.

- Individual variation: There are differences between how individual animals respond to different trainers and there are also differences between how different animals respond to the same trainer. GUERRERO (1996) describes that there are differences between species of big cats as well as

individuals of the same group. She also explains that the biggest difference between males and females occurs with lions. In our establishment it certainly seemed that females are generally more eager to train but some males show great enthusiasm too. It is important not to make up excuses for how well or not animals train. Labelling an animal as impossible to train does nothing to improve the chances of that individual being trained. However, depending on the reason for training an individual it might be worth focussing training on the more responsive individuals initially until the trainer builds up confidence and experience that will allow them to try again with the less responsive animals.

- Welfare implications: The Secretary of State's Standards of Modern Zoo Practice guidelines indicate that all training should be of net welfare benefit to the animal (DEFRA, 2004) and ideally improves the welfare of the animals without causing any decrease in welfare. Although it is very difficult to force an animal to participate in positive reinforcement training care needs to be taken that welfare is not being compromised e.g. by using starvation to motivate training or using forced separation of a group to allow training of individuals. In many cases the stress involved would limit the likelihood that an animal would focus on training anyway.

**Environmental**

- Location: Animals in neighbouring enclosures, public and staff can all distract animals from training. Therefore train away from other animals that are perceived to be a threat and train in areas where the animal being trained feels less threatened (often away from their night quarters). One of the many benefits of training is an increase of trust between trainer and animal and often cats that have been very defensive in their night quarters become less so as the relationship with their keeper changes; the reduction in stress associated with the necessary human presence around the animals is just as likely due to the positive association of being hand fed as it is with the actual training process (MCKINGLEY and BUCHANON-SMITH, 2003). One tiger I tried to train was very reluctant to come to the enclosure fence in one enclosure but progressed well in a different enclosure. This observation highlighted the fact that she never normally entered the part of the enclosure she was reluctant to train in and although a reason was not fully established it seemed logical that for some reason she was nervous of entering that area.

- Weather: Extremes of weather can affect both the animals and the trainer's motivation to train and training times and locations might have to be adjusted during certain weather conditions in order to get most out of the sessions. High winds can be distracting for some animals and many animals (and keepers) prefer to seek shelter in very wet, cold or hot weather.

- Building/enclosure design: With the correct facilities in place training certain behaviours becomes much easier (and in some cases possible). Often this means the staff using ingenuity in adapting the areas they have to work in but the potential for training should always be considered in any new build and therefore trainers, keepers and vets should all offer their input at the planning stage. For example building in crush cages or removable crate within tunnel systems facilitates crate training. However, even if these facilities are not available securing pet carriers to shelves or open crates to slides or doors will allow "training" with minimal effort from the staff as initially the animals will desensitise themselves to the new additions to their enclosures and then the keepers can simply put a portion of the diet inside the crates to develop a positive association before there is any need to spend time using operant conditioning (you do not always need a clicker or whistle to achieve your goals).

**Management**

Having support from managers is essential. Although most managers now see the importance of training in modern zoos many do not see it as a priority and staff often end up carrying out training on an *ad hoc* basis which can lead to demotivation and long term failure. As vets we can get involved with presenting the pros and cons of training to upper level managers as well as getting more hands on with guidance on what behaviours to train.

- Practical support: Management need to not only support the principal of training but need to support it practically too. This can be as simple as setting realistic goals for their staff; it is much better give staff small but regular time slots to train one or two individuals than expect or allow them to try to train all of their animals as and when they can.

- Financial support: Financial support can vary from giving a small budget to provide basic equipment such as clickers, through to sending staff on training workshops, employing the services of outside consultants and even creating an animal behaviour/ training department within the zoo. Considering the direct and indirect financial benefits to an institution that trains animals training budgets should never be an afterthought during annual budget meetings.

- Consideration of the trainer-animal relationship: Managers and vets can also support their staff by taking extra care when planning procedures which are likely to have a negative effect on the level of trust that is being built up between trainer and animal. For example if restraint of an animal is required then potentially the trainer (with their consent) can be omitted from the procedure to avoid the animal building up a negative association with the trainer. Moving animals to different enclosures or to different zoos can have an impact on the behaviour of the individual being moved and the animals in the near vicinity. The change in behaviour between animal and keeper can be positive or negative. Most movements are not optional but managers should be aware and support trainers who might experience setbacks with their training during these periods.

## Conclusion

There are many factors that can potentially lead to failure of a training program both at an individual and institutional level. Regular reviews both of the program and of the individuals (trainers and animals) will help highlight some potential pitfalls. Trainers need to take into account their animals' individual needs and mangers need to take into account the individuality of the trainers. A team approach is needed as mutual support is essential to ensure progress is made.

In most cases small changes in how we approach training can make all the difference but in some cases help and advice from specialist trainers is required. We must also learn to have reasonable expectations and not attempt too much. We need to consider approaching the whole program in the same way we approach our training: taking many smaller successful steps leads to a good successful program, attempting the impossible does not.

## References

*ANDERSON US, KELLING AS, PRESSLEY-KEOUGH R, BLOOMSMITH MA, MAPLE TL (2003): Enhancing the zoo visitor's experience by public animal training and oral interpretation. Environ. Behav.* ***35****, 826 - 841.*

*BALL RL, FRAZIER A (2002): Operant conditioning as a tool for improved veterinary care in zoo animals. Adv. Ethol.* ***37****, 22.*

*BLOOMSMITH MA, STONE AM, LAULE GE (1998): Positive reinforcement training to enhance the voluntary movements of group-housed chimpanzees within their enclosures. Zoo Biol.,* ***17****, 333 - 341.*

*BRODBELT D, BREALY J, YOUNG L, WOOD J, PFEIFFER D (2005): Anaesthetic-related mortality risks in small animals in the UK. Association of Veterinary Anaesthetists* ***32****, 1 - 7.*

*BUCHANON-SMITH HM (2003): The benefits of positive reinforcement training and its effects on human non-human animal interactions. Proceedings of the Fifth Annual Symposium on Zoo Research, Marwell Zoological Park, Federation of Zoological Gardens of Great Britain and Ireland: London, UK, 21 - 26.*

*DART C (1999): Advantages and disadvantages of using alpha-2 agonists in veterinary practice. Aust. Vet. J.* ***77****, 720 - 721.*

*DESMOND T, LAULE G (1994): Use of positive reinforcement training in the management of species for reproduction. Zoo Biol.,* ***13****, 471 - 477.*

*DEFRA (2004): Appendix 7 Training of animals. The Secretary of State's Standards of Modern Zoo Practice.*

*DURRANT C, MILLARD S, ZIMMERMAN D, LINDBERG D (2001): Lifetime semen production in a cheetah (Acinonyx jubatus). Zoo Biol.* ***20****, 359 - 366.*

*GOOD S (2000): A survey of operant conditioning in AZA institutions. American Zoo and Aquarium Association Regional Conference Proceedings 2000, 27 - 31.*

*GEURRERO D (1996): Training the big cats: One woman's perspective. http://www.cyberpet.com/cybercat/articles/behaviour/bgcats.htm*

*KEUHN BM (2002): Zoo animal welfare boosted by environmental enrichment, positive reinforcement training. JAVMA - J. Am. Vet. Med. Assoc.* ***221****, 1532.*

*McKINGLEY J, BUCHANON-SMITH M (2003): Improving the animal-human relationship with laboratory-housed common marmosets (Callitrix jacchus): increased interactions and positive reinforcement training. Proceedings of the Fifth Annual Symposium on Zoo Research, UK, 27-35*

*PROBST T, ALFORD V, DANEAULT A, MUIR D, PFLAGING E (2001): The use of operant conditioning for reptiles at Disney's Animal Kingdom. American Zoo and Aquarium Association Conference Proceedings 2001, 71 - 74.*

*SEVENICH, MACPHEE M, MELLEN J (2001): Husbandry Training. Disney's Animal Kingdom ©Theme Park Website.*

*WACK R (2003): Felidae. In: FOWLER ME, MILLER RE (Eds.): Zoo and Wild Animal Medicine. 5th Edition, WB Saunders, St Louis, 491 - 500.*

# MICROBIOLOGICAL FINDINGS IN HARBOUR SEALS (*PHOCA VITULINA*) FROM THE WADDEN SEA

ULRICH SA[1], PRENGER-BERNINGHOFF E[2], RADEMAKER M[1], WEISS R[2], WOHLSEIN P[3], SIEBERT U[1]

[1]University of Veterinary Medicine Hannover, Institute of Terrestrial and Aquatic Wildlife Research (ITAW), Foundation, Werftstaße 6, 25761 Büsum, GERMANY;
Sophia.Arlena.Ulrich@tiho-hannover.de; Ursula.Siebert@tiho-hannover.de

[2]Justus-Liebig-Universität Gießen, Institut für Hygiene und Infektionskrankheiten der Tiere, Frankfurter Str. 85 - 89, 35392 Gießen, GERMANY;
Ellen.Prenger-Berninghoff@vetmed.uni-giessen.de; reinhard.weiss@vetmed.uni-giessen.de

[3]University of Veterinary Medicine Hannover, Dept. of Pathology, Foundation, Bünteweg 17, 30559 HANNOVER; Peter.Wohlsein@tiho-hannover.de

Harbour seals (*Phoca vitulina*) are the most common pinniped species in the Wadden Sea. After the banning of hunting and two devastating mass mortalities due to phocine distemper virus (PDV) the population has reached an estimated size of 38,500 individuals in 2012. In comparison, the population size 1988 counted 4,400 animals and in 2002 20,975. In Germany, harbour seals are protected in national parks of the Wadden Sea, which also have become UNESCO World Heritage in 2009. Pathological investigations on dead or moribund found and euthanised animals revealed that harbour seals were suffering from parasitic and bacterial infections.

Microbiological investigations were performed on tissues from 402 harbour seals of the German North Sea collected between 1996 and 2012. As a screening, a total of 1,479 organ samples from lung, liver, kidney, spleen, intestine, and mesenteric lymph nodes of the animals were investigated. Samples were taken on the freshest animals (State 1-3) and histology was conducted on the majority of the animals. A large variety of bacteria including potentially pathogenic bacteria such as *Brucella* spp., *Clostridium perfringens*, *Escherichia coli*, *Erysipelothrix rhusiopathiae, Klebsiella pneumoniae*, *Vibrio* spp., β-haemolytic streptococci and *Staphylococcus aureus* were isolated. Those bacteria were associated with bronchopneumonia, enteritis, hepatitis, polyarthritis, myositis, myocarditis and nephritis. In the majority of cases septicemia was caused by β-haemolytic streptococci, *E. coli* and *Brucella* spp. *Bordetella bronchiseptica* was only found during the PDV epizootic in 2002 similar to the situation in 1988/89 during the first PDV outbreak. Beside parasites, bacterial infections seem to be a major health problem in young harbour seals, possibly influenced by immunosuppression or increasing infectious pressure due to increasing population size.

# CASE REPORT OF SUCCESSFUL GASTROTOMY AND ENTEROTOMY IN THE WESTERN LONG-BEAKED ECHIDNA (*ZAGLOSSUS BRUIJNI*)

VYSOKIKH A[1], ALSHINETSKI M[1], BEBIKH N[1], KUZNETSOVA M[1], STARUNINA I[2]

[1]Moscow Zoo, 123232 Bolshaya Gruzinskaya 1, Moscow, RUSSIA; vysokikh79@mail.ru
[2]Vetcentr, 127051 Tsvetnoy bulvar 11 bul. 1, Moscow, RUSSIA

## Summary

The western long-beaked echidna (*Zaglossus bruijni*) is one of the four extant echidnas and one of three species of *Zaglossus* that occur in New Guinea. *Zaglossus bruijni* has a unique anatomy, including a pronounced down curved snout, which accounts for two-thirds of the length of its head. Lack of teeth in the species is compensated by rows of spikes/horny teeth-like projections on the lengthy tongue of the animal. This type of oral cavity makes it difficult for clinical examination, tongue protruding, force-feeding an oral medication. It has a monogastric digestive tract (GRIFFITHS, 1989) and the diet of *Zaglossus bruijni* consists almost exclusively of earthworms. The process of eating their prey is particularly fast and it is especially difficult to observe the process. There are no records of echidnas being observed eating non-food items but the attraction to artificial objects as food items can be considered a clinical issue in this species. Laparotomies of the western long-beaked echidna were seldom performed. Most surgeries described are related to skin lesions removal, osteosynthesis, and surgical removal of sparganum larvae (VOGELNEST et al., 2008). This report outlines the presentation, diagnostics and treatment of a case of a foreign body GIT obstruction and its surgical removal in a western long-beaked echidna (*Zaglossus bruijni*).

## Introduction

Moscow zoo keeps a *Zaglossus bruijni* male, named "Small" since 1995 in an indoor enclosure, with a pool, natural ground substrate and a sleeping box (cat litter box). Its basic diet includes sliced raw beef meat complemented with mealworms, earthworms and insects. The major health issues observed in “Small” were abnormal liquid stool when the animal was kept on a meat diet (VOGELNEST et al., 2008) and pododermatitis. In 2011 during a six month period prior to our intervention the keepers reported a difference in the animal´s usual behaviour, the major symptoms being an inconstant appetite and low activity. The animal was manually restrained for clinical observation, blood sampling and X-ray and ultrasound examination after a period of marked weight loss in a month (from 7/2 to 6/6 kg), with diarrhea and dehydration, accompanied by an intense decrease in activity and appetite (refused basic diet, ate just small amount of insects and worms) and abnormal behaviour (torpor and preference for the heater area). The clinical evaluation revealed dehydration, abdominal pain and elevated body temperature (33.5°C). The main findings in imaging examination were GIT stasis, free abdominal fluid, hepatitis and pancreatitis. There were no remarkable changes in haematological and faeces analysis. Treatment was initiated with butilescopolamine bromide 0.05 ml/kg IM (intramuscularly) t.i.d ( Buscopan®, Boehringer Ingelheim GmbH) and ketoprofen 2 mg/kg IM t.i.d (Ketofen® 1 %, Merial). Enrofloxacin 5 mg/kg IM s.i.d. (Baytril® 2.5 %, Bayer) and NaCl 0.9 % - 20 ml/kg SC t.i.d and ademetionine 80 mg (Heptral®, Hospira S.p.A.) was administered and the usual diet was complemented with canned food (RC Recovery®, Royal Canine). The patient promptly responded to therapeutics and two to three hours after administration it became more responsive and active. After five days of therapy the animal started showing signs of pain (unusual body posture: curling back, slow-

ness, touching abdomen with the beak and refused to eat). A polyethylene package was then expelled with the faeces. It was decided to perform an exploratory surgery.

## Material and methods

Anaesthesia protocol included 0.1 mg/kg medetomidine (at the end of anaesthesia medetomidine was not reversed with atipamezole) IM and 2.5 mg/kg ketamine IM (RISSMAN, 2000) and isoflurane 0.5 - 3.0 % via mask as echidnas are particularly difficult to intubate (VOGELNEST et al., 2008). During anaesthesia "Small" showed diving reflex with respiratory rate of one breath per seven minutes in the beginning of anaesthesia and one breath per two minutes after forty three minutes of anaesthesia. This fact was presumably related with the poor body condition of the animal and the fact that echidnas are tolerant to increased $CO^2$ concentrations and respond by increasing tidal volume rather than respiratory rate (RISSMAN, 2000). The surgery procedure revealed a dilated, fully packed stomach and obstructed duodenum. Gastrotomy and enterotomy were performed using standard surgical technique performed in small animal practice and several pieces of polyethylene package, ground and food content were removed. There were no particular difficulties in surgical approach as echidnas GIT anatomy is described in literature (GRIFFITHS, 1989). The abdominal surgery was performed with the patient in dorsal recumbency through a midline incision of adequate length to allow a correct exploration of the abdominal cavity. Adhesions caused by the disease was not found during the procedure and the stomach and intestines were sufficiently mobile to perform the surgery out of the abdomen. Warm saline solution 0.9 % was used to clean abdominal cavity after surgery. For the gastrotomy and the enterotomy a 4-0 monofilament absorbable suture was used (poliglecaprone 25; MONOCRYL, Ethicon) with a simple interrupted (spaces of approx. 2 mm between sutures) two-layer pattern. Regarding the abdominal wall and skin closure a 3-0 monofilament absorbable suture (poliglecaprone 25; MONOCRYL, Ethicon) was used with an interrupted pattern. Post-operative care included a warm recovery room and fasting for three days, during which electrolyte replacement solution PO and SC and water were offered. The post-op medication administered was: ranitidine 5 mg/kg IM t.i.d. (Zantac®, Boehringer Ingelheim) and we continued with enrofloxacin, ketoprofen, and butilescopolamine bromide in the same dosages.

## Results

“Small” had an uneventful recovery becoming progressively more active and interested in the keepers. Despite the good condition of the animal achieved and its normal behaviour and appetite a prolonged skin healing process was observed. There was pronounced lymph drainage from the surgical skin site that started on day five and continued to day seventeen. Cytology did not reveal inflammation.

## Discussion

There is potential risk for echidnas being attracted to artificial objects as food items. Diagnostic tools to discover foreign body include clinical examination, X-ray and ultrasound visualisation. Adequate anaesthesia protocol with combination of injectable and gas anaesthetics and standard surgery technique used in small animal practice can be performed in echidnas.
The surgical recovery was uneventful.

## Acknowledgements

The authors thankfully acknowledge the staff of small mammal department of Moscow Zoo and Anna Chernetsova (DVM, imaging department, Bely Klik).

## Reference

*GRIFFITHS M (1989): Tachyglossidae. In Walton DW, Richardson BJ (Eds). Fauna of Australia, Vol. 1B, ch.15. Csiro Publishing Melbourne.*

*RISSMAN RA (2000): Chemical immobilization of the short-beaked echidna (Tachyglossus aculeatus): comparative physiological effects of seven different anaesthetic agents in echidna (alphaxalone, isoflurane, ketamine, medetomidine, medetomidine-ketamine, tiletamine-zolazepam and xylazine). MVetSci thesis (Wildlife Medicine and Husbandry). University of Sydney, Australia.*

*VOGELNEST L, WOODS R, MIDDLETON D (2008): Medicine of Australian mammals, Csiro Publishing Melbourne, 77 - 101.*

# SEROPREVALENCE OF MORBILLIVIUS IN HARBOUR SEALS: PREDICTIVE VALUE FOR POPULATION SUSCEPTIBILITY?

WEHRMEISTER E[1], HARDER TC[2], BAUMGÄRTNER W[3], HAAS L[4], SIEBERT U[1]

[1]University of Veterinary Medicine Hannover, Institute of Terrestrial and Aquatic Wildlife Research, Foundation, Werftstraße 6, 25761 Büsum, GERMANY;
Eva.Wehrmeister@tiho-hannover.de; Ursula.Siebert@tiho-hannover.de

[2]O.I.E., FAO and National Reference Laboratory for Avian Influenza Institute of Diagnostic Virology, Friedrich-Loeffler-Institute, Südufer 10, 17493 Greifswald-Insel Riems, GERMANY

[3]University of Veterinary Medicine Hannover, Dept. of Pathology, Foundation, Bünteweg 17, 30559 Hannover, GERMANY

[4]University of Veterinary Medicine Hannover, Dept. of Virology, Foundation, Bünteweg 17, 30559 Hannover, GERMANY

During the last 25 years two outbreaks of phocine distemper virus (PDV) infection in the free-ranging population of harbour seals (*Phoca vitulina*) were described killing more than 23,000 and about 30,000 harbour seals during outbreaks in 1988 and 2002, respectively. Clinical signs of PDV comprise fever, coughing, dyspnoea, occulonasal discharge, conjunctivitis, ophthalmia, keratitis, diarrhoea, abortion, increased buoyancy due to emphysema, and, occasionally, nervous signs. The main pathological finding is pneumonia with emphysema and oedema. Aim of this study was to follow by serologic means the fate of PDV in the wildlife population of harbour seals in the German and Danish Sea since 1990. Results obtained from more than 400 serum samples originating from free-ranging harbour seals of different ages are presented. Morbillivirus-specific antibodies were detected in standard neutralisation assays using either the PDV isolate 2558/Han 88 (sera obtained from 1990 to 1993, in 1996, 1997 and from 2002 to 2004) or the closely related canine distemper virus (CDV) strain Onderstepoort (sera obtained from 1996 to 1998, in 2000, 2001 and since 2005). One-third of the harbour seals in this study were seropositive for distemper virus. An undulating course of annual seroprevalence rates was seen with peaks in the post-epidemic years 1990/ 1991 and from 2002 to 2004. Thereafter seroprevalence decreased again. In recent years very few seropositive seals were detected suggesting an increasing susceptibility of the harbour seal population for a new outbreak of PDV. Lack of viral presence in the wildlife population and natural turnover rates of the seal population probably contributed to the near complete fade-out of humoral morbillivirus-specific immunity. As the seal population in the Wadden Sea has grown steadily since 2003 to a maximum of around 38,500 harbour seals since counting programmes have started in 1975 a reintroduction of PDV (from marine sources) or of CDV (from terrestrial sources) could result in an epizootic with high mortality.

# *MARMOTA MARMOTA*: TOXOPLASMOSIS IN WILD AND CAPTIVE EUROPEAN WOODCHUCK

WEINBERGER H[1], RICHTER S[1], BAGÓ Z[1], REVILLA-FERNÁNDEZ S[1], GLAWISCHNIG W[2], SCHMOLL F[1]

[1]Austrian Agency for Health and Food Safety, Inst. for Veterinary Disease Control Mödling, Robert-Koch-Gasse 17, 2380 Mödling, AUSTRIA; susanne.richter@ages.at
[2]AGES, Institute for Veterinary Disease Control Innsbruck, Technikerstr. 70, 6020 Innsbruck, AUSTRIA

*Toxoplasma gondii* is one of the most common zoonotic intracellular coccidian protozoan parasites infecting almost all warm-blooded animals, including birds. The life cycle of *T. gondii* is facultative heteroxenous with felids as definitive hosts being able to excrete sporulated oocysts into the environment. Intermediate hosts are wild and captive ruminants, carnivores, birds, marsupialia and even aquatic mammals. Infections are usually acquired by ingestion of infected meat, contaminated food or water with oocyts from faeces of infected cats or by transplacental transmission.
The occurrence of toxoplasmosis in Sciuromorpha (Genus *Marmota*) was first reported in 2007: a) in a captive European woodchuck (*Marmota marmota*) from the Alpenzoo in Innsbruck (RICHTER et al., 2007), and b) in a captive *Marmota monax* submitted from an American wildlife rescue facility in New York (BANGARI et al., 2007). In 2011 a wild woodchuck from the Austrian Alps was also found infected with toxoplasmosis. Immunohistochemical analysis showed tissue cysts of the parasite in liver and brain; the infection was confirmed by PCR and sequence analysis. Ultrastructure of tissue cysts, respectively the cyst wall structure and bradyzoite organisation resembled that of *T. gondii* described by SPEER et al. (1999) and DUBEY et al. (1998).
*M. marmota,* which inhabits like other hosts (e.g. foxes, roe deer, chamois and ibex) the Austrian, Italian and Swiss alpine regions, may be one of the indicators for pasture contamination with *T. gondii* oocysts in the European alpine region.

## References

*BANGARI DS, MOUSER P, MILLER MA, STEVENSON GW, VEMULAPALLI R, THACKER HL (2007): Toxoplasmosis in a woodchuck (Marmota monax) and two American red squirrels (Tamiasciurus hudsonicus). J. Vet. Diagn. Invest.* ***19****, 705 - 709.*

*DUBEY JP, LINDSAY DS, SPEER CA (1998): Structures of Toxoplasma gondii Tachyzoites, Bradyzoites, and Sporozoites and Biology and Development of Tissue Cysts. Clin. Microbial. Rev.* ***11****, 267 - 299.*

*RICHTER S, WERNSDORF P, GLAWISCHNIG W, BAGÓ Z (2007): The Ultrastructure of Bradyzoites and Tissue Cysts of an apicomplexan parasite found in a woodchuck (Marmota marmota Lin.) – a case study. Microscoc. Microanal.* ***13*** *(Suppl. 3), 236 - 237.*

*SPEER CA, DUBEY JP, MCALLISTER MM, BLIXT JA (1999): Comparative ultrastructure of tachyzoites, bradyzoites and tissue cysts of Neospora caninum and Toxoplasma gondii. Internat. J. Parasitol.* ***29****, 1509 - 1519.*

# WHAT'S NEW, ELEPHANT? - MORPHOLOGICAL PECULIARITIES OF THE EXTERNAL EAR IN AFRICAN ELEPHANTS (*LOXODONTA AFRICANA*)

WEISSENGRUBER GE, FEICHTINGER K, FORSTENPOINTNER G

University of Veterinary Medicine Vienna, Institute of Anatomy, Histology and Embryology, Veterinärplatz 1, 1210 Vienna, AUSTRIA; gerald.weissengruber@vetmeduni.ac.at

Many researchers took a particular interest in the extraordinarily large auricles of African elephants (*Loxodonta africana*). Position and movements of the auricles are possibly involved in social communication and defence against insects. Furthermore, it is very likely that their surface and blood supply play a major role in thermoregulation. Referring to several reports elephants can voluntarily close the second part of the external ear, the external ear canal. Nevertheless, detailed morphological data concerning the external ear and auricular muscles are sparse. We examined the external ear of four juvenile African elephants by means of macroscopic and microscopic anatomical methods. The Eminentia conchae of the auricular cartilage is connected via two rod-like structures to the cartilaginous part of the external ear canal. This part consists of a rolled up layer of cartilage whose edges overlap. In addition to those muscles moving the auricle, African elephants also have muscles, which insert on the Cartilago meatus acustici and the Eminentia conchae. Most probably, some of these muscles are able to vary the lumen size of the cartilaginous part of the external ear canal. The Arteria auricularis caudalis supplies the auricle. Branches of arteries, veins and nerves disperse tree-like over the caudal surface of the Cartilago auriculae.

# DETECTION OF DUCK ADENOVIRUS 1 (EGG DROP SYNDROME VIRUS) IN MALLARDS (*ANAS PLATYRYNCHOS*) BY MOLECULAR METHOD

ZADRAVEC M[1], BALLMANN M[2], ZORMAN ROJS O[1], HARRACH B[2], RAČNIK J[1], MARHOLD C[1], SLAVEC B[1]

[1]Veterinary Faculty of Ljubljana, Institute for Poultry Health, Gerbičeva 60, 1000 Ljubljana, SLOVENIA; marko.zadravec@vf.uni-lj.si

[2]Hungarian Academy of Sciences, Centre for Agricultural Research, Institute for Veterinary Medical Research, Hungária krt. 21., 1143 Budapest, HUNGARY

## Summary

Egg drop syndrome (EDS) is a frequent disease in egg laying hens. Duck adenovirus 1 (DAdV-1), its causative agent was successfully isolated from affected hens, as well as from naturally infected domestic ducks and geese. However, despite high occurrence of antibodies against DAdV-1 in free living waterfowl, the presumed natural reservoir of the virus, there is no data about successful isolation or molecular confirmation of the virus in wild birds.

In order to take an insight in prevalence and shedding of adenoviruses, cloacal swabs from 90 free living mallards (*Anas platyrynchos*) that were shot during the hunting season in 2010 were examined. DNA was extracted and sensitive, concensus nested PCR targeting the most conserved region of the adenovirus DNA polymerase gene was performed. Only one sample (1.1 %) tested positive on DAdV-1 polymerase gene fragment. A 272 bp long sequence that was gained from the sample shared 100 % homology on nucleotide level with DAdV-1. To the best of our knowledge, this is the first molecular report of DAdV-1 outside the intensively reared poultry

## Introduction

Egg drop syndrome (EDS) first emerged in 1973-1974 in flocks of laying hens in The Netherlands (VAN ECK et al., 1976) and was subsequently recognised in many other countries. The causative agent was found to be an adenovirus (strain 127, later EDS-76 virus or EDSV). Soon after onset of this new clinical condition, chicken's sera collected before outbreaks of the disease were retrospectively analysed. Results confirmed that antibodies against EDSV were not present in chickens before the occurrence of disease (MCFERRAN et al., 1977; KALETA et al., 1980; BARTHA et al., 1982).

Since then, many serological studies were performed in search for the original host of the causative agent of EDS. Many domesticated as well as wild birds were tested for antibodies against EDS virus. Antibodies were frequently found in waterfowl and aquatic birds. Most often their presence was confirmed in different wild-living and domestic duck species with antibodies prevalence up to 60 % (ADAIR et al., 1979; SCHLOER, 1980; BARTHA et al., 1982; GULKA et al., 1984). Ducks were determined to be the original host of EDS virus and the virus was classified as duck adenovirus 1 (DAdV-1) in the genus *Atadenovirus* (HARRACH et al., 1997; BENKŐ et al., 2005).

DAdV-1 was successfully isolated from laying hens, as well as from healthy and diseased domestic ducks and geese (BAXENDALE, 1978; GOUGH et al., 1982; IVANICS et al., 2001). However, there is no data about successful isolation or molecular confirmation of the virus from wild living birds. During a large volume screening for novel adenoviruses in wildlife (not published), we happened to detect DAdV-1 in mallards.

## Material and methods

Ninety (90) cloacal swabs of dead mallards (*Anas platyrynchos*) were collected. Mallards were shot during the hunting season in 2010. Before DNA extraction, 2 ml of phosphate buffered saline (PBS) was added to each sample and vortexed vigorously. DNA was purified from 200 µl of the suspension with the QIAamp® DNA Mini kit (Qiagen, Hilden, Germany) according to the manufacturer's recommendation. Obtained DNA was examined by nested PCR with highly degenerated primers targeting the adenoviral DNA polymerase gene, as described by WELLEHAN et al. (2004).

## Results and discussion

One sample (1.1 %) tested positive on DAdV-1 genetic material. After removing the primer sequences, a 272 bp long sequence was gained of the DNA polymerase gene. It had 100 % homology on nucleotide level with DAdV-1.

Unfortunately, further attempts with non-nested PCR using specific pair of primers targeting the variable region of DAdV-1 hexon gene (RAUE and HESS, 1998) were not successful. It is very likely, that quantity of viral DNA was too small in the presumably healthy ducks to be detected by the non-nested DAdV-1 specific primers, but still enough for successful detection by nested PCR. To detect the hexon gene of this mallard originated DAdV-1, we plan to design primers based directly on DAdV-1 sequences. By the study of the variable hexon region (loop1 and loop2) we may be able to see differences compared to the earlier sequenced DAdV-1 strain.

While our original aim was to discover possibly novel duck adenoviruses by the pan-adenovirus PCR, to the best of our knowledge, this is the first molecular report of DAdV-1, the causative agent of egg drop syndrome, outside the intensively reared poultry.

## Acknowledgements

The study was supported by Slovenian Research Agency – Young Research Grant (Grant No.: 1000-07-310106).

## References

*ADAIR BM, MCFERRAN JB, CONNORT TJ, MCNULTY MS, MCKILLOP ER (1979): Biological and physical properties of a virus (strain 127) associated with the egg drop syndrome 1976. Avian Pathol.* ***8****, 249 - 264.*

*BARTHA A, MÉSZÁROS J, TANYI J (1982): Antibodies against EDS-76 avian adenovirus in bird species before 1975. Avian Pathol.* ***11****, 511 - 513.*

*BAXENDALE W (1978): Egg drop syndrome 76. Vet. Rec.* ***102****, 285 - 286.*

*BENKŐ M, HARRACH B, BOTH GW, RUSSEL WC, ADAIR BM, ÁDÁM É, DE JONG JC, HESS M, JOHNSON M, KAJON A, KIDD AH, LEHMKUHL HD, LI Q, MAUTNER V, PRING-AKERBLOM P, WADELL G (2005): Adenoviridae. In: FAUQUET CM, MAYO MA, MANILOFF J, DESSELBERGER U, BALL LA (Eds.): Virus Taxonomy. Eighth Report of the International Committee on the Taxonomy of Viruses. San Diego: Academic Press, 213 - 228.*

*GOUGH RE, COLLINS MS, SPACKMAN D (1982): Isolation of hemagglutinating adenovirus from commercial ducks. Vet. Rec.* ***110****, 275 - 276.*

*GULKA CM, PIELA TH, YATES VJ, BAGSHAW C (1984): Evidence of exposure of waterfowl and other aquatic birds to the hemagglutinating duck adenovirus identical to EDS-76 virus. J. Wildlife Dis.* ***20****, 1 - 5.*

*HARRACH B, MEEHAN BM, BENKŐ M, ADAIR BM, TODD D (1997): Close phylogenetic relationship between egg drop syndrome virus, bovine adenovirus serotype 7, and ovine adenovirus strain 287. Virology* ***229****, 302-306.*

*IVANICS É, PALYA V, GLÁVITS R, DÁN Á, PÁLFI V, RÉVÉSZ T, BENKŐ M (2001): The role of egg drop syndrome virus in acute respiratory disease of goslings. Avian Pathol.* ***3****, 201 - 208.*

*KALETA EF, KHALAF SED, SIEGMANN O, BUSCHE HJ (1980): Nachweis von Antikorpern gegen das Egg-Drop-Syndrom-76-Virus bei domestizierten und nicht domestizierten Vogeln. Prakt. Tierarzt.* ***61****, 948 - 952.*

*MCFERRAN JB, ROWLEY HM, MCNULTY MS, MONTGOMERY LJ (1977): Serological studies on flocks showing depressed egg production. Avian Pathol.* ***6****, 405 - 413.*

*RAUE R, HESS M (1998): Hexon based PCRs combined with restriction enzyme analysis for rapid detection and differentiation of fowl adenoviruses and egg drop syndrome virus. J. Virol. Methods* ***73****, 211 - 217.*

*SCHLOER GM (1980): Frequency of antibody to adenovirus 127 in domestic ducks and wild water-fowl. Avian Dis.* ***24****, 91 - 98.*

*VAN ECK JHH, DAVELAAR FG, VAN DEN HEUVEL-PLESMAN TAM, VAN KOL N, KOUWENHOVEN B, GULDIE FHM (1976): Dropped egg production, soft-shelled and shell-less eggs associated with appearance of precipitins to adenovirus in flocks of laying fowl. Avian Pathol.* ***5****, 261 - 272.*

*WELLEHAN JFX, JOHNSON AJ, HARRACH B, BENKŐ M, PESSIER AP, JOHNSON CM, GARNER MM, CHILDRESS A, JACOBSON ER (2004): Detection and analysis of six lizard adenoviruses by consensus primer PCR provides further evidence of a reptilian origin for the atadenoviruses. J. Virol.* ***78****, 13366 - 13369.*

# OPTIMISATION OF MOLECULAR PROTOCOL FOR *TRICHINELLA* SPP. SPECIES IDENTIFICATION FROM WILDLIFE ANIMALS

ZDANKOVSKA A[1], KOKINA I[1], KIRJUŠINA M[1], DEKSNE G[2], BAKASEJEVS E[1], GAVARĀNE I[1]

[1]Daugavpils University, Institute of Systematic Biology, Vienības str. 13, Daugavpils 5401, LATVIA; zdankovska@inbox.lv
[2]Institute of Food Safety, Animal Health and Environment "BIOR", Lejupes str, 3, Rīga 1073, LATVIA

Nowadays the investigations of trichinellosis are often carried out, because infection by *Trichinella* spp. has been detected in domestic and wild animals of all continents, with the exception of Antarctic. One of the main methods for *Trichinella* spp. identification is by using molecular biology methods. There are developed a lot of different molecular protocols using different chemicals for analyses. The aim of current study was to optimise molecular protocol for *Trichinella* spp. species identification. Totally larvae from four animal species - wild boars, raccoon dogs, foxes, and lynxes were used.
Molecular analyses were carried out on 495 of *Trichinella* spp. individuals for species identification. For DNA isolation the molecular protocol by using membrane spin-column method (QIAamp DNA Mini Kit, Qiagen, Germany) was modified. For specific *Trichinella* spp. is known size (bp) of fragment produced by five primer pairs, and in this case it was possible to identify eight sibling species. PCR products were obtained by using multiplex-PCR, where five primer pairs were used (ESV, ITS1, ITS2 regions of DNA were analysed). For each 30 µl of PCR reaction Taq PCR Master Mix Kit (Qiagen, Germany) was used. It was possible to identify single larvae with one amplification reaction. For species identification PCR amplification products were visualised and analysed by automated QIAxcel electrophoresis instrument (Qiagen, Germany).
The results of our study showed that *Trichinella britovi* species were present in all samples.

## Acknowledgement

This work has been supported by the European Social Fund within the Project "Support for the implementation of doctoral studies at Daugavpils University" Agreement Nr. 2009/0140/1DP/1.1.2.1.2/ 09/IPIA/VIAA/015.

# AUTHOR INDEX

## A



## B



## C

## D



## F



## G

## H



## I



## J



## K

## L



## M



## N



## O



## P

## R



## S

## T



## U



## V



## W



## Z